

## Sclerotherapy of sciatic nerve varices

Alessio Mario Cosacco,<sup>1</sup> Maddalena Bressan,<sup>1</sup> Mirko Tessari<sup>2</sup>

<sup>1</sup>School of Vascular Surgery, University of Ferrara, Ferrara; <sup>2</sup>Vascular Diseases Centre, University of Ferrara, Ferrara, Italy

### Abstract

Sciatic nerve varices (SNV) represent an infrequent presentation of varicose veins. They are usually not recognized and may present only with chronic sciatic pain with few varicosities. On clinical examination, sciatic pain can be reproduced by finger-pressing the superficial varicose veins at their point of connection with the SNV. These varices are then confirmed by duplex ultrasonography. We herein report a case of a 78-years-old woman affected by symptomatic SNV, treated by echo-guided Tessari foam sclerotherapy (EGFSCL) with immediate relief of the sciatic pain. Reflux through the sciatic veins, as the connected superficial varicose veins, disappeared completely and not any complications have emerged. EGFSCL seems to be both safe and effective, so representing a reliable and minimally invasive treatment for this disorder.

### Case Report

A 78-years-old Italian Caucasian woman presented to our Vascular Disease Clinic concerned with a chronic history of sciatic pain located at the posterolateral aspect of the left leg. The patient referred that she used to treat this pain with piroxicam 20mg and tiocolchicoside 4mg/2mL for one week, followed by continuous recurrences within a few months. Previous medical history included post-partum deep vein thrombosis, breast carcinoma treated with radical mastectomy, Raynaud phenomenon, Dupuytren disease of the left hand surgically treated, chronic gastritis, previous stripping of both great saphenous veins (GSV), diffuse arthrosis. The patient was generally physically well, not overweight, and did not smoke. On clinical examination, the sciatic pain corresponded to the posterolateral aspect of the leg with visible superficial varicose veins in that area. Noteworthy the deep palpation of them was hurtful. High-resolution ultrasonography examination showed a popliteal reflux in recanal-

ized post-thrombotic vein. Moreover, the popliteal vein was in anatomical relationship with the sciatic nerve. Interestingly the sciatic nerve was encircled by a venous plexus, fed by the popliteal reflux. Finally, the plexus was connected via a perforator of the popliteal fossa with the painful varices of the postero-lateral aspect of the leg (Figure 1). We diagnosed the presence of sciatic nerve varices (SNV), which in the present case represents a collateral circle developed in consequence of the previous popliteal deep vein thrombosis (DVT). Along time the plexus enlarged because of the reflux occurred following popliteal vein recanalization. Actually, it appears as congested veins compressing the sciatic nerve. We supposed that the treatment of SNV could decrease the compression. For such a reason we performed an echo-guided foam sclerotherapy (EGFSCL) by the injection of 1mL of polidocanol 1%, mixed with air in a 1:4 ratio, according to Tessari method. We injected the postero-lateral varicose veins connected with the perineural venous plexus through a perforator of the popliteal fossa. At duplex ultrasound we verified that the foam properly filled the perineural venous plexus determining a vasospasm with immediate relief of the referred sciatic pain. The two-months follow-up duplex ultrasound examination showed that the effective treatment of both venous plexus and perforator reflux corresponded to a complete resolution of symptom. The patient was then required to wear a second-class elastic stocking with RAL pressure and AG segment, during cooler seasons. We can confirm both safety and effectiveness of echo-guided foam sclerotherapy in treating this disorder.

### Discussion

The first anatomic description of sciatic nerve varicosities was published in 1890 by Verneuil.<sup>1</sup> Almost a century later, Thiery described the association of varicosities along the nerve with sciatic pain arising in the popliteal area and extending along the course of the nerve in the posterior thigh.<sup>2</sup>

Varicose veins along lower limbs may also present as sciatic nerve varices. Even if the saphenous veins and their tributaries are involved in most of the cases of veins' reflux in cardiovascular disease (CVD), only in less than 10% of patients this reflux is found in non-saphenous veins.<sup>3,4</sup> There are few small reports on refluxing veins associated with nerves of lower limb, where the most frequent location is in the distribution of the sciatic nerve and its branches. De Pinãl *et al.* identified four patterns of extra-

Correspondence: Maddalena Bressan, Vascular Diseases Centre, University of Ferrara, via Aldo Moro 8, 44121 Cona (Ferrara), Italy.  
E-mail: maddalena.bressan@edu.unife.it.

Key words: Sciatic nerve; non-saphenous varicose veins; echo-guided foam sclerotherapy; sciatic pain; reflux; CVD.

Contributions: All the authors made a substantive intellectual contribution. All the authors have read and approved the final version of the manuscript and agreed to be accountable for all aspects of the work.

Conflict of interest: The authors declare no potential conflict of interest.

Funding: None.

Availability of data and materials: All data generated or analyzed during this study are included in this published article.

Informed consent: Written informed consent was obtained by the patient.

Received for publication: 3 October 2021.

Accepted for publication: 21 October 2021.

This work is licensed under a Creative Commons Attribution 4.0 License (by-nc 4.0).

©Copyright: the Author(s), 2021

Licensee PAGEPress, Italy

*Veins and Lymphatics* 2021; 10:10166

doi:10.4081/vl.2021.10166

neural drainage (Figure 2): the direct *venae nervora*, which is the least common type, draining directly from the nerve to the accompanying *vena commitans* and representing the main venous drainage of the nerves in that region (a); the indirect *venae nervora*, that leave the nerve and connect with other larger veins, which usually come off neighboring muscles and subsequently drain to the *vena commitans* (b); the periarterial venous plexus (c), where the nerve veins connect to before the plexus drains into the *venae commitans* of the artery. This is a common pattern of drainage and of clinical significance since the fine branches of the plexus have no valves; the perivenous venous plexus, where the nerve veins directly drain to a network of valveless small veins surrounding and connecting to larger cutaneous veins (d).<sup>5</sup>

The incompetent sciatic veins, with development of reflux, usually produce significant symptoms along the distribution of the nerves, with symptoms of local irritation, where the most common among these is pain along the sciatic distribution, that

deteriorated with sitting and improved with walking and standing. These persistent symptoms are most commonly present in the posterior thigh.<sup>4</sup> On clinical examination, to confirm the presence of SNV, sciatic pain can be reproduced by finger-pressing

the varicose veins at their point of descent under the underlying fascia and lateral to the popliteal skin fold.<sup>3</sup> Routine diagnosis of SNV does not require spiral computed tomography (CT) imaging, instead it may be achieved more reliably using duplex

ultrasonography which, together with the clinical symptoms, enables to determine the treatment of SNV when a reflux coming from an incompetent perforating vein is documented.<sup>6</sup>

From a therapeutic point of view, the superficial varices may be avulsed by phlebectomy with risk of damage to sensory nerve fibers close to the SNV. In fact, a more extensive surgical approach should be avoided because of the great risk of damaging the nerve structures. The subfascial and intramuscular SNV may be treated easily by sclerotherapy, using low concentrations of sclerosant to avoid inflammatory reaction affecting the nerve.<sup>3</sup> This therapy has already been described as effective and safe in treating SNV, but for some authors there would be dimensional and anatomical limitations with this treatment.<sup>4</sup> Despite this, sclerotherapy has few related complications and is easily repeatable when the symptoms for recurrent varices reappear.

## Conclusions

We herein describe a case of SNV successfully treated by Tessari foam sclerotherapy. We can affirm that SNV are less rare than usually thought. Currently, a totally safe and reliable treatment of this disorder is missing. Indeed, EGFSCS in treating SNV seems to be safe and effective in a mid-term evaluation, becoming a reliable treatment tool in a field in which surgical complication and nerve injuries have been frequently described.

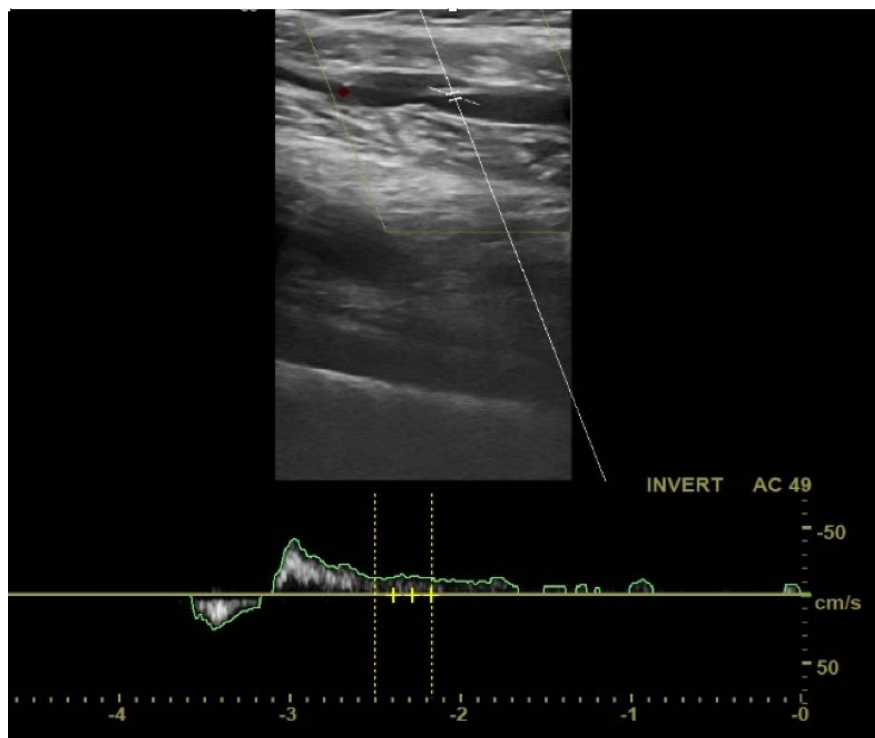


Figure 1. Longitudinal aspect of the post-thrombotic left popliteal vein with reflux.

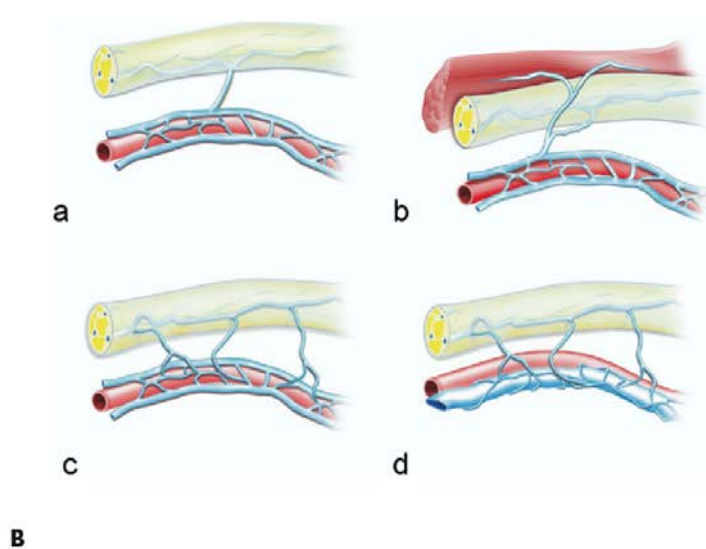
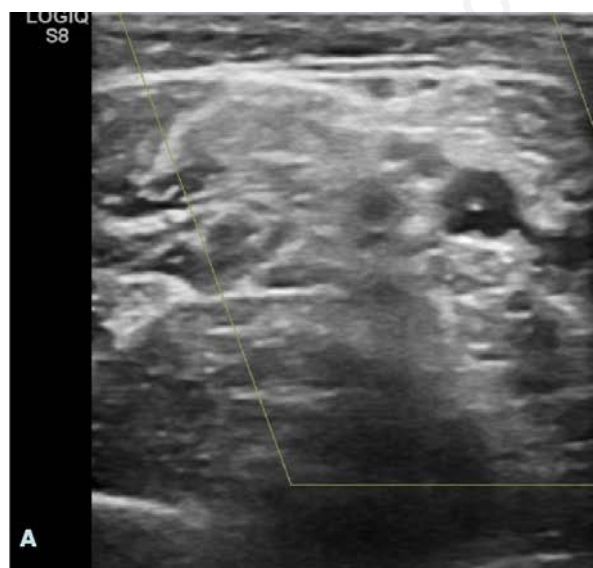


Figure 2. A) Transversal aspect showing the sciatic nerve compressed by a congested venous plexus (white ellipsis) fed by the popliteal reflux. The post-thrombotic destroyed valve appears as a hyperechogenic spot in the lumen of the popliteal vein (red arrow). B) Patterns of extraneural drainage from sciatic nerve veins. (modified from Del Piñal F. *et al.*<sup>5</sup>)

---

## References

1. Verneuil A. [In: 'Traité de chirurgie' de Duplay et Reclus, Paris, Tome II 221; 1890.] [Article in French.] Cited by J. Vander Stricht.
2. Thiery L. [La veine du nerf sciatique impact clinique et thérapeutique.] [Article in French]. Phlebologie 1988;41:687-9.
3. Ricci S., Georgiev M., Jawien A., Zamboni P. Sciatic nerve varices. Eur J Vasc Endovasc Surg. 2005;29:83-7.
4. Ricci S. Ultrasound observation of the sciatic nerve and its branches at the popliteal fossa: always visible, never seen. Eur J Vasc Endovasc Surg. 2005;30:659-63.
5. Del Pinà F, Taylor GI. The venous drainage of nerves; anatomical study, and clinical implications. Br J Plast Surg 1990;43:511-20.
6. Giancesini S., Menegatti E., Tacconi G., et al. Echo-guided foam sclerotherapy treatment of venous malformation involving the sciatic nerve. Phlebology 2009;24:46-47.

Non-commercial use only