

## Ulcerated hemosiderinic dyschromia and iron deposits within lower limbs treated with a topical application of biological chelator

Eugenio Brizzio,<sup>1</sup> Marcelo Castro,<sup>2</sup> Marina Narbaitz,<sup>3</sup> Natalia Borda,<sup>2</sup> Claudio Carbia,<sup>2</sup> Laura Correa,<sup>4</sup> Roberto Mengarelli,<sup>5</sup> Amalia Merelli,<sup>2</sup> Valeria Brizzio,<sup>2</sup> Maria Sosa,<sup>6</sup> Biagio Biancardi,<sup>7</sup> Alberto Lazarowski<sup>2</sup>

<sup>1</sup>International Group of Compression and Argentina Medical Association, Buenos Aires, Argentina; <sup>2</sup>Department of Clinical Biochemistry, Institute of Pathophysiology and Clinical Biochemistry, School of Pharmacy and Biochemistry, University of Buenos Aires, Argentina; <sup>3</sup>Pathology Department - Hematology - National Academy of Medicine, Buenos Aires, Argentina; <sup>4</sup>Favaloro's Foundation, Buenos Aires, Argentina; <sup>5</sup>Pontifical Catholic University of Argentina, Buenos Aires, Argentina; <sup>6</sup>Italian Hospital of Buenos Aires, Argentina; <sup>7</sup>Faculty of Pharmacy, University of Naples, Italy

### Abstract

The ulcerative haemosiderinic dyschromia of chronic venous insufficiency is difficult to heal and presents a high accumulation of iron. Lactoferrin, a potent natural iron chelator, could help to scar this ulcerative haemosiderinic dyschromia. The objective of this study was to determine whether the topical application of a liposomal gel with Lactoferrin favors scarring/degradation of the brown colored spot typical of ulcerative haemosiderinic dyschromia. Nine patients with severe chronic venous insufficiency and ulcerative haemosiderinic dyschromia (CEAP-C6), with a natural evolution of over 12 months, were included in the study. Hemochromatosis gene mutations were investigated. The levels of serum ferritin, transferrin saturation and blood cell counts were analyzed. The presence of hemosiderin was investigated through per ulcerous and ulcer fundus biopsies carried out at baseline and 30 days after treatment with Lactoferrin. The severity of the injuries (CEAP classification) was evaluated at the beginning of and throughout the whole 3-month treatment period. No patient had received compression treatment during the

three months previous to this therapy. Significant improvement in these injuries, with a reduction in the dimensions of the brown spot (9 of 9) at Day 90, and complete scarring with a closure time ranging from 15 to 180 days (7 of 9) were observed. The use of topical lactoferrin is a non-invasive therapeutic tool that favors clearance of hemosiderinic dyschromia and scarring of the ulcer. The success of this study was not influenced either by the hemochromatosis genetics or the iron metabolism profile observed.

### Introduction

Chronic venous insufficiency (CVI) is one of the most significant health problems in developed countries. Though the pathogenesis of skin changes and venous ulcers is not completely understood, they occur as a late consequence of chronic ambulatory venous hypertension, caused by outflow obstruction and reflux due to superficial or deep venous valve incompetence. Ethological theories including fibrin cuffs or leukocyte entrapment by chronic inflammation have been suggested.<sup>1</sup>

Haemosiderinic dyschromia (HD) of CVI is a pathological entity that features a brown colored spot resulting from the deposit of free iron within leg tissues. Iron is a highly irritative element capable of stimulating free-radical release and of causing leg ulcers, thus producing an ulcerated hemosiderinic dyschromia (UHD). Since it has been recognized as a grade IV cause of skin dyschromia according to CEAP classification, and taking into account that these effects can be self-produced or generated by stimulation of melanin, there is an increasing interest in the role of iron tissue deposits caused by chronic venous disorders. According to this, a brown discoloration of the skin near the injury can be considered to be a typical sign of venous disease. It occurs when blood cells leak out of blood vessels. The hemoglobin from red blood cells is broken down into hemosiderin that is then permanently stored within the tissues. This can take place after a significant injury in the leg and is often worsened by an underlying venous problem.<sup>2,3</sup>

Since extravasated blood cells with hemoglobin are phagocytosed by tissue macrophages called siderophages, the accumulation of hemosiderin within the injury area is a characteristic feature of the disease, resulting in the brownish color of the skin.<sup>2</sup> Furthermore, urinary hemosiderin could be a biological marker for the clinical follow up of chronic venous insufficiency with haemosiderinic dyschromia.<sup>4</sup>

Nearly 25% of absorbed iron is normally eliminated from the body by exfoliation of epi-

Correspondence: Eugenio Brizzio and Alberto Lazarowski, San Martín 965, 1st floor (Zip code 1004) Buenos Aires, Argentina.  
Tel. +54.11.4311.5559.  
E-mail: eugeniobrizzio@ciudad.com.ar; ebrizzio@fibertel.com.ar; eugeniobrizzio@gmail.com; alazarowski@gmail.com

**Key words:** ulcerated haemosiderinic dyschromia, liposomal Lactoferrin, scarring, hemosiderin-ferritin.

**Acknowledgments:** the authors would like to thank P. Girimonte for her assistance with the statistical analysis of the results. We also wish to thank the patients who made this study possible. Conference presentation: part of the present study has been presented at the following congresses: i) XX Argentine Congress of Hematology, October 18-22, 2011, Mar Del Plata, Argentina (submitted to the Poster Section); ii) III World Symposium of advances in Phlebology and Lymphology, November 10-12, 2011, Buenos Aires, Argentina (awarded); iii) Latin American Congress of Angiology and Vascular Surgery, November 24<sup>th</sup>, 2011, Cartagena, Colombia.

Received for publication: 26 July 2012.  
Revision received: 19 September 2012.  
Accepted for publication: 26 September 2012.

This work is licensed under a Creative Commons Attribution 3.0 License (by-nc 3.0).

©Copyright E. Brizzio et al., 2012  
Licensee PAGEPress, Italy  
Veins and Lymphatics 2012; 1:e6  
doi:10.4081/vl.2012.e6

dermal cells;<sup>5</sup> therefore, iron accumulation in the skin should be secondary to any mechanism that may increase iron deposits before carrying out this exfoliation. Iron is thought to be a co-factor or mediator of skin toxicity in a variety of pathological situations, including sunburn,<sup>6</sup> porphyria cutanea tarda,<sup>7</sup> inflammation,<sup>8</sup> and skin cancer,<sup>9</sup> as well as in hereditary hemochromatosis (HH).<sup>10</sup> It is important to distinguish HD in CVI from hereditary HH because individual differences could be genetically determined by genes related to HH (*H63D*, *S65C* and *C282Y*).<sup>11</sup>

Lactoferrin (LFR) is a glycoprotein belonging to the family of transferrins, capable of binding to iron. Both human and bovine LFR show a wide antimicrobial spectrum, against positive and negative Gram bacterias, and certain viruses and fungi.<sup>12</sup> The studies on LFR have focused on its ability to chelate iron in cases of hemosiderinic iron accumulation (ecchymosis, post sclerotherapy, CVI).<sup>12</sup> The results of recent studies indicate that it is a powerful regulator of dermal fibroblasts, and that it promotes cutaneous wound healing.<sup>13,14</sup>

however, this has been poorly researched.

There is currently no efficient treatment for HD and associated ulcer in patients with CVI. In a recent systematic survey and meta-analysis, eight randomized clinical trials were identified comparing treatment with stockings and bandages. Five studies revealed an advantage in the use of stockings over bandages, while three other assays showed no difference.<sup>15</sup>

Our aim was to study the effect of liposomated bovine Lactoferrin, locally applied on the surface of UHD, in 9 patients with long-lasting evolution of refractory CVI, selected from our previous study,<sup>16</sup> and to evaluate its potential relation to the iron metabolism profile and mutations of HH genes.<sup>17</sup>

## Study design

This was a prospective controlled pilot study performed on 9 selected patients with severe and persistent UHD of CVI, carried out according to the inclusion and exclusion criteria described below.

All patients gave their signed individual consent to treatment with topical application of liposomated LFR and to undergo biopsy of two lesions. There were three evaluation time points: at 30, 90 and 180 days. The therapeutic protocol was presented for review by the independent court of ethics on March 5<sup>th</sup> 2010 and was accepted on April 23<sup>th</sup> 2010; the protocol was approved in accordance with the principles of the Declaration of Helsinki.

The study used a database consistent with the results obtained during a 6-month follow-up period of 9 patients with recalcitrant venous ulcers. Only one of them presented bilateral ulcers with similar severity of lesions in both legs. This was a pilot study and the data collected should be considered in this light.

The main parameters controlled before and after treatment were: i) stratification of CVI (Ecodoppler), and leg goniometry and edema; ii) severity of ulcerous injuries (color, ulcer areas, rate of scarring time); iii) pain and quality of life; iv) hemosiderin staining in biopsies and blood iron metabolism parameters; v) hematologic profiles; vi) iron profiles; vii) the presence of HH mutations as potential predictive parameters of evolution.

## Inclusion criteria

The main inclusion criteria were: i) patients over 18 years old; ii) unilateral or bilateral ulcers at the anteromedial part of the calf, of proved venous origin, confirmed by Ecodoppler ultrasound; iii) surface larger than 3 cm<sup>2</sup> and smaller than 25 cm<sup>2</sup>; iv) presence of associated periulcerative haemosiderinic dyschromia; v) pre-existing ulcer with at least two months of evolution; vi) patients accepting to undergo treatment according to protocol; vii) each patient received a written report and signed their consent.

## Exclusion criteria

The main inclusion criteria were: i) presence of occlusive arterial pathology with a more than 0.8 arm/ankle index; ii) known allergies; iii) pregnancy; iv) life expectancy less than 12 months; v) severe diseases co-existing simultaneously with venous pathologies, *e.g.* cardiac or mental disorders, renal or hepatic insufficiencies, tumors, etc.; vi) symptomatic peripheral neuropathy, *e.g.* diabetic neuropathy; vii) patients with motor disabilities; viii) diabetes; ix) severe joint disease of the ulcerated leg, besides the ankle stiffness caused by venous ulceration.

## Materials and Methods

### Patients

Nine patients were selected (3 males, 6 females); average age 63 years. A total of 10 ulcerated legs were studied (unilateral ulcers, n=8; bilateral ulcers, n=2).

### Ecodoppler

A SonoScape® colour Ecodoppler S6 (SonoScape Co. Ltd., Shenzhen, China) was used to confirm the venous vascular etiology of the ulcer and the stratification of patients according to the type of reflux observed. Only one baseline control was performed at the moment of admission. Stratification of patients was carried out according to the type of reflux observed, such as superficial, perforating, deep, or their combined forms as superficial + perforating, perforating + deep, superficial + perforating + deep.

### Lesion evaluation

Time from the onset of the CVI, the evolution of the hemosiderinic dyschromia, and the ulcer development were all recorded.

Since skin pigmentation as a brown discoloration near the lesion is a typical feature of

HD in case of venous ulcers, a visual scale of brown color was used to follow up treatment. Baseline and weekly controls were carried out. We used an analogical visual arbitrary numbered scale of brown (Figure 1) that allowed us to build a follow-up chart and to identify any improvement in HD.

Wound size is a basic parameter used to evaluate the success of treatment. The planimetric Visitrak® Smith and Nephew device (Smith and Nephew, Hull, UK) was used.

Volume was obtained through perimeters measured at 4 segments of the leg: 12 cm from hallux extremity, and 10, 20 and 30 cm from the floor (Figure 2A and B).<sup>18-19</sup>

Goniometry was measured using the model described by Cleusa Belczak (Figure 3).<sup>20</sup>

Pain was measured at baseline and after four weeks of treatment using the arbitrary numerical Likert scale from 1 to 5, where 1 indicates the lowest intensity of pain and 5 the highest one.<sup>21</sup> The quality of life questionnaire in chronic lower limb venous insufficiency (CIVIQ) was evaluated as previously described.<sup>22</sup>

Venous blood samples for determining hematimetric parameters as well as molecular studies were drawn in 2 separate collection tubes containing potassium ethylene diamine tetraacetic acid (K<sub>3</sub>-EDTA), while those for determining biochemical parameters were drawn in tubes with serum separators. Serum was freshly separated from venous blood samples by centrifugation at 1800 g for 10 min at room temperature. All fractioned serum samples and those for molecular studies were stored frozen at -20°C for three months before assaying. Hematimetric parameters were evaluated on fresh samples immediately after blood sample collection; full blood cell counts were studied by SYSMEX XT-1800 (Roche, Penzberg, Germany). Serum iron (SFe, µg/dL), total iron-binding capacity (TIBC, µg/dL), transferrin saturation (sat-Trf %) and serum ferritin (SF, ng/mL) were assayed using a Cobas 6000 autoanalyzer system (Roche).



Figure 1. Arbitrary identification of color scale used.

## HFE genotyping

Samples: five drops of 25  $\mu$ L of anticoagulated blood with  $K_3$ -EDTA were collected on Whatman filter paper no. 1 (5 $\times$ 5 cm) and stored at room temperature in a paper envelope

DNA extraction: DNA was extracted by the modified Boom method.<sup>23</sup> Two drops of dried blood from filter paper of each sample were cut with a scalpel and placed on 4.5 mL of lysis buffer. After 4 h of gentle shaking, the paper was carefully discarded and the DNA was extracted in the supernatant as previously described.<sup>23</sup> DNA extracts were stored at -20°C.

Amplification and detection: the polymerase chain reaction (PCR) mixture was prepared in separate tubes for the study of mutations in exons 4 and 2, respectively, at a final volume of 50  $\mu$ L and a final concentration of 1X Taq Buffer, 0.2 mM dNTP, 2.5 mM MgCl<sub>2</sub>, 0.5 U of Taq polymerase (Invitrogen Corp., Carlsbad, CA, USA) and 0.2  $\mu$ M of each primers (Invitrogen). We used 5  $\mu$ L of DNA extract per sample. The sequences of the primers used were:

### i) exon 4 (*Cys282Tyr* mutation)

Forward: 5'TGGCAAGGGTAAACAGATCC

Reverse 5'CTCAGGCACCTCTCAACC (390 bp);

### ii) exon 2 (mutations *His63Asp* and *Ser65Cys*)

Forward: 5'ACATGGTTAAGGCCTGTTGC

Reverse 5'GCCACATCTGGCTTGAAATT (208 bp).

For both constructions of primers, amplification conditions were 35 cycles with an annealing temperature of 63°C. Then 15  $\mu$ L of PCR products were digested with 2 U of Rsa I for codon 282, Bcl I for codon 63 and Hinf I for codon 65 (New England Biolabs, Ipswich, MA, USA) overnight, according to the manufacturer's instructions. The digestion products were run on 3% agarose gel (Invitrogen) for 2 h at 120 Volts, with ethidium bromide for viewing under UV light. This allowed us to distinguish wild-type (WT), heterozygous (HT) and homozygous (HO) genotypes for each mutation with the following cutting patterns:<sup>24,25</sup>

- Rsa I (*Cys282Tyr*): WT 250 pb/140 pb, HO 250 pb/111 pb/29 pb, HT 250 pb/140 pb/111 pb/29 pb;

- Bcl I (*His63Asp*): WT 138 pb/70 Pb, HO 208 pb, HT 208 pb/138 pb/70 pb;
- Hinf I (*Ser65Cys*): WT 147 pb/60 Pb, HO 207 pb, HT 207 pb/147 pb/60 pb.

Biopsy handling: all patients were treated with subcutaneous local administration of 1% sterile xilocaine. After 10 min, an approximately 12 mm long and 3 mm wide rectangle of tissue was excised to include the surrounding intact skin, the ulcer edge, and the ulcer base. In order to compare changes on both anatomic and hemosiderin staining patterns, biopsies were taken at two different contiguous sites for initial and end-point samples, respectively.<sup>26</sup>

Biopsy histochemistry: each biopsy was immediately divided lengthways. One half was fixed in cold 4% paraformaldehyde in phosphate buffered saline and the other was snap-frozen in optimal cutting temperature over liquid nitrogen for immunocytochemistry. After 24 h, fixed tissues were embedded in paraffin wax and sectioned at 4  $\mu$ . Hematoxylin & Eosin and Perls' Prussian blue methods were used to stain alternate sections.<sup>27</sup>

Operational protocol: the product, a gel containing bovine LFR liposomated to 3%, placed on a 15 $\times$ 20 cm sterile paraffin dressing (tulle gras) made of open weave gauze, with 0.5% chlorhexidine acetate, an antiseptic with a broad spectrum (Bactigras® plaque, Smith and Nephew), was locally applied every day for four weeks (first end point).

It was applied twice a week during the second and third months using an additional compression by means of a multilayer bandage from the very first day, assembled with 3 short 8 cm and 10 cm elastic bandages (Fisiodur®, Zuccari srl, Trento, Italy). The multilayer bandage was applied in a figure-of-eight with turns that regularly crossed one another, with a resting pressure of 40 mmHg and 5-7 mmHg of static stiffness, as previously described.<sup>28</sup> At each medication session, the ulcer was cleaned using gauzes impregnated with Prontosan® solution (B. Braun Medical Inc., Bethlehem PA, USA) followed by administration of simple occlusive medication.

## Results

### Patients

Nine patients were selected from a cohort of 55 patients who had previously completed the aforementioned comparative study of low-strength medical compression stockings with bandages for treating recalcitrant venous ulcers,<sup>16</sup> after a long period without showing any improvement in the ulcers' features (*e.g.* dimensions, color intensity of dyschromia), as well as pain and CIVIQ. Of the 9 independent cases analyzed, 5 corresponded to primary (P) ulcers and the remaining 4 to recidivating (R) ulcers. Ninety percent of the patients included in this study presented dynamic static alterations of plantar support, 4 patients with *pes cavus* (grades II and III), another 4 with flat feet (grades II and III), and the remaining patient without any foot disorder. There was equal distribution of lower limb ulcers between both legs (right n=5, left n=5), taking into account that one patient had bilateral ulcers that both presented the same degree of severity (Table 1).

### Stratification of refluxes through ecodoppler

Ecodoppler confirmed the venous vascular etiology of the ulcer (Figure 4).

No patients presented purely deep reflux. One case exhibited an altered reflux due to the combination of the three systems associated with a severe hemodynamic condition (Table 2).

### Lesion evaluation

Range of duration of CVIs was 48-560 months, of hemosiderinic dyschromia 15-240 months, and of ulcers 2-54 months (Table 1).

In order to perform an evolutive control of the hemosiderinic dyschromia, we used an analogical and arbitrary visual numbered scale of the color brown, and built a chart of color evolution. Therefore, the real color intensity of the skin was compared to the intensities of the aforementioned color scale (Table 3). This scale

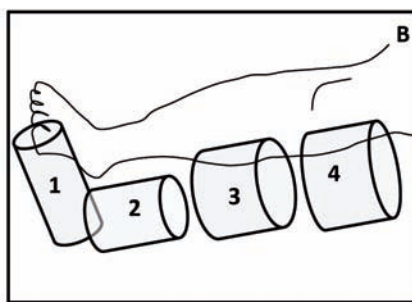
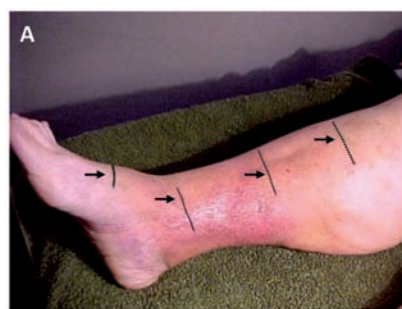

Figure 2. (A) Patient's leg with (B) schematic representation of cylindrical volume of each area (1-4). Modified from Rossi *et al.*<sup>29</sup>

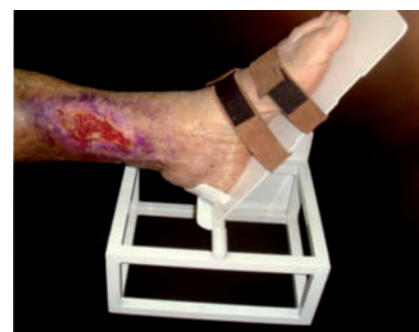

Figure 3. Belczak's model of goniometry.



showed a starting point with an average intensity of 18.7 and decreased to an average intensity of 7.2 at week 12 ( $P < 0.001$ ) (Figure 5). An approximately 50% decrease in color intensity was observed at Week 4.

### Measurement of the area of the ulcer

The area of the ulcer and the scarring rate were checked at study start and at weekly intervals, and observations were recorded. During the initial control, dimensions of ulcers ranged from 3.3 to 23.6 cm. In 8 of 9 patients (9 of 10 ulcers), the area involved decreased significantly ( $P < 0.001$ ) (Table 4 and Figure 6), and in 7 patients, the healing rate reached 80% of the ulcers at the 6-month follow up (Table 5).

Only one patient, who had abandoned the trial, showed a transient increase in the size of the surface of the ulcer, which returned to baseline at Month 6.

### Volumetric perimeter: control of edema

Perimetral control of foot and leg was transformed to volume in  $\text{cm}^3$  as previously described.<sup>18-20</sup> With the exception of case no. 3437 (corresponding to the patient with bilateral ulcers) whose values were approximately 9500  $\text{cm}^3$ , the remaining cases presented values ranging from 3000  $\text{cm}^3$  to 5000  $\text{cm}^3$  and a mild decrease in the edema volume was observed (Table 6).

Goniometry was measured at baseline and after 30 days to check flexion (flx) and extension (ext) movements. A favorable evolution of the tibioastragaline joint could be observed at the expense of an increase in flexor and extensor excursions without any additional treatment (Table 7).

### Pain and chronic lower limb venous insufficiency controls

We used the numerical Likert scale, most commonly seen as a 5 point scale (0=no pain,

5=worst possible pain). In 5 patients, the maximum level of pain (grade 5) was observed at the initial control; this was later reduced to grade 1 after four weeks of treatment. As far as the remaining patients are concerned, the level of the Likert scale diminished 1 point during the same period (Table 8). The survey of quality of life (CIVIQ), the baseline control and the tests performed during Weeks 4, 8 and 12 showed an improvement at all levels. It could be observed that, at all times, the average scoring of the CIVIQ scale (total score) in patients with ulcers closed at Week 12 was lower than the average scoring in patients with unclosed ulcers ( $P < 0.05$ ) (Table 9).

### Blood tests: hematimetric and iron metabolism profiles

Normal results of basal control (1<sup>st</sup>) and after four weeks (2<sup>nd</sup>) of treatment on hematimetric parameters and platelet counts were observed in all cases (data not shown), and iron metabolism profile (Table 10). Interestingly, while transferrin sat (%) decreased in 7 of 9 cases, ferritin increased in 6 of 9.

### HFE genotyping

Only one of the 9 patients (case no. 3334) was heterozygous for the mutant *H63D gene* (Table 10). Coincidentally, the patient presented a high level of ferritin (222 and 244  $\mu\text{g/mL}$ ).

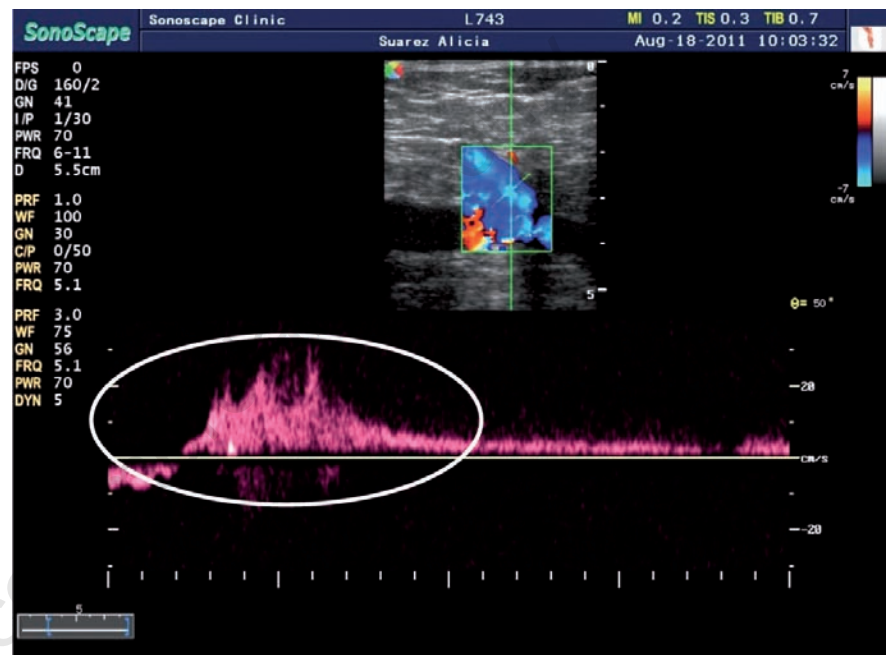


Figure 4. Color ecodoppler: reflux in great saphenous vein.

Table 1. Main features of patients' lesions. No patients were previously treated by surgical or sclerotherapy procedures.

Case no.	Laterality	Duration CVI (months)	Duration dyschromia (months)	Interval (months)	Duration ulcer age (months)	Primary or recurrent	Cavus and/flat feet	BMI
3446	R	180	22	20	2	P	FC	Normal
3437 <sub>R</sub>	R	180	60	24	36	R	FC	OB.3
3437 <sub>L</sub>	L	180	60	30	30	R	FC	OB.3
3283	L	336	36	34	2	R	FC	OB.1
3334	R	276	48	46	2	R	FC	Over weight
3161	L	192	84	36	48	R	Normal	Normal
3441	L	60	54	---	54	P	FF	Normal
3451	R	48	15	2	13	P	FF	OB.2
3274	L	560	60	57	3	P	FF	OB.2
3449	R	360	240	236	4	R	FC	Normal

R, right; L, left; CVI, chronic venous insufficiency; P, primary; R, recurrent; BMI, body mass index; OB, obesity.

Ecodoppler for this patient evidenced reflux on the 3 systems, superficial, perforating and deep reflux mentioned above.

### Biopsy histochemistry

Biopsy features of borders and ulcer bed: samples of two control biopsies (initial and after 4 weeks of treatment) were obtained from the periulcerous area in 10 ulcers, and additional samples from the ulcer bed were obtained in another 2. Histological features (Figure 7) and hemosiderin staining (Figure 8) were evaluated before and after treatment. Before treatment, the histological analysis showed the presence of fibrin cuffs, small vessels, and extravasation of red blood cells, fibrosis and a chronic inflammatory pattern (Figure 7A). Perls' Prussian blue staining showed superficial and deep high cumuli of hemosiderin in the border and fundus of the ulcer (Figure 8A). After four weeks of treatment, extravasated red blood cells and fibrosis were still present; however, certain neovascular structures as well as a repairing inflammatory pattern were observed (Figure 7B). In some cases, Perls' Prussian blue staining seemed to have decreased (Figure 8B).

## Discussion

Ochre dermatitis is a secondary pigmentary disorder of venous stasis in which the increase in intravascular pressure and endothelial alterations cause extravasations of erythrocytes, hemosiderin-laden macrophages, and melanin deposits. It is associated with long-term and high care costs, with an equally high incidence of recurrence, and a significant proportion of negative patient outcomes.<sup>29</sup> In our study, all 9 patients were selected from a previous study because they had ulcers and hemosiderinic dyschromia, both associated to refractory ulcer.

Wound repair depends on neoangiogenesis and activation of a local immune response, as well as on the presence of growth factors, including epidermal growth factor, transforming growth factor  $\beta$ , and basic fibroblast growth factor.<sup>30,31</sup> It has been recently suggested that systemic or topical drugs acting in the wound repair and regeneration processes could be promising and useful agents in the treatment of chronic venous ulcers.<sup>32</sup> However, in a previously reported systematic review performed by Bradley *et al.*, 16 randomized controlled trials were identified that compared topic agents (growth factors, cell suspensions, free-radical scavengers) versus placebo for treating CVI ulcers, concluding that there was insufficient evidence to recommend any particular agent.<sup>33</sup>

The main finding was that topic application of liposomated LFR allowed a fast and progressive

**Table 2. Stratification of refluxes through ecodoppler (Type) and frequencies (No.) of pure or mixed forms of reflux.**

Systems	Type	No.
Superficial reflux only	One system	1
Perforating reflux only	One system	3
Deep reflux only	One system	0
Mixed superficial and perforating reflux	Two systems	3
Mixed perforating and deep reflux	Two systems	1
Mixed superficial, perforating and deep reflux	Three systems	1

**Table 3. Brown color scale: colorimetric evolution.**

Case no.	Baseline	Weeks					
		1	2	3	4	8	12
3446	26	17	13	11	9	7	7
3437 <sub>R</sub>	23	23	22	11	9	8	8
3437 <sub>L</sub>	25	18	17	14	11	10	9
3283	17	10	9	8	7	-	-
3334	19	18	17	14	11	10	8
3161	8	7	5	5	5	5	5
3441	18	17	14	14	13	8	5
3451	16	15	14	11	10	8	7
3274	18	16	14	11	10	8	7
3449	17	15	14	13	13	11	9

R, right; L, left.

**Table 4. Evolution of ulcerous area in cm<sup>2</sup> during the first six months of follow up.**

Case no.	Study start	Month 1	Month 2	Month 3	Month 4	Month 5	Month 6
3446	3.3	0.0	-	-	-	-	-
3437 <sub>R</sub>	6.5	0.1	0.1	0.0	-	-	-
3437 <sub>L</sub>	12.8	10.7	8.8	8	5.7	3.2	0.0
3283	4.5	5.8	7.2	8.3	4.5	Deserted	
3334	3.1	0.5	0.2	0.1	0.0	-	-
3161	6.0	5.1	7.5	6.4	4.7	2.7	0.0
3441	19.9	8.8	0.6	0.0	-	-	-
3451	23.6	11	3.5	2.1	0.0	-	-
3274	3.6	0.8	1.8	0.3	0.5	0.2	0.0
3449	9.6	6.2	6.7	6.2	5.2	4.9	0.0

R, right; L, left.

**Table 5. Time (months) taken to achieve complete closure of the 10 lesions from 9 patients.**

Time (months)	Number closed lesions	Total
1	1/10	1
3	2/10	3
6	6/10*	9

\*One patient left the study.

reduction in the dimensions of the area of the ulcer in 9 of 9 patients and complete closure in 7 of 9 cases. The 90 days of evolution evidenced an important improvement in the injuries, with a reduction in the intensity of the brown color of the spot (9 of 9) and time to complete scarring ranging from 15 to 180 days (7 of 9). It is important to emphasize that the patients belonged to the group of refractory cases included in the previous study already mentioned.<sup>16</sup> This assay showed that 50% of ulcers showed complete closure using medical compression stockings, and 67% of complete closure with multilayer bandages, after 180 days.

One of the most remarkable findings was the significant decrease, in all cases, of the brown color of the HD and the size of the ulcerous areas (Figures 5 and 6), with a concomitant goniometric improvement (Table 7), and complete closure of lesions in 7 cases after six months of treatment. The rate of healing was independent of baseline or recurrent ulcers (Figure 5).

In all patients, clinical improvement of the wounds (10 ulcers) was associated with a significant decrease in pain and improvement in quality of life, except in one case (\*case no. 3161) due to a domestic accident on the lesion, which showed no clinical improvement and led to the patient discontinuing treatment (Figure 6, Tables 8 and 9). All biopsies showed changes in cytological patterns (Figure 7). In several cases, a decrease was seen in the high level of stain-

**Table 6. Edema control in cm<sup>3</sup>: volumetric variation in leg edemas.**

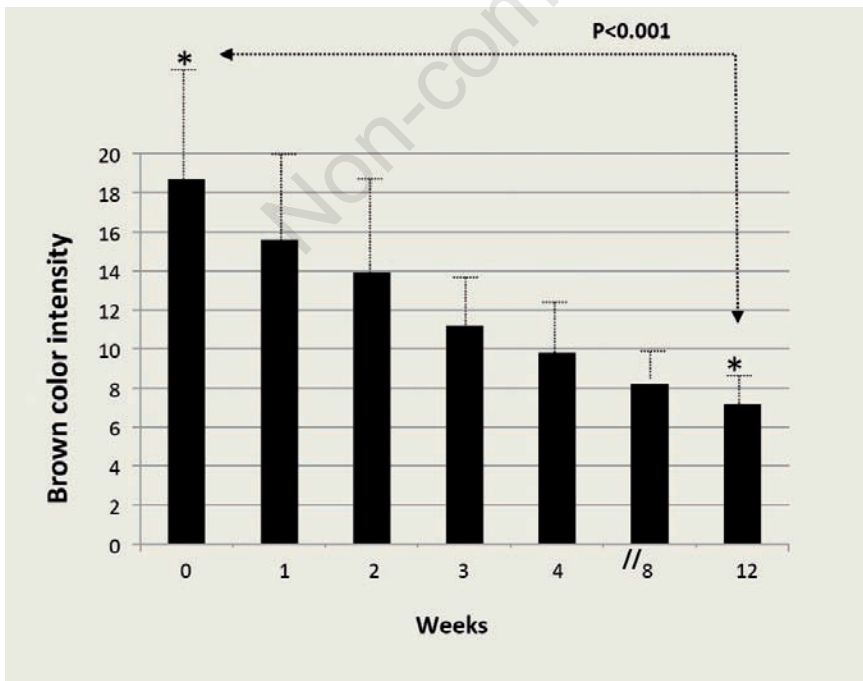
Case no.	Basal	Week 1	Week 2	Week 3	Week 4	Week 8	Week 12
3446	4227	4127	4089	4072	3958	3932	3886
3437 <sub>R</sub>	9457	9409	9678	9623	9562	9549	9605
3437 <sub>L</sub>	9963	9856	9777	9670	9581	9588	9540
3283	4215	4122	4092	4061	4011	3999	3980
3334	4747	4680	4565	4548	4495	4424	4366
3161	3163	3056	3431	3214	3125	3008	2998
3441	4149	4011	4020	3977	3959	3884	3892
3451	4480	4314	4241	4204	4115	4097	4161
3274	4261	4008	3878	4129	4114	4059	3993
3449	4737	4512	4498	4451	4388	4275	4174

R, right; L, left.

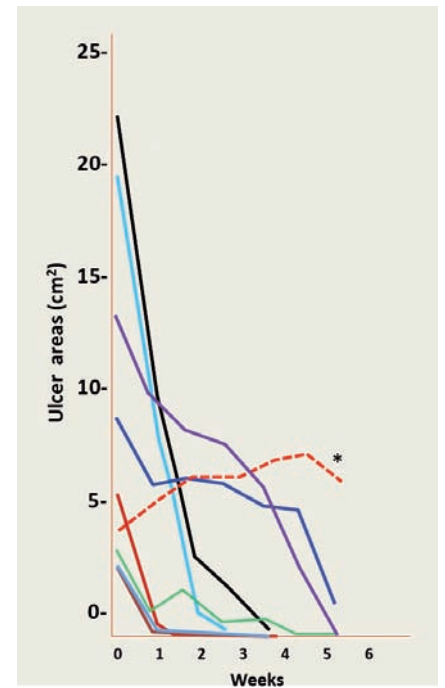
**Table 7. Baseline-final goniometry. Goniometric values before and after 30 days of treatment.**

Case no.	BG (flx)	FG (flx)	BG (ext)	FG (ext)
3446	12°	12°	30°	42°
3437 <sub>R</sub>	10°	19°	22°	25°
3447 <sub>L</sub>	9°	10°	22°	24°
3283	5°	12°	25°	35°
3334	10°	12°	30°	35°
3161	10°	12°	19°	28°
3441	3°	10°	37°	40°
3451	9°	12°	22°	24°
3274	10°	11°	20°	23°
3449	9°	10°	15°	30°

R, right; L, left; BG, baseline; FG, final goniometry; flx, flexion; ext, extension.



**Figure 5. Variation in brown color scale values during the treatment.**



**Figure 6. Ulcer's areas diminution during six weeks of follow up.**



ing for HS in periulcerous and ulcer fundus biopsies present during the initial control (Figure 8) and this associated with a significant improvement in the edema and ulcerous areas (Figure 9) after treatment.

Iron deposits in the skin of patients with CVI cause readily visible HD (brown colored dermal areas) that always surrounds ulcers. The origin of increased iron loads in these lesions lies in the extravasations of red blood cells during significant venous stasis. Erythrocytes are degraded by resident dermal macrophages, and iron is incorporated into ferritin which, in time, changes to HS according to progressive iron overload.<sup>30,32</sup> Furthermore, the urinary excretion of hemosiderin described in these patients<sup>4,33</sup> suggests that the phenomenon of leg hemosiderin deposits could be of significance on the entire body.<sup>34,35</sup> However, in contrast with this hypothesis, in 1988 Ackermann found a 20-fold higher average concentration of iron in lower limbs affected by venous ulcers as compared to the upper arms of the same subjects.<sup>2</sup>

The distribution of high levels of ferritin staining in leg ulcers of patients with CVI were reported to be located intra and extracellular in the matrix, as compared with normal skin tissue with considerably less alterations or non-evident alterations at all.<sup>11</sup> However, the systemic parameters of iron metabolism observed in our study (Table 7) did not seem to influence either the severity of HD nor the evolution of treatment with local LFR. Furthermore, the abnormal levels of ferritin observed in some patients did not limit the previously mentioned improvement in the ulcers. However, it is important to note that potential co-morbidities could be associated to systemic iron overload. One case that presented an altered reflux caused by the combination of the three systems associated with a severe hemodynamic condition was also a carrier of an HFE gene mutation (heterozygous), evidencing high levels of serum ferritin (222 and 244 ng/mL), and suffered a sudden death. In another case with elevated serum ferritin (405 and 355 ng/mL) the patient experienced heart insufficiency and later stroke. Finally, the patient with bilateral ulcers also exhibited high serum ferritin values (233 and 251 ng/mL).

We still do not know with certainty if ferritin could constitute a prognostic evolutive parameter, but its association to the clinical evolution observed in 3/9 patients suggests that it should be included in follow-up protocols.

Because all parameters studied including ulcer lesion features, as well as quality of life (CIVIQ) and pain (Likert's scale) were improved after treatment, topic application of liposomed LF could be a new therapeutic strategy, particularly in patients with refractory ulcers and HD associated secondary to chronic venous insufficiency.

**Table 8. Pain control using the Likert scale comparing baseline values with those obtained at Week 4.**

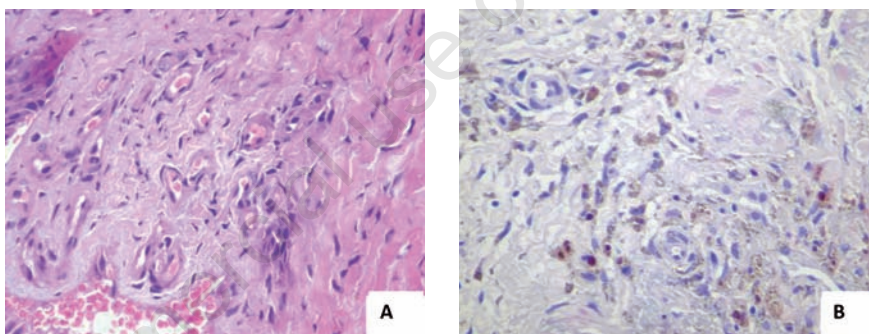
Case no.	Baseline	Week 4
3446	1	1
3437 <sub>R</sub>	5	1
3437 <sub>L</sub>	5	1
3283	5	3
3334	3	2
3161*	2	3
3441	5	2
3451	5	1
3274	2	1
3449	5	1

R, right; L, left. \*One patient left the study.

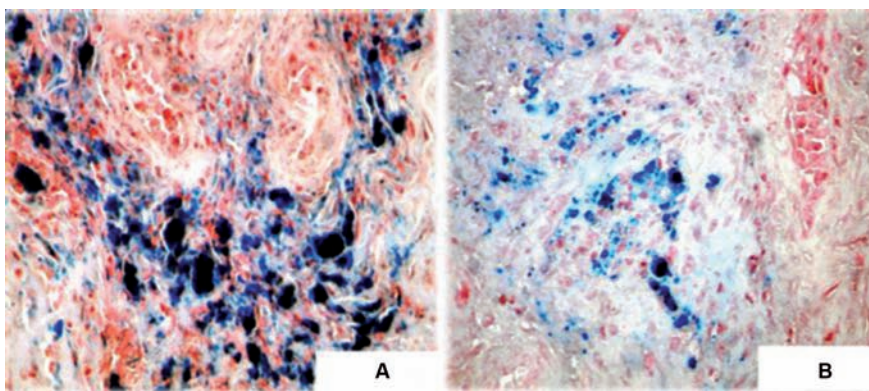
**Table 9. Positive chronic lower limb venous insufficiency score: variation between baseline and final values were observed in all cases except in one patient (\*) who discontinued treatment.**

Case no.	Baseline	Final	B-F
3446	35	33	2
3437	83	75	8
3283	66	59	7
3334	53	47	6
3161*	49	53	-4
3441	73	60	13
3451	89	80	9
3274	67	60	7
3449	71	66	5

B, baseline; F, final. \*One patient left the study.



**Figure 7. (A) Histological features before treatment: presence of fibrin sleeves, small vessels, extravasations of red blood cells, fibrosis, chronic inflammatory pattern. (B) Histological features after treatment (4 weeks): presence of new vascular structures, extravasations of red blood cells, fibrosis and granulation tissue-granulation, chronic repairing inflammatory pattern.**



**Figure 8. Baseline sample (A) showed high hemosiderin concentration (local iron overload) with (B) an evident reduction in hemosiderin staining after four weeks of treatment.**

As regards its iron binding properties, LFR differs from serum transferrin in its higher iron binding affinity and unique ability to retain iron over a broad pH range.<sup>1</sup> The protective effects of topic LFR on induced dermatological allergic process was demonstrated experimentally.<sup>36</sup> Similar results were obtained in a study carried out on human volunteers, treated by topical administration of the contact allergen and

using purified recombinant human LFR.<sup>37</sup> Although originally identified as an abundant protein in milk secretions, LFR is mainly expressed by surface epithelia and secreted into the mucosal environment. However, further research is needed to clarify whether local iron mobilization, free radical scavenging and induction to tissue repair are simultaneously staged by the multiple properties of LF.

## Conclusions

Our results suggest that the topical use of LFR could be a potential non-invasive therapeutic tool that favors clearance of HD and a faster closure of ulcers, with concomitant relief or disappearance of pain, and consequent improvement in quality of life in patients with chronic venous insufficiency. Further research is needed to confirm these results by prospective randomized controlled studies.

## References

1. Raju S, Neglen P. Chronic venous insufficiency and varicose veins. *N Engl J Med* 2009;360:2319-27.
2. Ackerman Z, Seidenbaum M, Loewenthal E, Rubinow A. Overload of iron of patients with varicose ulcers: possible contributing role of iron accumulation in progression of the disease. *Arch Dermatol* 1988;124:1376-8.
3. Allegra C, Antignani PL, Bergan JJ, et al. International Union of Phlebology Working Group. The "C" of CEAP: suggested definitions and refinements: an International Union of Phlebology conference of experts. *J Vasc Surg* 2003;37:129-31.
4. Piotrowicz R, Grzela T, Jawień A, Kuligowska-Prusińska M. Urine haemosiderin: a marker of chronic venous insufficiency. *Acta Angiol* 2009;15:101-7.
5. Weintraub L, Demis D, Conrad M, Crosby W. Iron excretion by the skin selective localization of iron in epithelia cells. *Am J Pathol* 1965;46:121-7.
6. Bissett DL, Chatterjee R, Hannon DP. Chronic ultraviolet radiation induced increase in skin iron and the photo protective effects of topically applied iron chelators. *Photochem Photobiol* 1991;54:215-23.
7. Takeshita K, Takajo T, Hirata H, et al. In vivo oxygen radical generation in the skin of the protoporphyrin model mouse with visible light exposure: an L-band ESR study. *J Invest Dermatol* 2004;122:1463-70.
8. Gira AK, Casper KA, Otto KB, et al. Induction of interferon regulatory factor 1 expression in human dermal endothelial cells by interferon-gamma and tumor necrosis factor-alpha is transcriptionally regulated and requires iron. *J Invest Dermatol* 2003;121:1191-6.
9. Bhasin G, Kausar H, Sarwar Alam M, Athar M. Progressive iron overload enhances chemically mediated tumor promotion in murine skin. *Arch Biochem Biophys* 2003;409:262-73.
10. Chevrant-Breton J, Simon M, Bourel M, Ferrand B. Cutaneous manifestations of

Table 10. Iron metabolism profile.

Case no.	Iron $\mu\text{dL}$		TIBC $\mu\text{dL}$		Transferrin sat. (%)		Ferritin ng/mL	
	1°	2°	1°	2°	1°	2°	1°	2°
3446	38	53	361	253	10.5	20.1	25	23.8
3437	61	58	302	306	20.1	19	233	251
3283	60	74	263	265	23.5	27.9	117	126
3334	73	53	325	382	22.4	18.9	222	244
3161	57	48	297	311	19	15.4	82	72.9
3441	52	44	309	325	16.8	13.5	26	31.3
3451	73	70	198	212	36.8	33	405	355
3274	128	120	296	301	43	40	197	201
3449	72	66	250	251	28.8	26.2	112	117

TIBC, total iron binding capacity.

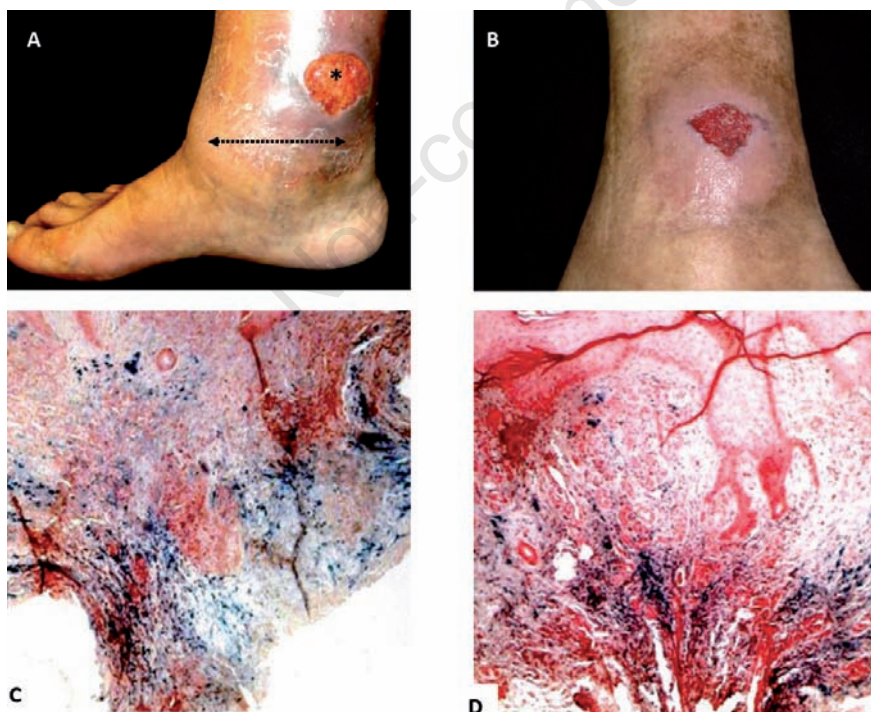


Figure 9. Comparison of severity of lesion before (A, C) and after (B, D) treatment. (A and B) Size of ulcers and (C and D) edema. Intensity of hemosiderin staining. Decreasing dimensions of edema and ulcers correlate with a lower staining hemosiderin observed after treatment (A and B).



- idiopathic hemochromatosis. Study of 100 cases. *Arch Dermatol* 1977;113:161-5.
11. Zamboni P, Tognazzo S, Izzo M, et al. Hemochromatosis C282Y gene mutation increases the risk of venous leg ulceration. *J Vasc Surg* 2005;42:309-14.
  12. Valenti P, Berlutti F, Conte MP, et al. Lactoferrin functions: current status and perspectives. *J Clin Gastroenterol* 2004;38 Suppl 6:S127-9.
  13. Tang L, Wu JJ, Ma Q, et al. Human Lactoferrin stimulates skin keratinocyte function and wound re-epithelialization. *Br J Dermatol* 2010;163:38-47.
  14. Engelmayer J, Blezinger P, Varadhachary A. Talactoferrin stimulates wound healing with modulation of inflammation. *J Surg Res* 2008;149:278-86.
  15. Brizzio E, Blättler W, Rossi G, et al. Healing venous ulcers with different modalities of leg compression. Unexpected findings of a pilot study. *Phlebologie* 2006;35:249-55.
  16. Brizzio E, Amsler F, Lun B, Blättler W. Comparison of low-strength compression stockings with bandages for the treatment of recalcitrant venous ulcers. *J Vasc Surg* 2010;51:410-6.
  17. Blättler W, Lüscher D, Brizzio E, et al. Healing of chronic venous leg ulcers could be affected by an interaction of the hemochromatosis gene polymorphism HFE H63D with the strength of compression treatment - a re-analysis of patients from previous studies. *Wound Repair Regen* 2012;20:120-4.
  18. Perrin M, Guex JJ. Edema and leg volume: methods of assessment. *Angiology* 2000;51:9-12.
  19. Rossi G, Idiazabal G. Mathematical model to obtain the volume of the lower limb. *Int Angiol* 2005;3 Suppl 1:110. [Abstract].
  20. Belczak CEQ. Fisiologia do sistema venoso. In: Thomaz JB, Belczak CEQ (eds.). *Tratado de flebologia y linfologia*. Rio de Janeiro: Editorial Rubio; 2006. pp 37-70.
  21. Likert R. A technique for the measurement of attitudes. *Archiv Psychol* 1932;140:1-55.
  22. Launois R, Reboul-Marty J, Henry B. Construction and validation of a quality-of-life questionnaire in chronic lower limb venous insufficiency (CIVIQ). *Qual Life Res* 1996;5:539-54.
  23. Boom R, Sol C, Salimans M, et al. Rapid and simple method for purification of nucleic acids. *J Clin Microbiol* 1990;28:495-503.
  24. Baptista-González HA, Rosenfeld-Mann F, Trueba-Gómez R, et al. Association of HFE mutations (C282Y and H63D) with iron overload in blood donors from Mexico City. *Ann Hepatol* 2007;6:55-60.
  25. Oliveira VC, Caxito FA, Gomes KB, et al. Frequency of the S65C mutation in the hemochromatosis gene in Brazil. *Genet Mol Res* 2009;8:794-8.
  26. Herrick SE, Sloan P, McGurk M, et al. Sequential changes in histologic pattern and extracellular matrix deposition during the healing of chronic venous ulcers. *Am J Pathol* 1992;141:1085-95.
  27. Bancroft J, Gamble M (eds.). *Theory and practice of histological techniques* bancroft & gamble. 6th edition. London: Churchill-Livingstone, Elsevier Health Sciences; 2008.
  28. Brizzio E, Idiazabal G. Multilayer system. *Rev Acta Flebol* 2003;3:65-8.
  29. Beebe-Dimmer JL, Pfeifer JR, Engle JS, Schottenfeld D. The epidemiology of chronic venous insufficiency and varicose veins. *Ann Epidemiol* 2005;15:175-84.
  30. Eming SA, Kiegl T, Davidson JM. Inflammation in wound repair: molecular and cellular mechanisms. *J Invest Dermatol* 2007;127:514-25.
  31. Werner S, Grose R. Regulation of wound healing by growth factors and cytokines. *Physiol Rev* 2003;83:835-70.
  32. Palfreyman S, King B, Walsh B. A review of the treatment for venous leg ulcers. *Br J Nurs* 2007;16:S6-14.
  33. Bradley M, Cullum N, Nelson EA, et al. Systematic reviews of wound care management: (2) Dressings and topical agents used in the healing of chronic. *Health Technol Assess* 1999;3:1-35.
  34. Zamboni P, Scapoli G, Lanzara V, et al. Serum iron and MMP-9 variations in limbs affected by chronic venous disease and venous leg ulcers. *Dermatol Surg* 2005;31:644-9.
  35. Zamboni P, Izzo M, Tognazzo S, et al. The overlapping of local iron overload and HFE mutation in venous leg ulcer pathogenesis. *Free Radic Biol Med* 2006;40:1869-73.
  36. Zweiman B, Kucich U, Shalit M, et al. Release of lactoferrin and elastase in human allergic skin reactions. *J Immunol* 1990;144:3953-60.
  37. Griffiths CE, Cumberbatch M, Tucker SC, et al. Exogenous topical Lactoferrin inhibits allergen-induced Langerhans cell migration and cutaneous inflammation in humans. *Br J Dermatol* 2001;144:715-25.