

# Endovascular treatment of sciatic pain from venous congestion in the pelvis. A technical note

Maddalena Bressan,<sup>1</sup> Ilaria Massi,<sup>1</sup> Elpiniki Tsolaki,<sup>2</sup> Roberto Galeotti<sup>3</sup>

<sup>1</sup>School of Vascular Surgery, S. Anna University Hospital of Ferrara; <sup>2</sup>Unit of Vascular Surgery and Endovascular Surgery, Department of Cardiothoracic and Vascular Surgery, S. Anna University Hospital, Ferrara; <sup>3</sup>Unit of Interventional Radiology, Department of Radiology, S. Anna University Hospital of Ferrara, Italy

## Abstract

Klippel-Trénaunay Syndrome (KTS) is a vascular disorder characterized by a combination of vascular malformations (capillary, lymphatic, and venous) and limb overgrowth. Pelvis involvement is less frequent and is often underrecognized. We report a case of a patient affected by KTS with persistent sciatic pain. Phlebography demonstrated significant pelvic venous congestion

mainly due to reflux at the level of the sacral plexus venous. A minimally invasive approach was successfully utilized to treat reflux with complete pain regression.

## Introduction

Klippel-Trénaunay Syndrome (KTS) is a rare and complex disorder that affects the development of blood vessels, soft tissues (skin and muscles), and bones. The etiology remains unknown, though it has been attributed to both genetic and environmental factors.<sup>1</sup> Common symptoms include port-wine stains, present in 90-100% of cases,<sup>2</sup> varicosities and hypertrophy of soft tissues and/or long bones.<sup>3</sup> Recurrent deep vein thrombosis and pulmonary embolism have also been reported<sup>2,3</sup> and lymphedema due to lymphatic abnormalities is present in 15-50% of cases.<sup>4,5</sup> Venous malformations comprise varicosities and agenesis, atresia of the deep venous system, persistent embryonic veins and anomalous venous valve formation and result in abnormal reflux in venous system.<sup>6</sup> Pain, swelling, hyperpigmentation, thrombophlebitis, variceal bleeding, and ulceration represent frequent symptoms of KTS. Pain affects as many as 88% of the patients and may occur due to bone, tissue, peripheral nerve hypertrophy, the presence of microscopic epineural Arteriovenous Anastomoses (AVA), vascular abnormalities and pelvic congestion.<sup>7-9</sup>

Management of KTS is primarily non-surgical and multidisciplinary due to the wide variability of clinical presentations, extension of the disease, and stages of severity. All therapeutic measures aim to prevent complications and treat symptoms such as swelling, inflammation, limb asymmetry, and pain. Symptoms related to venous congestion, such as pelvic pain, present significant challenges.<sup>2</sup> Mild symptoms are usually managed similarly to those caused by common chronic venous disorders (considering the possible involvement of the deep venous system), with conservative management (compression stockings, intermittent pneumatic compression, and medical therapy).<sup>3</sup> Invasive treatment, however, may be necessary in case of severe pain due to severe venous stasis, pelvic hemorrhage, or due to rupture of the dilated veins. Stripping of lateral veins, excision of varicosities, ligation of perforator veins, and laparoscopic pelvic vein ligation represent surgical options to reduce circulatory overload.<sup>10,11</sup> In rare cases of severe hemorrhage, partial cystectomy and hysterectomy may be necessary.<sup>12</sup> Currently, less invasive, endovascular techniques such as transcatheter coil embolization, and the “sandwich technique” with foam sclerotherapy or other methods of injection of sclerosing agents are reported to have satisfactory outcomes.<sup>13-16</sup>

Correspondence: Elpiniki Tsolaki, Unit of Vascular and Endovascular Surgery, S. Anna University Hospital, via Aldo Moro 8, 44124 Cona (Ferrara), Italy.  
E-mail: niki.tsolaki@gmail.com

Key words: Klippel-Trenaunay Syndrome, sciatic pain, pelvis venous congestion, phlebography, foam sclerotherapy, endovascular treatment.

Contributions: all the authors made a substantive intellectual contribution. All the authors have read and approved the final version of the manuscript and agreed to be held accountable for all aspects of the work.

Conflict of interest: the authors declare no potential conflict of interest.

Funding: none.

Informed consent: we confirm that written informed consent for patient information and images to be published was provided by the patient.

Availability of data and materials: all data generated or analyzed during this study are included in this published article.

Received: 23 November 2023.  
Accepted: 14 December 2023.  
Early view: 15 December 2023.

©Copyright: the Author(s), 2023  
Licensee PAGEPress, Italy  
Veins and Lymphatics 2023; 12:12124  
doi:10.4081/vl.2023.12124

This work is licensed under a Creative Commons Attribution-NonCommercial 4.0 International License (CC BY-NC 4.0).

*Publisher's note: all claims expressed in this article are solely those of the authors and do not necessarily represent those of their affiliated organizations, or those of the publisher, the editors and the reviewers. Any product that may be evaluated in this article or claim that may be made by its manufacturer is not guaranteed or endorsed by the publisher.*

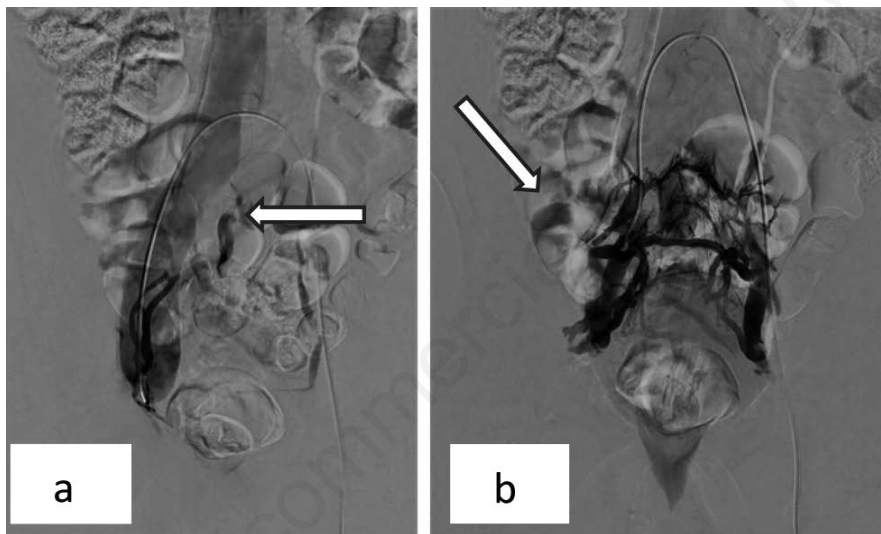
### Case Report

A 42-year-old Caucasian male with a history of KTS was referred to our outpatient clinic for persistent and severe pain in the affected limb. Radiofrequency ablation therapy of the right great saphenous vein and tributaries had been previously performed to treat vein incompetence, alleviate pain, and reduce swelling. One year later, the patient reported the onset of buttock pain that worsened by the sitting position.

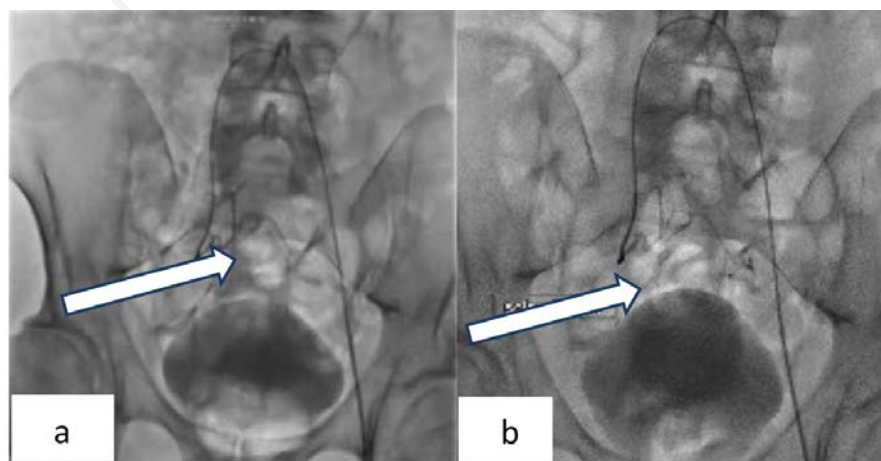
The neurological assessment during the physical examination as well as a lumbar Magnetic Resonance Imaging (MRI) study later performed, prescribed by the general practitioner, failed to demonstrate nerve root compression, herniated disk, or any other osteomuscular etiology. The duplex scan examination showed obliteration and no reflux at the right great saphenous vein and no signs of thrombosis at the deep venous system. Considering the patient was affected by the KTS and having excluded the bone eti-

ology, pelvic venography was planned. In the hybrid suite and under local anesthesia, venography was performed through a percutaneous, contralateral, common femoral vein access. This exam showed no significant defects regarding the inferior cava vein and the left common iliac axis, but demonstrated reflux in the left sacral venous plexus with retrograde opacification of the internal iliac veins. On the right side, the common and external iliac veins appeared significantly dilated, and the retrograde study of the right internal vein detected reflux at the level of the sacral venous plexus considerably more evident than at the contralateral side (Figure 1 a,b). Finally, the common femoral vein ostial valve was revealed competent with regular opacification of the deep femoral and inferior epigastric veins.

Selective cannulation and transcatheter sclerotherapy of the sacral venous plexus and its tributaries was performed by injection of foam of polidocanol 3% with a ratio 1:4 sclerosant to room air and mixed via the classic Tessari method (Figure 2 a,b).



**Figure 1.** The retrograde study of the right internal vein detected reflux at the level of the sacral venous plexus considerably more evident than at the contralateral side.



**Figure 2.** Selective cannulation and transcatheter sclerotherapy of the sacral venous plexus and its tributaries was performed by injection of foam of polidocanol 3% with a ratio 1:4 sclerosant to room air and mixed via the classic Tessari method.

Postoperative recovery was uneventful except for the onset of moderate pelvic pain an hour after treatment, successfully managed with analgesics. The patient was discharged in the same evening after the endovascular procedure in stable hemodynamic conditions. At 1 and 3 months, clinical controls confirmed regression of the sciatic pain. Further follow-up controls were scheduled at 6 months and then annually.

## Discussion

In this report, we describe a successful treatment of a patient affected by KTS presenting with sciatic pain and proximal sacral venous plexus reflux. In current literature, the incidence of pelvis involvement is reported as high as over 30% in KTS,<sup>17</sup> and different studies describe nerve-related symptoms due to venous congestion.<sup>18-20</sup> Pelvic congestion syndromes such as the Nutcracker Syndrome and May-Thurner Syndrome have been largely reported in the literature.<sup>21,22</sup> Lemos *et al.* described intrapelvic cases of sciatica caused by malformed or dilated branches of iliac vessels, prevalently in females, successfully treated with surgical decompression by vessel ligation.<sup>23,24</sup> Ricci *et al.* described lower limb sciatic pain, due to vein incompetence at the level of the popliteal fossa.<sup>25</sup> In the pelvis, the SN originates close to the sacral plexus and its proximal part runs precisely through it. Therefore, sacral vein reflux may be responsible for sciatic nerve pain, as in our case. Unfortunately, in contrast to the lower limb vein system, routinely evaluated with an ultrasound exam, pelvic veins, which may involve the SN at the origin of its course, are rarely investigated with selective venography. In our patient, standard venography efficiently evaluated the pelvis venous system and identified the presence of sacral venous reflux. This allowed us to provide prompt and effective treatment confirmed by sciatica pain relief as was referred by the patient at the follow-up controls.

## Conclusions

Pelvic venous congestion should be considered in cases of no identifiable spinal or musculoskeletal causes of sciatic pain. Accurate patient physical evaluation and radiological imaging are mandatory to investigate infrequent causes of this neuropathy and suggest appropriate therapy. Minimal invasive transcatheter treatment of refluxing sacral vein plexus represents a valid therapeutic option.

## References

- Sunderkrishnan R. Genetics of Klippel-Trenaunay-Weber Syndrome. 2022. Medscape Available from: <https://emedicine.medscape.com/article/945760-overview?form=fpf>
- Alwalid O, Makamure J, Cheng QG, et al. Radiological Aspect of Klippel-Trénaunay Syndrome: A Case Series With Review of Literature. *Curr Med Sci.* 2018;38:925-31.
- Wang SK, Drucker NA, Gupta AK, et al. Diagnosis and management of the venous malformations of Klippel-Trénaunay syndrome. *J Vasc Surg Venous Lymphat Disord.* 2017;5:587-95.
- John PR. Klippel-Trenaunay Syndrome. *Tech Vasc Interv Radiol.* 2019;22:100634.
- Liu NF, Lu Q, Yan ZX. Lymphatic malformation is a common component of Klippel-Trenaunay syndrome. *J Vasc Surg.* 2010;52:1557-63.
- Wang H, Xie C, Lin W, et al. Internal Iliac Vein Reflux: An Underrecognized Pathophysiology in Klippel-Trénaunay Syndrome With Pelvis Involvement. *Cureus.* 2022;14:21472.
- Lee A, Driscoll D, Gloviczki P, et al. Evaluation and management of pain in patients with Klippel-Trenaunay syndrome: a review. *Pediatrics.* 2005;115:744-9.
- Meirer R, Huemer GM, Shafiqi M, et al. Sciatic nerve enlargement in the Klippel-Trenaunay-Weber syndrome. *Br J Plast Surg.* 2005 ;58:565-8.
- Burrows PE. Vascular malformations involving the female pelvis. *Semin Intervent Radiol.* 2008;25:347-60.
- Noel AA, Gloviczki P, Cherry KJ Jr, et al. Surgical treatment of venous malformations in Klippel-Trénaunay syndrome. *J Vasc Surg.* 2000;32:840-7.
- Servelle M. Klippel and Trénaunay's syndrome. 768 operated cases. *Ann Surg.* 1985;201:365-73.
- Cucinella G, Di Buono G, Geraci G, et al. Uterine Involvement in Klippel-Trenaunay Syndrome: A Rare But Relevant Event. Review of the Literature. *Front Surg.* 2022;9:893320.
- De Gregorio MA, Guirola JA, Alvarez-Arranz E, et al. Pelvic venous disorders in women due to pelvic varices: treatment by embolization: experience in 520 patients. *J Vasc Interv Radiol.* 2020;31:1560-9.
- Tessari L, Cavezzi A, Frullini A. Preliminary experience with a new sclerosing foam in the treatment of varicose veins. *Dermatol Surg.* 2001;27:58-60.
- Gloviczki P, Comerota AJ, Dalsing MC, et al. The care of patients with varicose veins and associated chronic venous diseases: clinical practice guidelines of the Society for Vascular Surgery and the American Venous Forum. *J Vasc Surg.* 2011;53:2S-48S.
- Senéchal Q, Echegut P, Bravetti M, et al. Endovascular Treatment of Pelvic Congestion Syndrome: Visual Analog Scale Follow-Up. *Frontiers in Cardiovascular Medicine.* 2021;8:751178.
- Wang H, Xie C, Lin W, et al. Internal Iliac Vein Reflux: An Underrecognized Pathophysiology in Klippel-Trénaunay Syndrome With Pelvis Involvement. *Cureus.* 2022;14:e21472.
- Berthelot JM, Douane F, Ploteau S, et al. Venous congestion as a central mechanism of radiculopathies. *Joint Bone Spine.* 2022;89:105291.
- Labropoulos N, Tiongson J, Pryor L, et al. Nonsaphenous superficial vein reflux. *J Vasc Surg.* 2001;34:872-7.
- Hallan DR, McNutt S, Reiter GT, et al. Dilated Epidural Venous Plexus Causing Radiculopathy: A Report of 2 Cases and Review of the Literature. *World Neurosurg.* 2020;144:231-7.
- Ahmed K, Sampath R, Khan MS. Current trends in the diagnosis and management of renal nutcracker syndrome: a review. *Eur J Vasc Endovasc Surg.* 2006;31:410-6.
- White JM, Comerota AJ. Venous Compression Syndromes. *Vasc Endovascular Surg.* 2017;51:155-68.
- Lemos N, Cancelliere L, Li ALK, et al. Superior gluteal vein syndrome: an intrapelvic cause of sciatica. *J Hip Preserv Surg.* 2019;6:104-8.
- Possover M, Forman A. Pelvic Neuralgias by Neuro-Vascular Entrapment: Anatomical Findings in a Series of 97 Consecutive Patients Treated by Laparoscopic Nerve Decompression. *Pain Physician.* 2015;18:E1139-43.
- Ricci S, Georgiev M, Jawien A, Zamboni P. Sciatic nerve varices. *Eur J Vasc Endovasc Surg.* 2005;29:83-7.