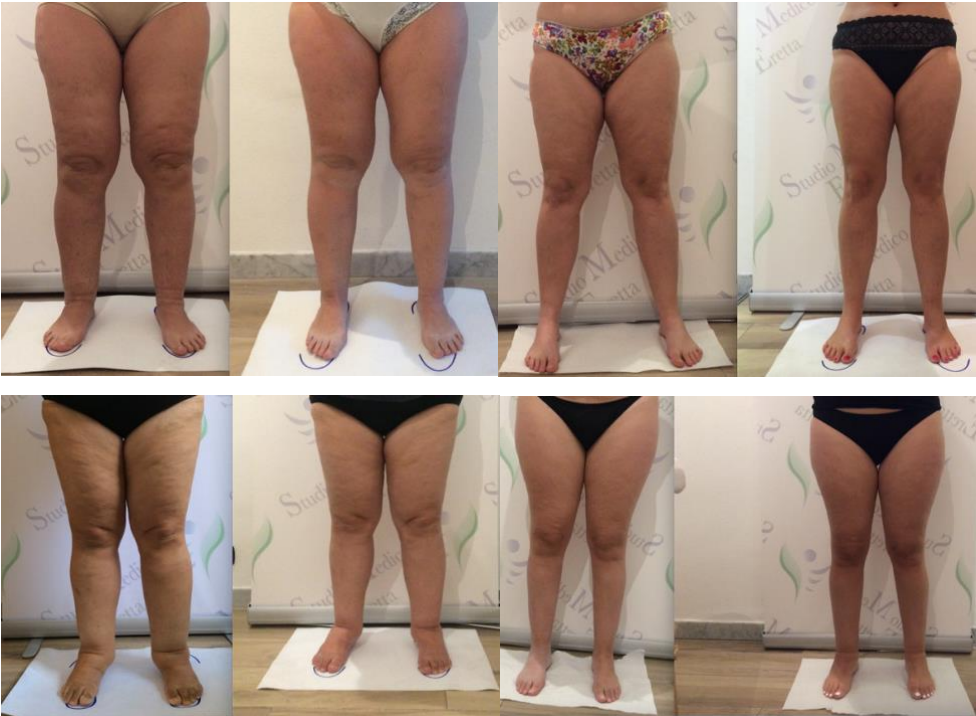
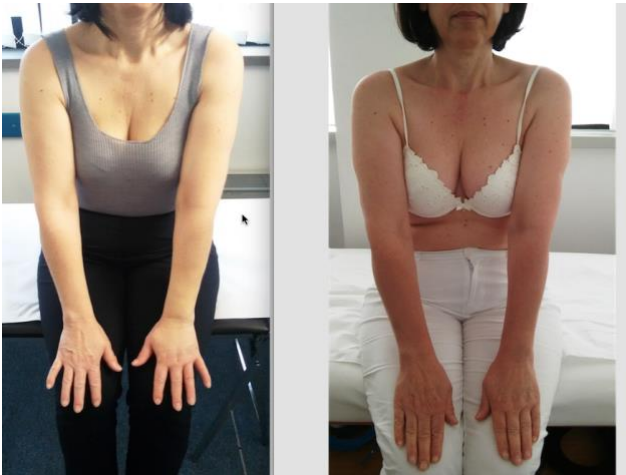
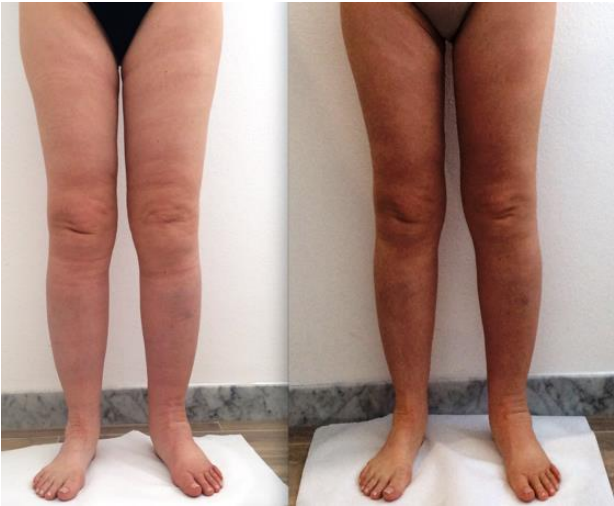**Supplementary Figure 1.** Patients affected by lipoedema at the lower limb in different steps while making Complex Decongestive Therapy (CDT).



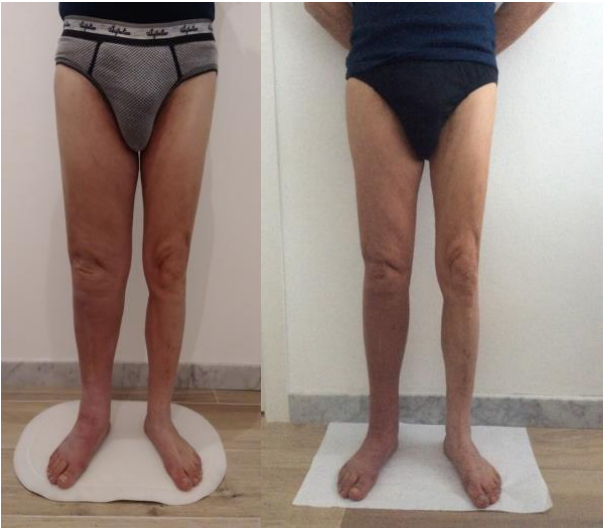**Supplementary Figure 2.** Breast cancer.



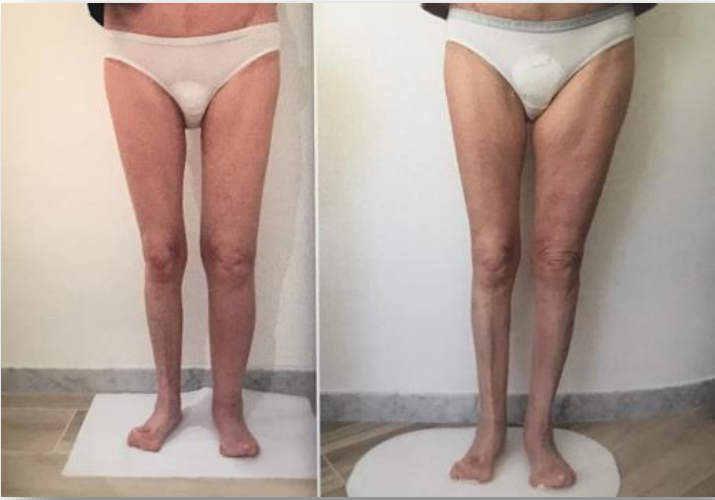**Supplementary Figure 3.** Hysterectomy.



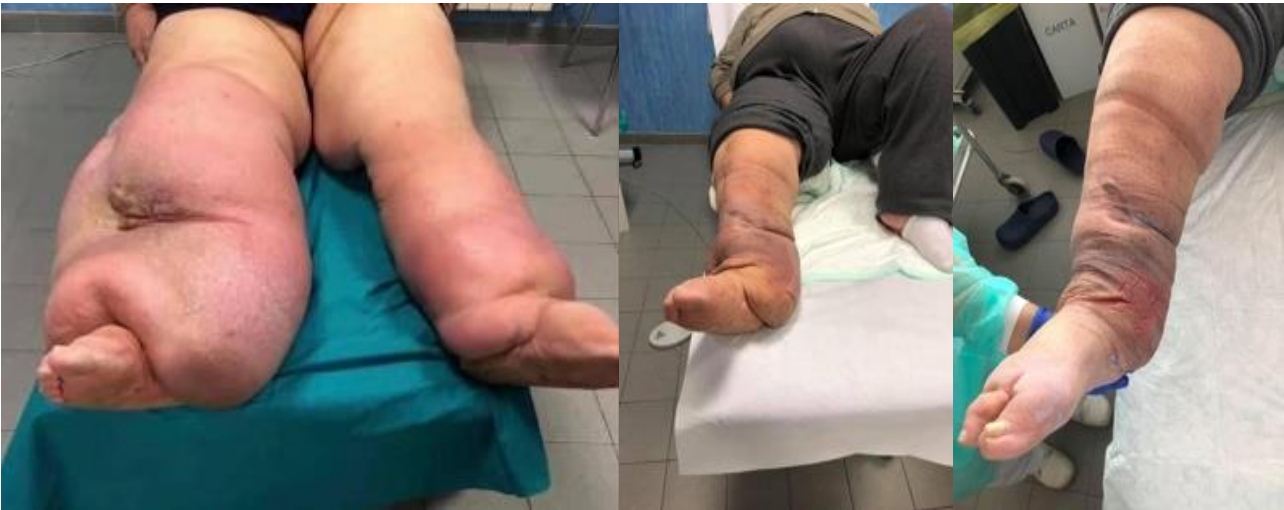**Supplementary Figure 4. Prostatectomy.**



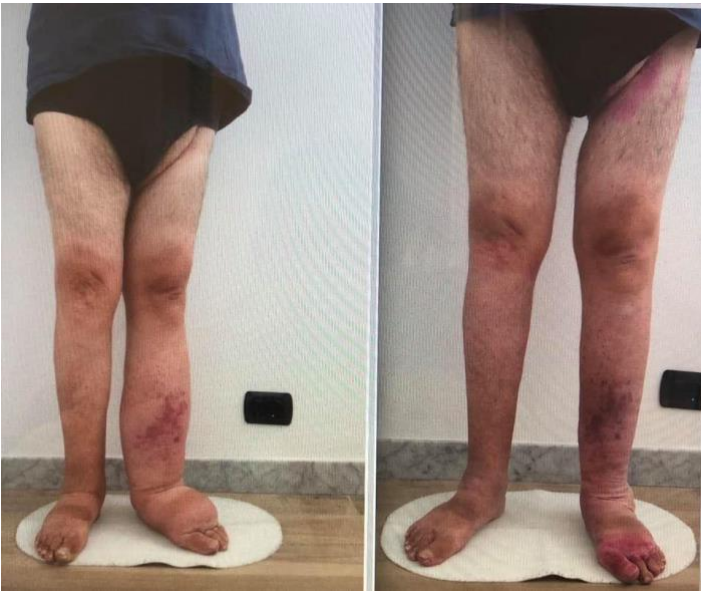**Supplementary Figure 5.** Hysterectomy.



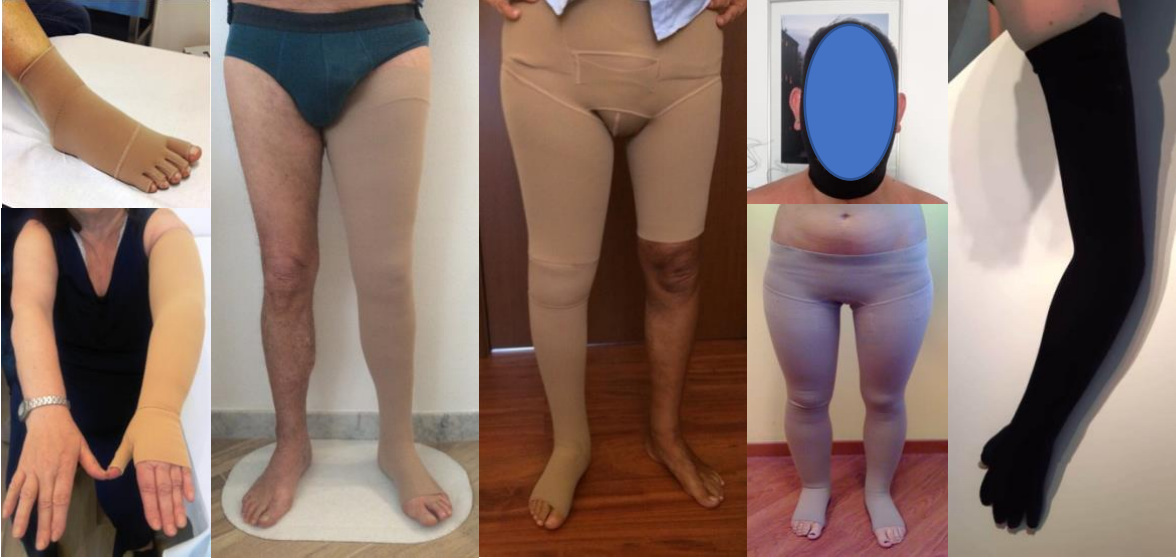**Supplementary Figure 6.** Primary lymphedema.



**Supplementary Figure 7.** Primary lymphedema.

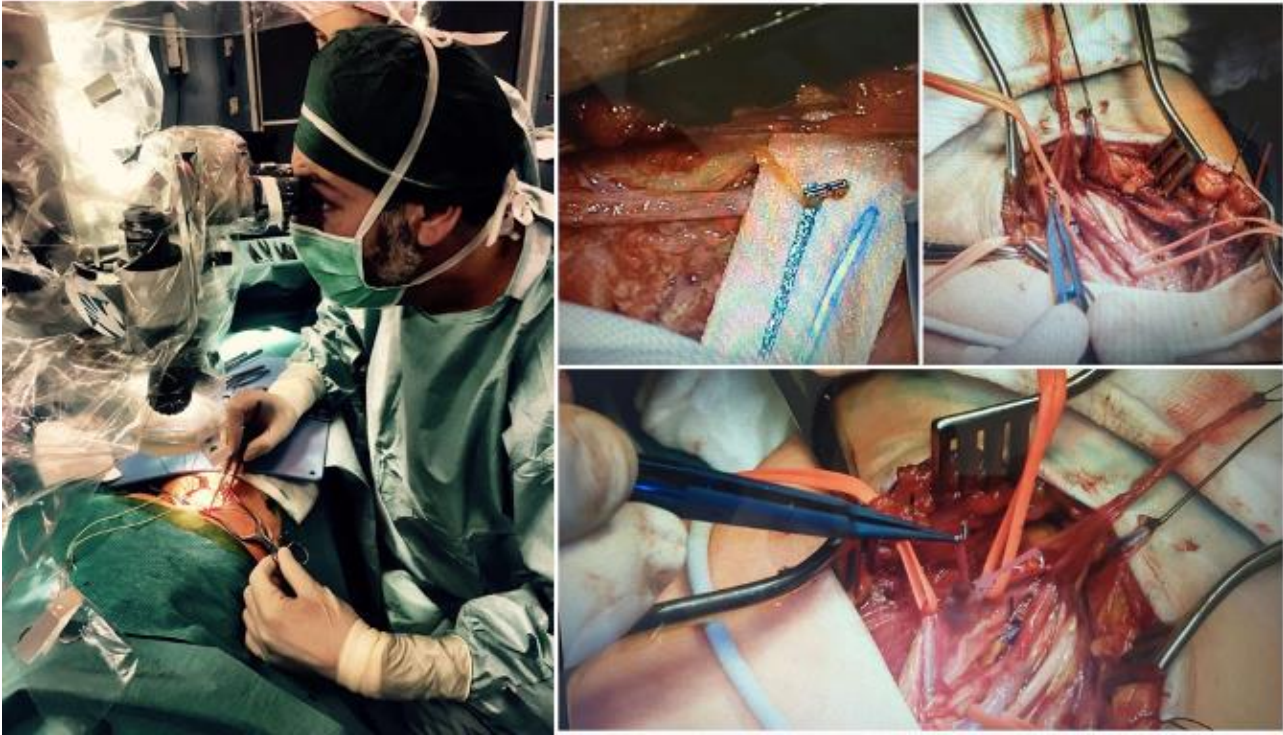


**Supplementary Figure 8.** Stabilization of lymphedema with elastic stocking.

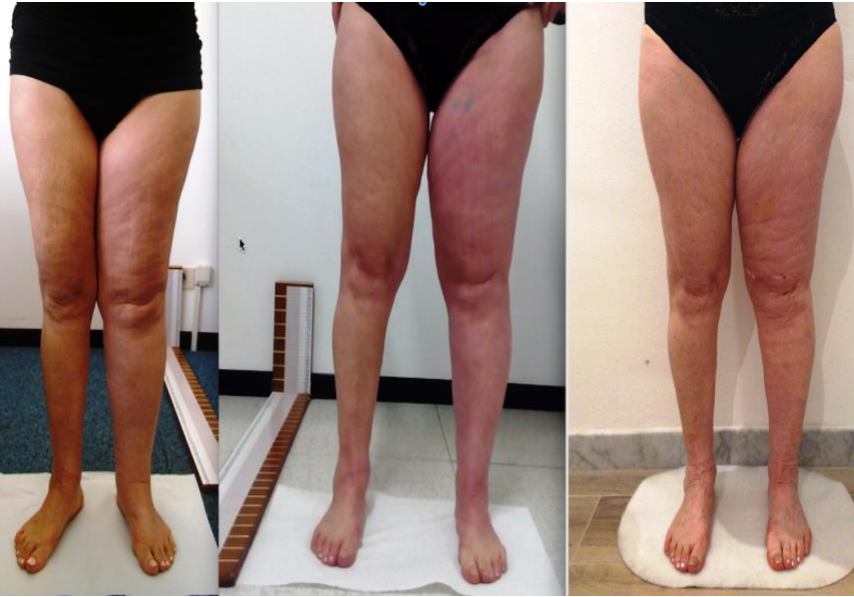




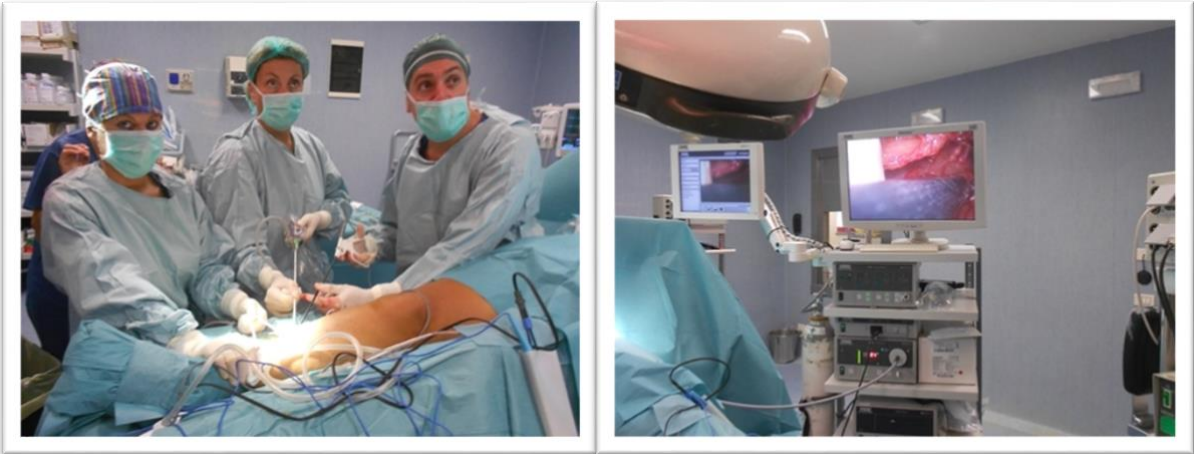**Supplementary Figure 9.** Lymphatic Venous Vein Anastomosis (LVA) one site with the microscope.



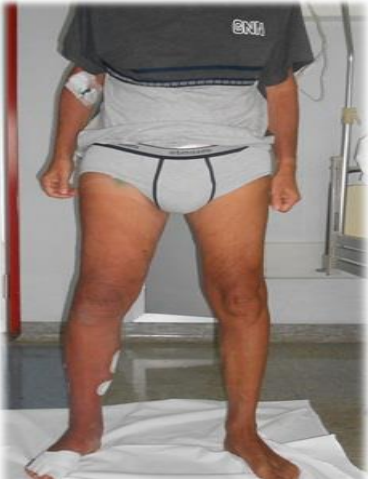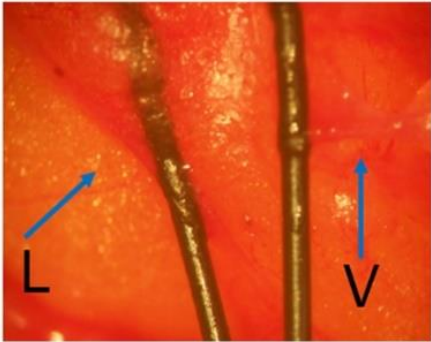
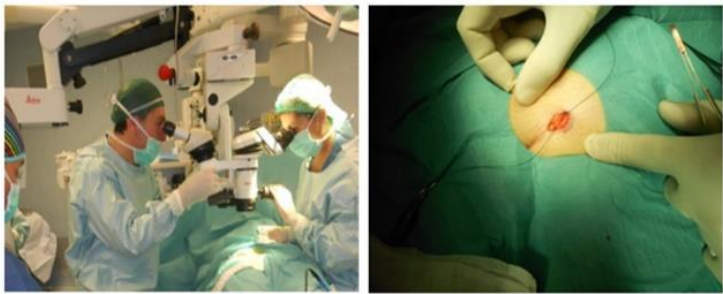**Supplementary Figure 10.** Secondary lymphedema results one site Lymphatic Venous Vein Anastomosis (LVA) + Complex Decongestive Therapy (CDT).



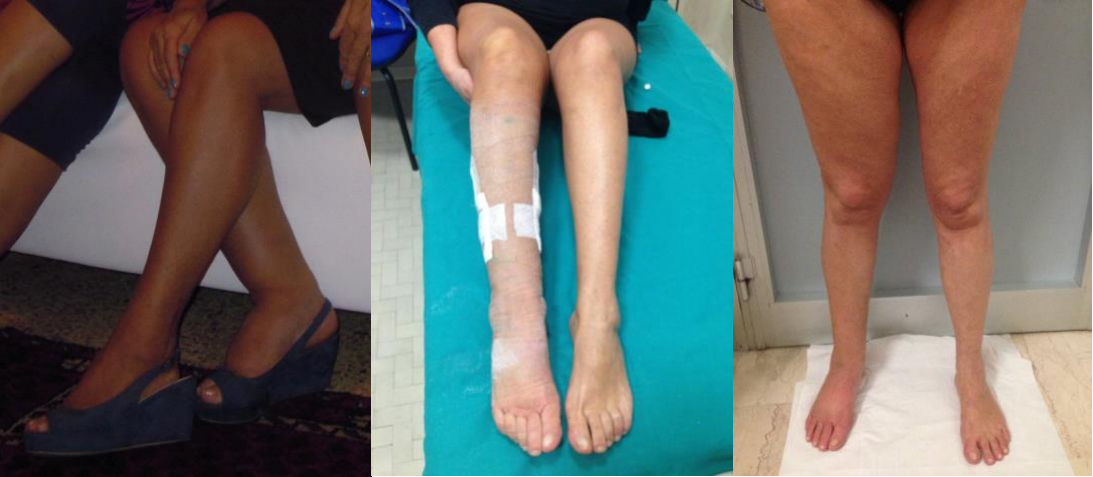**Supplementary Figure 11.** Mini-Invasive Fasciotomy (MIF).



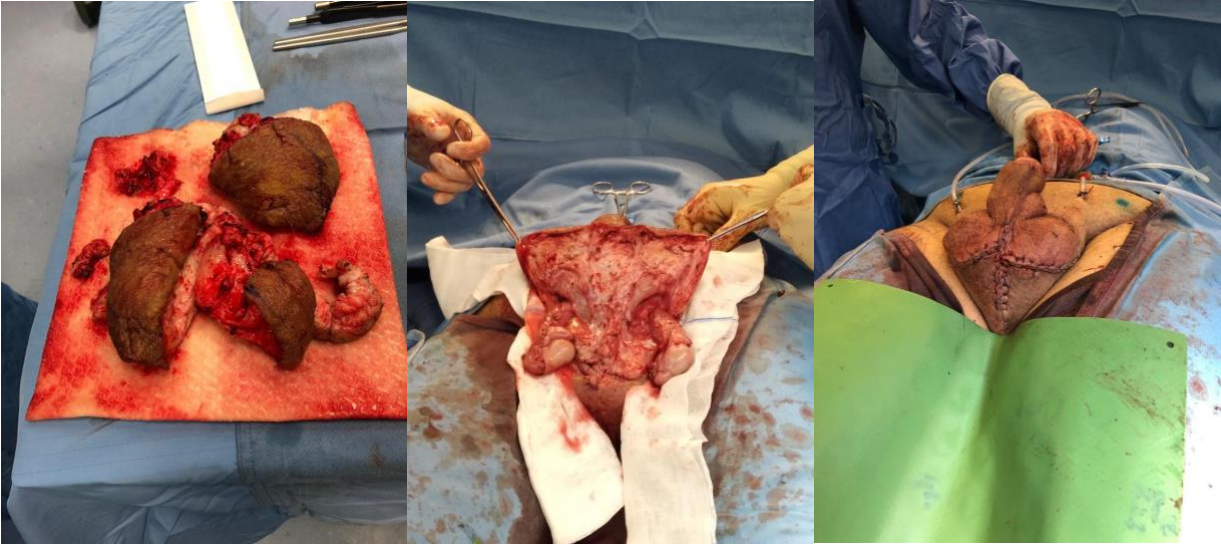**Supplementary Figure 12.** Secondary lymphedema results from multiple LVA + CDT.



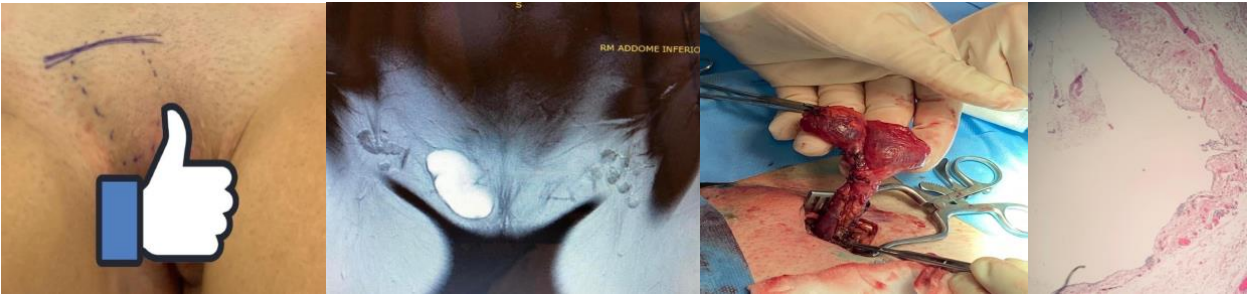**Supplementary Figure 13.** Primary lymphedema Mini-Invasive Fasciotomy (MIF) result.



**Supplementary Figure 14.** Plastic surgery of genitalia.



**Supplementary Figure 15.** Resective surgery.

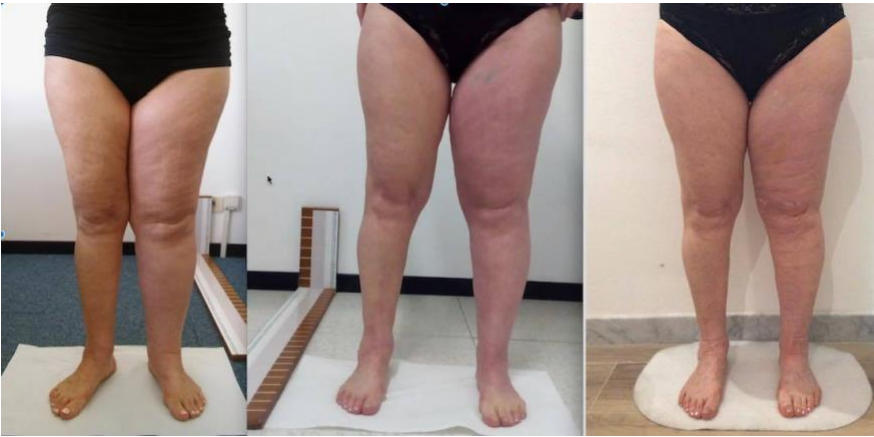


**Supplementary Figure 16.** Fibrolymphosuction technique with PDE.





**Supplementary Figure 17.** Fibrolymphosuction with Complex Decongestive Therapy (CDT).



**Supplementary Figure 18.** Monoclonal cell implantation in primary lymphedema with ulcer, with PDE.

