

CHIVA treatment for pelvic leak points in males

Jianping Deng, Xiaoyin Zhu, Xin Du, Lei Su, Yijian Gu, Qiang Zhang

Dr. Smile Medical Group, Shanghai, China

Abstract

Pelvic Leak Points (PLPs) are a possible cause of varicose veins of the lower limbs even in men, and can be easily overlooked without a thorough assessment, or leading to incorrect treatment with high recurrence rate. CHIVA is a minimally invasive approach by recorrecting hemodynamic changes, preserving the venous drainage network in lower extremity. In this study, we present two cases of male patients with symptomatic varicose veins related to PLPs that were successfully treated with the CHIVA method. With proper venous hemodynamic assessment

and strategic support, CHIVA could be a safe and effective way to treat PLPs in men.

Introduction

According to a national survey on the management of varicose veins in China, stripping and ablation were the most common treatments for varicose veins.¹ In a separate survey of UK practices, 9% of the 100 respondents who treat varicose veins do not recognize pelvic venous reflux, and 11% do not investigate or treat it. Coil embolization is used in 89% of treatments, and only 5% of respondents treat more than 10 patients annually, with just 14% using duplex ultrasound for follow-up.² Recurrences after stripping have been related to pelvic venous reflux, evaluated as 17%, but not specifically anatomically defined or treated.^{3,4} Thanks to Echo-Color-Doppler (ECD) investigation, different Pelvic Leak Points (PLPs), responsible for varicose veins in the lower limbs, have been detected and successfully treated using reflux ablation at the PLPs level.⁵⁻⁹ Accurate ultrasound hemodynamic assessment of each specific PLPs, as well as a specialized surgical technique, appear to be key to achieving satisfactory outcomes. The CHIVA method has been confirmed to be both safe and effective in treating this disorder.

Correspondence: Qiang Zhang, Sijun Surgical Clinic, Hongxin Medical Technology Center, No. 675 Minbei Road, Minhang District, Shanghai, China.
Tel. 021.60758889; 15000013163.
E-mail: qiang.zhang@drsmilehealth.com

Key words: CHIVA, varicose veins, Pelvic Leak Point (PLP), hemodynamics.

Contributions: all the authors made a substantive intellectual contribution. All the authors have read and approved the final version of the manuscript and agreed to be accountable for all aspects of the work.

Conflict of interest: the authors declare no potential conflict of interest.

Funding: none.

Ethics approval and consent to participate: no ethical committee approval was required for this case report by the Department, because this article does not contain any studies with human participants or animals. Informed consent was obtained from the patient included in this study.

Availability of data and materials: all data generated or analyzed during this study are included in this published article.

Received: 7 March 2023.
Accepted: 24 May 2023.
Early view: 22 August 2023.

©Copyright: the Author(s), 2023
License PAGEPress, Italy
Veins and Lymphatics 2023; 12:11271
doi:10.4081/vl.2023.11271

This work is licensed under a Creative Commons Attribution-NonCommercial 4.0 International License (CC BY-NC 4.0).

Publisher's note: all claims expressed in this article are solely those of the authors and do not necessarily represent those of their affiliated organizations, or those of the publisher, the editors and the reviewers. Any product that may be evaluated in this article or claim that may be made by its manufacturer is not guaranteed or endorsed by the publisher.

Case Reports

Diagnostic assessment

Two male patients presented to our vein center with aesthetic complaints and symptoms. The first patient (Case A) was 50 years old and had edema and pain in his right lower extremity, with visible varicose veins in the calf. He was evaluated for a C₃E_pA_sP_r CVD, which was first diagnosed twenty years before, and had a Venous Clinical Severity Score (VCSS) of 6. The ECD revealed an escape point from the Obturator Leak Point (OP) that drained into the saphenous vein arch, between the Terminal Valve (TV) And Pre-Terminal Valve (PTV), resulting in a type 4+2 shunt (Figure 1A).

The second patient (Case B) was 35 years old and was concerned with pain and edema of the right leg, and had right lower extremity varicose veins with a VCSS of 4. He was evaluated for a C₃E_pA_sP_r CVD. The ECD showed an Inguinal Leak Point (IP) reflux in the right superficial ring of the inguinal canal, resulting in a type 4+2 shunt (Figure 1B).

The hemodynamic measures for both cases are reported in Table 1.

Operative procedure

CHIVA is an office-based treatment for varicose veins performed under local anesthesia. The aim of the technique is to lower veins transmural pressure in the superficial, as well as deep venous system, preserve the venous drainage, avoiding wide

destruction of veins, and above all preserving the Great Saphenous Vein (GSV) for any need of vascular surgery. The mainstay of this approach is a correct hemodynamic evaluation. A complete Duplex scan is performed in a patient standing or in a lying position, if necessary, to correctly determine the source of pressure overloads. Hemodynamic manoeuvres are necessary to check the venous system: the hyperpressure Valsalva manoeuvre as well as the gravitational Parana manoeuvre, or the static gravitational squeezing manoeuvre. The deep ambulatory non-invasive measurement of the deep venous pressure^{10,11} is also necessary to highlight an increase in residual pressure.¹²⁻¹⁶ The strategy uses ligatures/disconnections targeted to interrupt escape points and fractionate hydrostatic pressure.

Case A

Various strategies can be employed, including ligation of the obturator point during saphenofemoral disconnection in the presence of associated terminal valve incompetence, or simple high ligation of the saphenous vein just below the superior collaterals of the junction. Given the satisfactory function of the terminal valve, we opted for the latter approach and disconnection of type 2 shunts (Figure 2A).

Case B

Based on the plexus that runs through the subcutaneous fascia and connects to the collaterals of the anterior, bypassing the Saphenous Femoral Junction (SFJ), we chose disconnection of the IP at the subcutaneous fascia in the inguinal region and disconnection of type 2 shunts (Figure 2B).

Local anesthesia with 5 mL of 1% lidocaine is administered to the incision site. Both cases had their N2-N3 reflux tributary of the leg ligated with a total of 3 small incisions made in each patient. The patients were discharged 30 minutes after the operation, and instructed to wear compressive stockings as per our postoperative routine. Clinical and ECD follow-up was scheduled at 1, 6, and 12 months.

Results

One month after treatment, both patients reported reduced symptoms and no major or minor complications were observed.

At the six-month follow-up visit, the patients reported no pain or heaviness and noted an improvement in their quality of life, with significant shrinkage of the varicose veins in the calf.

Table 1. Morphologic and hemodynamic measurements recorded both in case A and B.

	Case A	Case B
Escape points	OP	IP
TV	-	-
PTV	+	+
GSV diameter at mid thigh (mm)	8.6	7.5
Reflux time (s)	4	3
Peak velocity (cm/s)	45	40
Shunt type	4+2	4+2

GSV, Great Saphenous Vein; OP, Obturator Leak Point; IP, Inguinal Point; TV, Terminal Valve; PTV, Pre-terminal Valve; -, means competent; + Means incompetent. Both the PLPs show a systolic Valsalva reflux.

At the one-year follow-up, no systolic Valsalva recurrence at the IP in case B, no GSV systolic Valsalva in case A, where of course there is a reversed Valsalva negative drainage flow (CHIVA flow), and the diameter of the great saphenous vein was significantly smaller than before treatment. We took a complete photographic record before and after treatment (Figure 3, Figure 4).

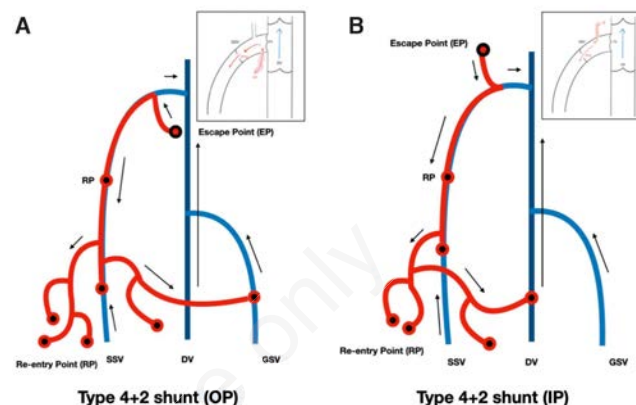


Figure 1. A) Type 4+2 shunt (OP): Pathological inversion of the physiological order of emptying from obturator point into GSV arch and trunk (N2), competent terminal valve, N2-N3 and N2-N4T additional escape points, reversed flow in N3 and N4T, re-entry points through N3 (N3-N1), and also through the N4T (N2-N4T-N2-N1; N4T-N1). A re-entry direct perforator is focused on the GSV (N2-N1). **B)** Type 4+2 shunt (IP): Pathological inversion of the physiological order of emptying from inguinal point through an arch tributary into GSV (N1-N3-N2), competent terminal valve, incompetent GSV preterminal valve, Parana diastolic reverse flow in the thigh GSV arch; two direct re-entry perforators on the GSV (N2-N1), and N2-N3 escape point below the knee: the incompetent tributary has its own RP (N3-N1). DV-N1, Deep Vein; GSV-N2, Great Saphenous Vein; SSV-N2, Small Saphenous Vein; EP, Escape Point; RP, Re-Entry Point; OP, Obturator Point; IP, Male Inguinal Point.

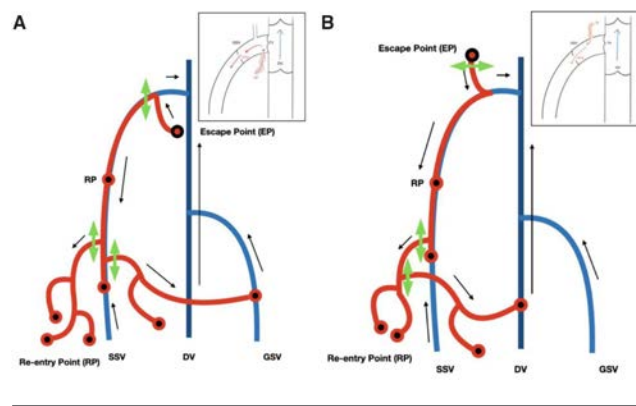


Figure 2. The green double arrows (↔) show the location of the incision for surgical treatment. Both cases had their N2-N3 reflux tributary of the leg ligated with a total of 3 small incisions made in each patient.

Discussion

PLPs have been found to contribute towards lower limb venous insufficiency with leg varicose veins. Varicose veins of pelvic origin in the male are not so rare, but some leakage points are infrequent. The Valsalva manoeuvre is mandatory for a correct PLP evaluation. Delfrate¹⁷ specified that pelvic leaks points in men can be of different types: i) medial muscular circumflex vein, anterior branch of the obturator vein, to be considered in the study of Valsalva from the terminal valve or saphenous arch; ii) anterior and posterior pampiniform plexuses with possible reflux into the inferior epigastric vein but also with a direct collector in the saphenous arch; iii) scrotal perforator veins fed indifferently from the homo- or contralateral pampiniform plexus; iv) penile root collector receiving reflux supply from the superficial dorsal penile vein, which in turn is in communication with the superficial or deep dorsal penile plexuses widely communicating between them.

Dabbs suggests investigating pelvic vein reflux and considering pelvic vein embolization in such cases.¹⁸ However, endovascular procedures can be more invasive and carry serious risks, such as the need for main venous access, radiation exposure, and

embolization-related complications.¹⁹ In contrast, the CHIVA strategy is a minimally-invasive surgical approach that aims to correct imbalances in the venous system while preserving the GSV and venous network, which is important for future bypass and venous drainage. In our study, two male patients with symptomatic right lower extremity varicose veins and aesthetic concerns underwent CHIVA treatment under local anesthesia, and follow-up data was consistent with existing literature.

In recent years, the CHIVA procedure has become the preferred method in our vein centers for treating varicose veins due to its advantages over traditional stripping or ablation treatments, including minimal invasiveness, reduced bleeding, less nerve damage, decreased postoperative pain, faster recovery, office-based treatment, lower recurrence rates, and most importantly, preservation of the saphenous veins. However, despite its demonstrated feasibility and safety in several studies, managing patients with lower extremity varicose veins caused by PLPs remains particularly challenging.^{5,6,8,14}

PLPs act as perforating veins that supply superficial veins with reflux. The primary points of leakage are the Perineal Point (PP), fed by the internal pudendal vein or deep penile venous, and the

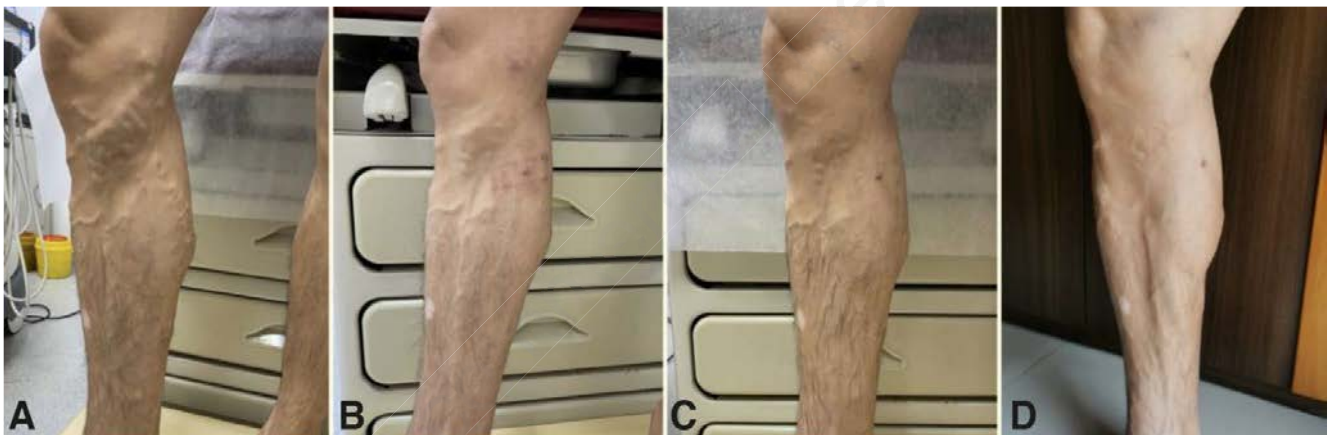

Figure 3. Case A. **A)** preoperative; **B)** 1 month postoperative; **C)** 4 month postoperative; **D)** 12 month postoperative.

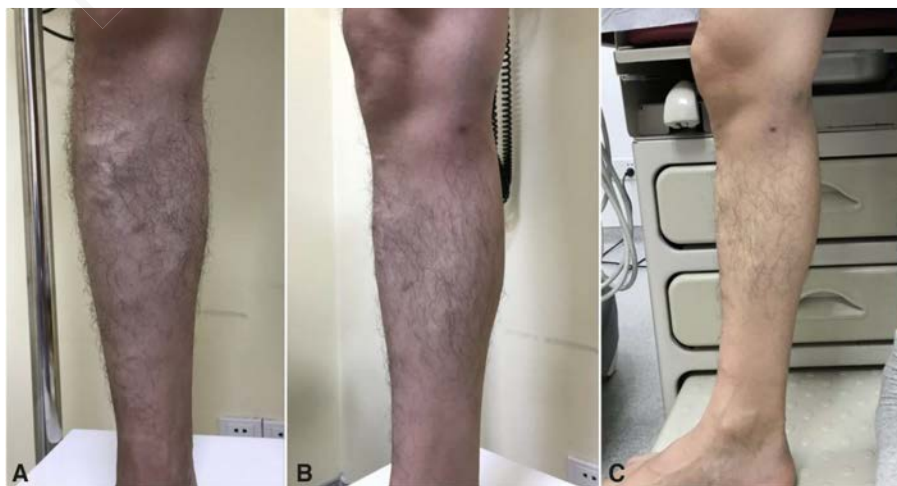


Figure 4. Case B. **A)** preoperative; **B)** 1 month postoperative; **C)** 12 months postoperative.

Inguinal Point (IP), fed by the round ligament vein of the uterus or spermatic veins. Most vulvar or perineal varices are fed by one of these two leakage points, which may extend to the superficial veins of the ipsilateral and/or contralateral lower extremity via anastomoses. Attempting neovalvulation, ligation, or embolization of the veins in this single, incontinent network is doomed to fail because it will be promptly circumvented, and pressure or leakage through IP and/or PP will persist. To treat lower extremity superficial venous reflux of pelvic origin effectively, the leak points must be ligated in the same way as a refluxing perforating vein or junction. Recurrence due to collateral flow will follow proximal or distal ligation without ligation of IP and/or PP. Franceschi *et al.* (2005) presented the treatment of lower extremity venous insufficiency in women caused by PLPs. The article described the definition and functional anatomy of PLPs, as well as its diagnostic and therapeutic strategies. The authors concluded that treatment of IP and PP location leads to simple and effective treatment of previously difficult-to-treat varicosities.⁷

In 2019, Delfrate *et al.* assessed 273 PLPs free of Pelvic Congestion Syndrome (PCS) with a minimum 12-month follow-up who underwent minimally-invasive procedures. Of the 273 PLPs treated, 267 (97.8%) did not show any PLPs reflux recurrence. PLPs reflux recurrence was detected in 6 (2.2%) PLPs. Three patients with PLPs reflux recurrence underwent a redo surgery (1.1%). In the remaining 3 patients with reflux redo, sclerotherapy was proposed. No cases of deep vein thrombosis, pulmonary thromboembolism, or death occurred. No bruises, subcutaneous inguinal or perineal hemorrhage, saphenous nerve neuralgia, wound infection, or superficial phlebitis occurred, with the exception of one inguinal bleeding that required immediate surgical exploration.²⁰ According to Rabe *et al.* (2015), embolization may not be necessary when treating leg varices of pelvic origin without PCS. Patients with vulvar or pudendal varicose veins have achieved good results with foam sclerotherapy or phlebectomy. However, if pelvic vein embolization is performed prior to PLPs reflux ablation, a residual PLPs reflux may persist, which requires additional superficial treatment. Therefore, pelvic varicose embolization should only be considered if PLPs reflux is resistant or if PLPs is associated with PCS.²¹ The effectiveness and safety of the CHIVA method in treating male PLPs have already been established. As our understanding of the disease and its treatment improves, an increasing number of patients will benefit. However, this also emphasizes the need for all physicians involved to possess advanced knowledge of sonography and hemodynamics.

Conclusions

We present two cases of successful treatment of male PLPs using the CHIVA strategy and surgical tactic planned thanks to the hemodynamic cartography. Accurate ultrasound assessment and a deeper understanding of venous hemodynamics appear to be crucial for achieving satisfactory outcomes. We find this individualized strategy to be highly beneficial for these patients, as it enables precise blockage of escape points, preservation of the GSV trunk, and a quick return to normal work and daily activities.

References

- Zhang M, Qiu T, Bu X, et al. A national survey on management of varicose veins in China. *J Vasc Surg Venous Lymphat Disord.* 2018;6:338-346.e1.
- Campbell B, Goodyear S, Franklin I, et al. Investigation and treatment of pelvic vein reflux associated with varicose veins: Current views and practice of 100 UK vascular specialists. *Phlebology.* 2020;35:56-61.
- Perrin MR, Labropoulos N, Leon LR Jr. Presentation of the patient with recurrent varices after surgery (REVAS). *J Vasc Surg.* 2006;43:327-34.
- Reich-Schupke S, Mendoza E, Dörler M, et al. Frequency of refluxive tributaries of the junction region in the groin in patients with recurrent varicose veins of the thigh. *Phlebologie.* 2016;45:149-53.
- Franceschi C. Anatomie fonctionnelle et diagnostic des points de fuites bulbo-clitoridiens chez la femme (Point C). *Journal des Maladies Vasculaires.* 2008;33:S42.
- Franceschi C, Bahnini A. Points de fuite pelviens viscéraux et varices des membres inférieurs. *Phlébologie.* 2004;57:37-42.
- Franceschi C, Bahnini A. Treatment of lower extremity venous insufficiency due to pelvic leak points in women. *Annals of Vascular Surgery.* 2005;19:284-8.
- Franceschi C, Zamboni P. Principles of venous hemodynamics. Nova Biomedical Books, Hauppauge, NY, USA. 2009. 198 pp.
- Ricci S. *Phlebology in 21st century. Veins and Lymphatics.* 2014;3:2268.
- Bartolo M, Nicosia PM, Antignani PL, et al. Noninvasive venous pressure measurements in different venous diseases. A new case collection. *Angiology.* 1983;34:717-23.
- Bartolo M, Antignani PL, Nicosia PM, et al. Noninvasive venous pressure measurement and its validation. *Int Angiol.* 1988;7:182-9.
- Franceschi C. Théorie et pratique de la cure conservatrice et hémodynamique de l'insuffisance veineuse en ambulatoire. Precy-sous-Thil, France, Editions de l'Armançon. 1988. 126 pp.
- Delfrate R. A new diagnostic approach to varicose veins: haemodynamic evaluation and treatment. Lorena Dioni Publisher, Trento, Italy. 2014. 177 pp.
- Zamboni P, Mendoza E, Giancesini S. Saphenous vein-sparing strategies in Chronic Venous Diseases. Springer, New York, USA. 2018. 291 pp.
- Mendoza E. Duplexsonographie der oberflächlichen Beinvenen. Springer, New York, USA. 360 pp.
- Faccini FP, Franceschi C, Ermini S. Hemodynamic Saphenous Preserving Procedures in Chronic Venous Disease: Can, and should, we preserve the saphenous vein? 2022. 323 pp.
- Delfrate R. Anatomy of pelvic leak points in the context of varicose veins. *Phlebologie.* 2021;50:42-50.
- Dabbs EB, Dos Santos SJ, Shiangoli I, et al. Pelvic venous reflux in males with varicose veins and recurrent varicose veins. *Phlebology.* 2018;33:382-7.
- Lopez AJ. Female pelvic vein embolization: indications, techniques, and outcomes. *Cardiovascular and Interventional Radiology.* 2015;38:806-20.
- Delfrate R, Bricchi M, Franceschi C. Minimally-invasive procedure for pelvic leak points in women. *Veins and Lymphatics.* 2019;8:7789.
- Rabe E, Pannier F. Embolization is not essential in the treatment of leg varices due to pelvic venous insufficiency. *Phlebology.* 2015;30:86-8.