

Indication of oxygen ozone therapy in the back pain of the sportsman with spongy edema type modic 1

Luca Morelli,¹⁻⁴ Simona Carla Bramani,¹ Angela Bassani,¹ Federico Carlo Morelli¹

¹Centro Polispecialistico Riabilitativo “San Fedele”, Longone al Segrino (CO); ²Master II livello Ossigeno Ozono Terapia, Università degli Studi Pavia; ³Associazione Medico Sportiva (AMS) Como, Italy; ⁴UCM United Campus of Malta HEI Foundation, Smart City Switzerland, Lugano, Switzerland

Abstract

Sport has contradictory effects on the lumbar spine, because while on the one hand it guarantees a strengthening of the “Muscular Core” of the trunk and increases its stability and elasticity, on the other hand it subjects the body to repeated stress and micro-trauma that would not occur in normal life and if prolonged over time cause damage to the structures, rather than a benefit. There are some conditions predisposing to lumbago in sportsmen and women that lead to the onset of the pathology determined mainly by functional overload of the spine. The rapid biomechanical movement produces a displacement of the pulpy nucleus which, if it fails to reposition itself, frequently causes micro lesions of the annulus with consequent degeneration of the disc in the medium term. In our study, only 20% of our athletes with back pain were found to have an anatomical cause, such as a herniated disc or vertebral stenosis, predominantly a discopathy related to Modic 1 type spongy edema. There is in fact a very strong correlation between the Modic type 1 sign, which is an indication of spongy tissue edema associated with trabecular fracture and back pain. One of the hypothetical causes of Modic type 1 bone edema has been attributed to the infection of bacteria such as: *Propionibacterium acnes*, *Corynebacterium propinquum* and *Staphylococcus*, demonstrating the effectiveness of Modic Antibiotic Spinal Therapy (MAST) on the symptom of pain in patients with chronic lumbago.

Correspondence: Luca Morelli, Centro Polispecialistico Riabilitativo “San Fedele”, Longone al Segrino (CO), Italy.
E-mail: lucamorelli@centrosanfedele.it

Key words: Lumbago in Sportman; Spongy Edema; Modic Type 1; Low Back Pain; Modic Antibiotic Spinal Therapy (MAST); Oxygen Ozone Therapy.

Conflict of interest: the authors declare no potential conflict of interests.

Received for publication: 12 October 2020.
Accepted for publication: 12 October 2020.

©Copyright: the Author(s), 2020
Licensee PAGEPress, Italy
Ozone Therapy 2020; 5:9396
doi:10.4081/ozone.2020.9396

This article is distributed under the terms of the Creative Commons Attribution Noncommercial License (by-nc 4.0) which permits any noncommercial use, distribution, and reproduction in any medium, provided the original author(s) and source are credited.

Mechanisms of action of oxygen-ozone in disco-radicular conflicts

Disc-radicular conflict occurs when the intervertebral disc changes shape, volume and seat.

On a clinical level, there is pain and motor limitation. On the pathophysiological level, a Mechanical Compression, Deformation and Stretching component and a Cellulo-mediated and Bio-humoral Inflammatory component with activation of cytokines involving the formation of algogenic substances such as prostaglandins, bradykinin, histamine, H⁺, glutamate, serotonin and ATP with specific action with pain receptors are identified.

The indications for oxygen-ozone therapy are essentially based on its biochemical properties with the restoration of the redox balance.

Due to the inflammatory and degenerative processes caused by discopathy, there is an increase in oxidative damage which tends to perpetuate due to an imbalance between excess ROS and consumption of antioxidants.

Ozone improves oxygenation, inhibits activation and leukocyte and platelet adhesion, inhibits activation of phospholipase A₂, cyclooxygenases and metalloproteases. Thanks to this intervention, the bio-humoral inflammatory response is inhibited.

The gaseous mixture reduces pain by helping to develop local micro-vascularization and remove inflammatory substances thanks to the link between ozone and unsaturated fatty acids; in addition, the bactericidal activity of ozone, due to the destruction of the capsule of the bacterium subjected to the oxidative process through SOD and the formation of Peroxides in the Respiratory Burst, plays a very important role in Modic Antibiotic Spinal Therapy (MAST).

Introduction

*Low back pain in athletes*¹ is not considered a disease but a symptom with multiple aetiological factors. The conditions that lead to the onset of a spinal overload pathology occur when: i) the athlete is not physically suitable for the required sports performance or is not adequately trained; ii) the biomechanics of the sporting gesture is not correct; iii) the work required by the sport practiced involves loads, tensions, resistance and movements that deviate from normal physiology; iv) morphological abnormalities of the spine, congenital or acquired, which alter the mechanical and functional balance.

Three types of functional overload can be distinguished: i)

fatigue overload: the continuous flexo-extension and torsional movements are the cause of repetitive micro-traumas that are often aggravated by inadequate recovery periods between one effort and the next; ii) super-load overload: occurs due to exhaustion of muscular strength, *i.e.* when, in order to bear the load, the bone, tendon and capsular structures of the spine are suddenly used, which can lead to structural failure; iii) involuntary overload: caused by a technical error, bad shape, fall or accidental collision.

Often the hasty athletic preparation, tiredness and competitive heat become the key element of a rachis accident. The rapid movement, in fact, produces a displacement of the pulpy nucleus which, if it is not able to reposition itself, frequently produces microlesions to the annulus with consequent degeneration of the disc in the medium period.

Many studies² have examined the relationship between the Modic sign, an alteration in the spongy tissue of the vertebral bodies and lumbago.

There is, in fact, a very strong correlation between back pain and the Modic type 1 sign, which is an indication of spongy tissue edema associated with fracture of the trabeculae, considering that these are alterations of the spongy tissue subjected to excessive stress due to the degeneration of the adjacent disc.

Purpose of the work

The aim of the work was to evaluate the causes of the lumbalgic symptom in our athletes and the effectiveness of paravertebral infiltrative treatment in relation to the mechanisms of action of oxygen-ozone therapy.³

Materials and Methods

Our study was conducted with the re-evaluation of the Nuclear Magnetic Resonance Imaging (NMRI) X-rays of the lumbar sacral tract of 60 clinical cases of sportsmen and women aged between 20 and 40 years, practicing different sports disciplines, which came to our observation for lumbago. The athletes had been subjected to conservative pharmacological treatment, excluding corticosteroid therapies for DOPING reasons, by different orthopaedic specialists or neurosurgeons and in physiotherapeutic treatment and physical therapy with little benefit.

Radiological images of 48 athletes showed mild protrusive discopathies or bulging associated with Modic 1 type spinal spongy edema; these patients reported fluctuating lumbago symptoms of predominantly nocturnal intensity that forced them to walk for pain relief.

Only 12 athletes showed, from the radiological images, an anatomical cause such as a herniated disc or vertebral stenosis and reported a constant and persistent lumbosciatic symptomatology that did not improve with rest.

Only 10 athletes, who showed slight protrusive discopathies associated with Modic 1 type spongy oedema, undergoing pharmacological treatment with NSAIDs and muscle relaxants with amoxicillin-clavulanate antibiotic therapy (500 mg / 125 mg) 3 times a day, according to the Modic Antibiotic Spinal Therapy (MAST) protocol, had greater symptomatological benefits.

In addition to their specific rehabilitation program, all patients were treated with infiltrations of 16-20 cc oxygen ozone⁴ at a concentration of 20 mg distributed in 4 lumbar paravertebral inoculation points once a week for the first 3-4 weeks with reduction of

algic symptoms and resumption of sports activity. The athletes underwent further paravertebral oxygen infiltration treatments with ozone oxygen at fortnightly or monthly maintenance intervals for a total of 6-10 sessions.

Results

All the athletes, after the first 4-6 infiltrative sessions with ozone oxygen, gradually resumed their sporting activity.

It was interesting to note that the 10 patients with Modic type 1 in antibiotic treatment responded positively to infiltrative oxygen ozone therapy from the very first sessions.

This asked us several questions about the aetiology of spongy edema and the mechanism of action of ozone oxygen in the treatment of Modic type 1.

Discussion

The hypothetical cause of Modic type 1 bone oedema has been identified in the infection of bacteria⁵ such as *Propionibacterium acnes*, *Corynebacterium propinquum* and *Staphylococcus*. These anaerobic commensal organisms of the skin and mouth are believed to have access to the disc during normal bacteremia due to neovascularization associated with disc degeneration or hernia.

Local inflammation in the adjacent bone can therefore be a side effect due to the production of cytokines and propionic acid, *i.e.* the infection is in the disc, Modic bone edema is a "side effect" that manifests itself in the bone.

In a pilot study,⁶ patients with chronic lumbago following herniated lumbar disc, associated with Modic type 1, were treated with amoxicillin-clavulanate.

The results provided further provisional support for the hypothesis that bacterial infection may play a role in low back pain with Modic type 1 alterations.

The aim of the study was to test the effectiveness of Antibiotic therapy in Modic type 1 bone edema of the spine (MAST) in patients with chronic lumbago and to identify a dose-response relationship.

Disc-radicular conflict occurs when the intervertebral disc changes shape, volume and seat.

On a clinical level, there is pain and motor limitation. On the physiopathological level, two components are identified: a mechanical, direct and indirect one; a cell-mediated and bio-humoral inflammatory component.

Mechanical Factors

The direct mechanical factors can be: Compression, Deformation and Stretching which lead to myelin sheath disruption with possible significant qualitative anomaly in the conduction of the electrical stimulus.

Indirect mechanical factors are related to vascularization which can be arterial ischemic with demyelination of nerve fibres and venous ischemic with venous stasis, edema, trophic disturbances especially in intraforaminal hernias.

The inflammatory nerve and perinervous component responsible for the pain symptom may be: i) Cell-mediated: responsible for cell activation phenomena: histiocytes, fibroblasts and chondrocytes in the processing of cytokines such as IL-1a, IL-6 and TNF α ; ii) Bio-humoral: Cytokine activation involves the formation of algogenic substances such as prostaglandins, bradykinin, histamine, H⁺, glutamate, serotonin, ATP with specific action with pain receptors.

Due to the inflammatory and degenerative processes caused by disc herniations there is an increase in oxidative damage which tends to perpetuate due to an imbalance between excess ROS and consumption of antioxidants.

Excessive levels of ROS are involved in the development and maintenance of hyperalgesia, allodynia.

Mechanisms of action of oxygen-ozone in discoradicular conflicts

Oxygen ozone therapy has been spreading over the last few years, showing good results in the treatment of many pathologies, particularly those of osteoarticular, vertebral, vascular and immune interest.

The indications for oxygen-ozone therapy are essentially based on its biochemical properties.^{7,8}

Ozone, a triatomic oxygen molecule, in a lipophilic environment, reacts with polyunsaturated fatty acids (PUFA) containing double bonds by adding the three oxygen atoms to the unsaturated bond, resulting in ozone formation.

This reaction is of great importance, in fact ozone causes the splitting of the double bonds with a reaction called Criegee ozonolysis leading to the formation of Reactive Oxygen Species (ROS) and Lipid Oxidation Products (LOPs) (Figure 1).

In an aqueous medium such as blood, ozonides are immediately transformed into stable hydroperoxides (ROS) such as Hydrogen Peroxide and into lipo-peroxides (LOP) such as 4-hydroxynonene (4-HNE): LOP which helps reactivate defence mechanisms.

Lipo-peroxides induce: i) Inhibition of the release of vasoconstrictor agents with release of vasodilating Reactive Nitrogen Species (RNS), such as NO; ii) Decrease in venous and capillary stasis; iii) Increase in nuclear related factor 2 (Nrf2), which increases the level of antioxidant enzymes and restoration of the redox balance; iv) Increase in Heme-oxygenase - 1 (HO-1), enzyme that protects at the endothelial level.

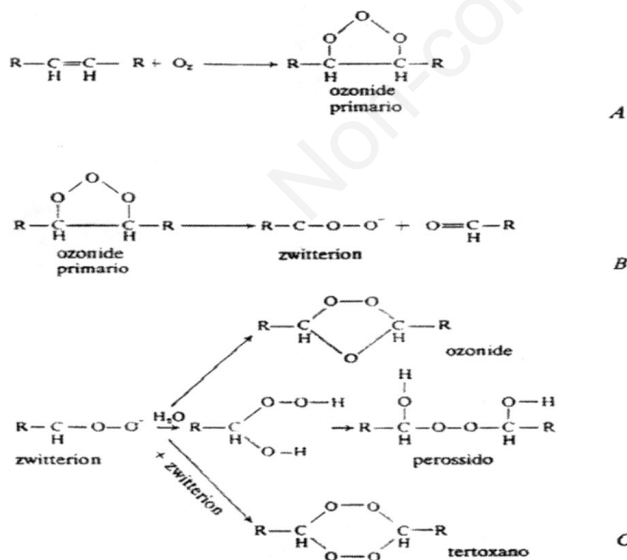


Figure 1. Critical Mechanism of ozonolysis of unsaturated organic substances (containing a double carbonic bond): A) Very unstable primary ozonide formation; B) the primary ozonide decomposes giving rise to zwitterion; C) Zwitterion, in the presence of water or other reactive solvents, gives rise to peroxides. (Marmo, "Farmacologia Generale e Speciale" 1991, p. 146).

Therefore, in moderate oxidative stress, oxygen-ozone plays a very important role in Infection, inflammation, endothelial regeneration, cell differentiation and healing with an immediate action that lasts over time (Figure 2).

Topical bactericidal action of oxygen ozone therapy

The bactericidal and fungicidal action depends on the direct contact between the ozone and the microorganisms and is due to the destruction of the capsule subjected to the gas oxidative process and peroxides.

Ozone, through the production of ROS, acts as an oxidizer in a similar way to what happens in leukocytes activated during phagocytosis. It is plausible to imagine that this increase is responsible for the bactericidal effect on anaerobic bacteria, considering that the latter are devoid of enzymes, such as superoxide dismutase (SOD), capable of neutralizing the oxidizing action of these free radicals.

Ozone could then act directly on the bacteria through its peroxides (OH-) attacking enzymes, DNA etc.

Ozone could act indirectly through phagocytosis with superoxide anion (O⁻²) during the cellular process of the Respiratory Burst (Figure 3).

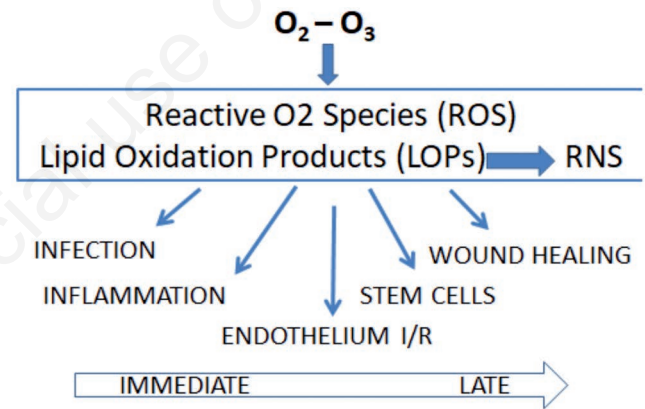


Figure 2. Ozone therapy and oxidative stress.

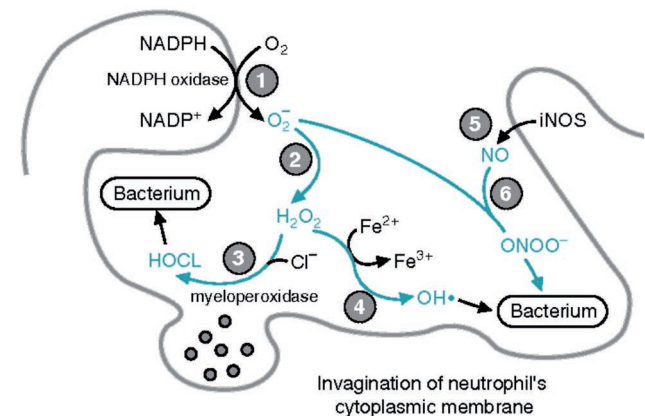


Figure 3. Topical bactericidal action of oxygen ozone therapy (Oxygen Toxicity and Free Radical Injury, Corpus ID: 7812013, available from: <https://www.semanticscholar.org/paper/Oxygen-Toxicity-and-Free-Radical-Injury/f8233012645a1a86ba41c0de28095869d1b81b92>).

The presence of H₂O₂ stimulates the formation of VEGF (Vascular Endothelial Growth Factor), which stimulates neoangiogenesis.

Ozone improves oxygenation, inhibits activation and leukocyte and platelet adhesion, inhibits activation of phospholipase A₂, cyclooxygenases and metalloproteases. This intervention will inhibit the bio-humoral inflammatory response. The gaseous mixture reduces pain by helping to develop local micro-vascularization and remove inflammatory substances thanks to the link between ozone and unsaturated fatty acids and erythrocyte peroxides.

Moreover, the bactericidal activity of ozone, due to the destruction of the capsule of the bacterium subjected to the oxidative process through SOD and the formation of Peroxides in the Respiratory Burst, plays a very important role in Modic Antibiotic Spinal Therapy (MAST).

Conclusions

Assuming that the etiopathogenic cause of Modic Type 1 spongy edema can hypothetically be traced back to a bacterial infection of the intervertebral disc, we have begun to assess the pathogenic causes of disc infection even in non-athletes who showed signs of Modic Type 1 and patients with discitis or spondylodiscitis sine causa. Some of these patients showed intestinal dysbiosis as the only likely cause of disc infection. These patients, in addition to topical paravertebral infiltrations with ozone oxygen, were treated according to the protocol of the Italian Scientific Society of Oxygen-Ozone Therapy (SIOOT) for the treatment of intestinal dysbiosis by means of hypodermic therapy with ozonized water and systemic rectal oxygen-ozone insufflation therapy.

From very early basic medical evidence, these patients resolved the lumbago symptoms very quickly, demonstrating that the systemic antibacterial effect of ozone can play an important role in disc infections.

We are currently conducting more in-depth research into the possible infectious causes of intestinal dysbiotic problems in

Modic type 1 lumbago patients and the specific therapeutic indications of ozone oxygen therapy.

References

1. Trompeter K, Fett D, Platen P. Prevalence of Back Pain in Sports. A Systematic Review of the Literature. *Sports Med* 2017;47:1183-1207.
2. Sairyo K, Nagamachi A. State-of-the-art management of low back pain in athletes: Instructional lecture. *J Orthop Sci* 2016;21:263-72.
3. Romeo A, Chierchia M, Baiano C, Ronca D. Anatomic substrate to pain originating in the disc and chronic low back pain posture damage resolution. *Ozone Ther* 2017;1:61-5.
4. Morelli L, Bramani SC, Cantaluppi M, et al. Comparison among different therapeutic techniques to treat low back pain: a monitored randomized study. *Ozone Ther* 2016;1:17-20.
5. Braten LCH, Rolfsen MP, Espeland A, et al. Efficacy of antibiotic treatment in patients with chronic low back pain and Modic changes (the AIM study): double blind, randomised, placebo controlled, multicentre trial. *BMJ* 2019;367:15654.
6. Albert HB, Sorensen JS, Christensen BS, Manniche C. Antibiotic treatment in patients with chronic low back pain and vertebral bone edema (Modic type 1 changes): a double-blind randomized clinical controlled trial of efficacy. *Eur Spine J* 2013;22:697-707.
7. Simonetti L, Raffi L, Cenni P, et al. Pharmacological Mechanisms Underlying Oxygen-Ozone Therapy for Herniated Disc. *Rivista Italiana di Ossigeno-Ozonoterapia* 2003;2:7-11.
8. Valdenassi L, Franzini M, Richelmi P, Bertè F. Ossigeno Ozono Terapia. In: Monticone M. (ed.). *Passaggio Lombosacrale e Sacro-iliache: progetto e programmi riabilitativi multidisciplinari*; Pavia, 22 novembre 2003. *Atti I Convegno della Sezione SIMFER di Riabilitazione ed Ambulatoriale*, Pavia: Dipartimento di Chirurgia dell'Università di Pavia, Dicembre 2003, pp. 116-23.