

# The use of intraoperative oxygen-ozone therapy to prevent capsular contracture in breast augmentation

Carlo Gasperoni,<sup>1,2</sup> Paolo Gasperoni,<sup>1</sup> M. Stella Malavenda<sup>3</sup>

<sup>1</sup>Private Surgery Practice, Rome, Italy; <sup>2</sup>Private Surgery Practice, Lugano, Switzerland; <sup>3</sup>“La Sapienza” University of Rome, Italy

## Abstract

Capsular contracture is the most frequent complication in breast augmentation. It has multifactorial aetiology but biofilm is suggested to have a central role in the capsular contracture pathogenesis. To sterilize the breast cavity and the implant after insertion we decided to use a mixture of oxygen and ozone, using ozone sterilizing properties with no subsequent contamination related to manipulation.

## Introduction

Capsular contracture (CC) is the most frequent complication in breast augmentation and in reconstruction with breast implants, increasing the number of reoperations. Various hypotheses have been formulated on the aetiology of CC.<sup>1-3</sup> The silicone oil oozing through the wall of implants and the prosthesis surface, from smooth to textured polyurethane coated, micro-textured and smooth again, was studied. Currently, it is implied the multifactorial aetiology of CC though an important role

attributed to biofilm formation and subclinical infections.<sup>4,5</sup> Biofilm can cause subclinical infections over time that may play an important role in the genesis of CC.<sup>6,7</sup> Many surgeons believe that it is important to prepare a sterile breast cavity that should remain sterile after introducing the breast implant. Using prosthesis with a smooth surface provide germs less nesting and No-touch techniques with Keller funnel have been developed,<sup>8</sup> to decrease the contact with the patient skin but are made partially ineffective by the manipulations of the surgeon in order to correctly position the implants inside the cavity. To guarantee greater sterility, some surgeons prefer peripheral access away from the nipple in order to avoid bacterial contamination of the lactiferous ducts during the manipulation of the mammary gland.<sup>9,10</sup> To minimize the bacterial load we sterilised the cavity with a sterilizing mixture of oxygen-ozone due to the bactericidal, fungicidal and virustatic properties of the ozone.<sup>11-15</sup> The treatment aims to reduce the incidence of capsular contracture in patients undergoing cosmetic breast augmentation.

## Materials and Methods

We used the Multiossigen Medical 99 IR Oxygen-Ozone therapy device with 25 mcg/cm<sup>3</sup> ozone concentration. The ozone does not interact with smooth or texturized silicone implants so it will not have negative consequences on the implants; to use the peri-areolar access we used the ozone to sterilize both the implant and the cavity after surgery. Nelaton catheter is left in the cavity after the prosthesis insertion; the gland is sutured with interrupted stitches and the skin with intradermal suture leaving the catheter in place. After completing the suture the catheter is insufflated with 100 cm<sup>3</sup> of oxygen-ozone mixture (Figure 1) and let in act for 5 minutes. Draining off excess gas through the catheter, remove the catheter and close the intradermal suture (Figure 2), thus avoiding any further risk of bacterial contamination.

## Results and Discussion

Oxygen-ozone therapy is successfully used for various purposes particularly for the treatment of infections due to its bactericidal, fungicidal and virustatic properties. We used it to interact with surfaces potentially contaminated by bacteria and that can generate CC through the formation of biofilm and consequent subclinical infections. Its harmlessness to human tissues and its important sterilizing action make it ideal for the sterilization of implanted prosthesis and implant cavity during surgery.

Correspondence: Paolo Gasperoni, Private Surgery Practice, Via Pieve di Cadore 30, 00135 Rome, Italy.  
E-mail: p.gasperoni@libero.it

Key words: Breast augmentation; Oxygen-ozone therapy; Capsular contracture; Risk factors.

Contributions: the authors contributed equally.

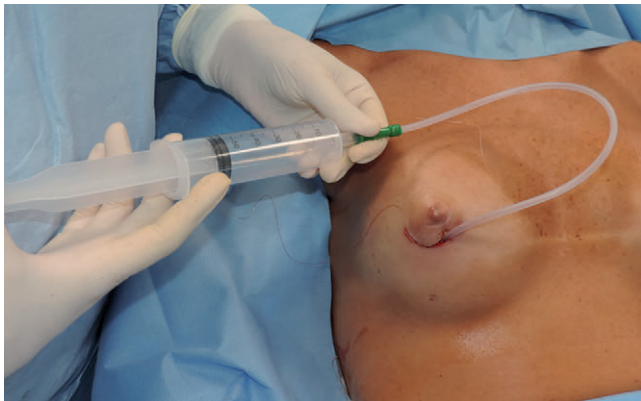
Conflict of interest: the authors declare no potential conflict of interest.

Funding: none.

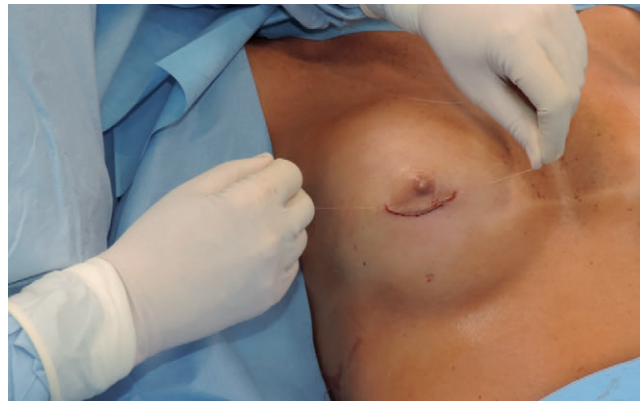Received for publication: 4 August 2018.  
Accepted for publication: 4 September 2018.

©Copyright C. Gasperoni et al., 2018  
Licensee PAGEPress, Italy  
Ozone Therapy 2018; 3:7740  
doi:10.4081/ozone.2018.7740

This article is distributed under the terms of the Creative Commons Attribution Noncommercial License (by-nc 4.0) which permits any noncommercial use, distribution, and reproduction in any medium, provided the original author(s) and source are credited.



**Figure 1.** Mixture of Oxygen-Ozone insufflate in the cavity through an indwelling catheter.



**Figure 2.** The catheter is extracted and the intradermal suture is pulled to close the incision.

## Conclusions

The ozone therapy using autohemotherapy could also be used, but we believe that local treatment with direct contact between the ozone and the prosthesis surface may be more appropriate to remove any risk of biofilm formation. As CC may appear after many years, long term follow-up will thus be necessary to know the real efficacy of this method, but we believe that it is able to reduce the bacterial load of the implant pocket reducing the risk of capsular contraction.

## References

- Bachour Y, Verweij SP, Gibbs S, et al. The aetiopathogenesis of capsular contracture: A systematic review of the literature. *J Plast Reconstr Aesthet Surg* 2018;71:307-17.
- Calobrace MB, Stevens WG, Capizzi PJ, et al. Risk factor analysis for capsular contracture: a 10-year Sientra study using round, smooth, and textured implants for breast augmentation. *Plast Reconstr Surg* 2018;141:20S-8S.
- Galdiero M, Larocca F, Iovene MR, et al. Microbial evaluation in capsular contracture of breast implants. *Plast Reconstr Surg* 2018;141:23-30.
- Jewell ML, Adams WP Jr. Betadine and breast implants. *Aesthet Surg J* 2018;38:623-6.
- Ajdic D, Zoghbi Y, Gerth D, et al. The relationship of bacterial biofilms and capsular contracture in breast implants. *Aesthet Surg J* 2016;36:297-309.
- Rieger UM, Raschke GF, Frei R, et al. Role of bacterial biofilms in patients after reconstructive and aesthetic breast implant surgery. *J Long Term Eff Med Implants* 2014;24:131-8.
- Tamboto H, Vickery K, Deva AK. Subclinical (biofilm) infection causes capsular contracture in a porcine model following augmentation mammoplasty. *Plast Reconstr Surg* 2010;126:835-42.
- Gowda AU, Chopra K, Brown EN, et al. Preventing breast implant contamination in breast reconstruction: a national survey of current practice. *Ann Plast Surg* 2017;78:153-6.
- Wixtrom RN, Stutman RL, Burke RM, et al. Risk of breast implant bacterial contamination from endogenous breast flora, prevention with nipple shields, and implications for biofilm formation. *Aesthet Surg J* 2012;32:956-63.
- Wiener TC. Relationship of incision choice to capsular contracture. *Aesthetic Plast Surg* 2008;32:303-6.
- Polydorou O, Halili A, Wittmer A, et al. The antibacterial effect of gas ozone after 2 months of in vitro evaluation. *Clin Oral Investig* 2011;16:545-50.
- Silva RA, Garotti JE, Silva RS, et al. Analysis of the bactericidal effect of ozone pneumoperitoneum. *Acta Cir Bras* 2009;24:124-7.
- Knight GM, McIntyre JM, Craig GG, et al. The inability of *Streptococcus mutans* and *Lactobacillus acidophilus* to form a biofilm in vitro on dentine pretreated with ozone. *Aust Dent J* 2008;53:349-53.
- Białoszewski D. The use of the intraoperative ozone - therapy as prophylaxis of infections in surgery of locomotor system with special regard to total hip plasty - a preliminary study. *Ortop Traumatol Rehabil* 2003;5:781-6.
- Huth KC, Quirling M, Lenzke S, et al. Effectiveness of ozone against periodontal pathogenic microorganisms. *Eur J Oral Sci* 2011;119:204-10.