

# Oxygen-ozone therapy effects on PaO<sub>2</sub> value in a diabetic patient suffering from chronic peripheral obliterative arteriopathy

Maria Laura Rosato,<sup>1</sup> Luca Schiaffino,<sup>2</sup> Margherita Luongo,<sup>2</sup> Luigi Mascolo,<sup>2</sup> Silvana Mattera,<sup>1</sup> Marco Mainini<sup>1</sup>

<sup>1</sup>Department of Anesthesiology, Intensive Care, Pain Medicine and Ozone Therapy; <sup>2</sup>Center of Oxygen-Ozone Therapy, Second University of Naples, Naples, Italy

## Abstract

We define chronic occlusive arterial disease of the extremities (COAD) as the aging process of the arterial vessel wall, characterized by the formation of atherosclerotic plaques.

Patients suffering from COAD often refer induced pain exercise. Previous studies described benefic effects of oxygen-ozone (O<sub>2</sub>-O<sub>3</sub>) therapy in treatment of COAD.

We describe a case of a 69-year old man, suffering from COAD, treated with O<sub>2</sub>-O<sub>3</sub> therapy. The aim of our report was to evaluate not only the effects of the oxygen-ozone therapy on the patient, but also the influence of this method on the arterial partial pressure of oxygen value.

## Introduction

We define chronic occlusive arterial disease of the extremities (COAD) the aging process of the arterial vessel wall, characterized by the formation of aggregates fibrocalcified (atherosclerotic plaques), which result in progressive narrowing of the arterial lumen, resulting in decreased downstream blood flow of the diseased segment; hence, an insufficient supply of oxygen (O<sub>2</sub>) occurs in perfused tissues from

the sick vase and this deficit is accentuated during exercise, for an increased O<sub>2</sub> demand from the muscle groups involved.

The mismatch between the demand and supply of O<sub>2</sub> to tissues determines the appearance of pain; this symptom is often an impediment to the continuation of physical activity.

We will now describe a case of COAD occluding the lower limbs treated with oxygen-ozone (O<sub>2</sub>-O<sub>3</sub>) therapy: this therapeutic technique is currently emerging in many fields of medicine, being used for the treatment of many diseases for its analgesic, anti-inflammatory, antiviral and immunomodulatory effects.

## Case Report

A 69-year old man, ex-smoker, diabetic, dyslipidemic, suffering from chronic obstructive pulmonary disease, arterial hypertension, chronic ischemic heart disease, chronic arterial disease in the lower limbs (Bypass surgery of the right iliac-popliteal in 2011) and obstructive sleep apnea syndrome, came to our observation for the persistence of pain (induced from walking) to the lower limbs, despite the conventional analgesic therapies. The patient also complained of numbness in both legs present even at rest.

It was decided, therefore, to proceed with oxygen-ozone therapy treatment.

Treatments were carried out at regular time intervals, every week, for a total of 28 doses and a total duration of the therapeutic cycle of 7 months.

There are different methods of administration of the mixture of O<sub>2</sub>-O<sub>3</sub>: in the case of our patient we used the grand autohemo infusion (GAEI); this technique consists in taking of 200 mL of venous blood that, once ozonized (30 µg/mL O<sub>2</sub>-O<sub>3</sub> mixed in 180 mL of blood), being reinfused into the patient's bloodstream.

Recall that the purpose of the study was to evaluate, in addition to effects of the oxygen-ozone therapy on the patient, also the influence of this method on the arterial partial pressure of oxygen (PaO<sub>2</sub>) value, detected by the arterial blood gas (ABG) analysis; hence, in each therapy session the patient was subjected to arterial blood gas analysis before and after the treatment.

## Discussion

The patient reported a noticeable improvement in symptoms as early as the third session. In fact, it was observed that, before the beginning of the therapeutic cycle (Time 0), the patient presented a marching autonomy evaluated by the Treadmill test, of less than 50 m,

Correspondence: Maria Laura Rosato and Marco Mainini, Department of Anesthesiology, Intensive Care, Pain Medicine and Ozone Therapy, Second University of Naples, via Luigi De Crecchio 6, 80130 Naples, Italy.  
E-mail: maria.laura.rosato@alice.it ; mamainini@yahoo.it

Key words: Chronic occlusive arterial disease; extremities; PaO<sub>2</sub>; ozone.

Conflict of interest: the authors declare no potential conflict of interest.

Received for publication: 16 February 2016.

Accepted for publication: 24 February 2016.

©Copyright M.L. Rosato et al., 2016

Licensee PAGEPress, Italy

Ozone Therapy 2016; 1:5843

doi:10.4081/ozone.2016.5843

This article is distributed under the terms of the Creative Commons Attribution Noncommercial License (by-nc 4.0) which permits any noncommercial use, distribution, and reproduction in any medium, provided the original author(s) and source are credited.

while at the conclusion of this cycle, the marching autonomy reached a value of 400 m.

During the arterial blood gas analysis, carried out before the first treatment, we noted the value of PaO<sub>2</sub>, equal to 65.2 mmHg; this value, taken immediately after the first session, increased to 68.4 mmHg.

We also observed, before the last treatment, a PaO<sub>2</sub> value of 69.9 mmHg; this parameter after the last therapy reached 73.9 mmHg (Figure 1).

It was also observed a significant reduction of lactate, which, from a value of 33 mg/dL noted before the beginning of the treatment, became normal at the end of treatment.

Previous studies shown the efficacy of O<sub>2</sub>-O<sub>3</sub> therapy, administered systemically through the GAEL, in treatment of patients suffering from COAD with venous leg ulcers. O<sub>2</sub>-O<sub>3</sub> therapy improves patient's quality life, increasing marching autonomy and promoting healing of skin ulcers.<sup>1-4</sup>

In 2008 a study described the positive response to the administration of blood ozonized on skin ulcers of patients suffering from vascular disease.<sup>5</sup>

Traditional therapies, as cilostazol and pentoxifylline besides having high costs also have numerous side effects, which affect the quality of life.<sup>1</sup>

The O<sub>2</sub>-O<sub>3</sub> therapy presents contained costs and rare side effects. In medical literature it has been described a case of death consequently to the O<sub>2</sub>-O<sub>3</sub> therapy, regarding a patient who underwent a GAEL and died from air embolism following a procedural mistake.<sup>7</sup>

For these reasons this therapeutic technique could represent a valid alternative to conventional therapies. Our study is coherent with the data present in the reports, which highlight the benefic effects of the O<sub>2</sub>-O<sub>3</sub> therapy during the treatment of patients affected by blood vessels diseases. This study also highlights a progressive and durable increase of the PaO<sub>2</sub> values, which could explain at least in part the positive response to the treatment. Such validation, however, needs further studies as it refers to only one clinical case.

## Conclusions

The oxygen-ozone therapy, administered systemically through the GAEL, determines a marked improvement in patient's life quality and a concomitant increase in PaO<sub>2</sub> value, detected by ABG analysis. This increase, already evident after the first treatment, became more and more significant with the continuation of the therapy, highlighting not

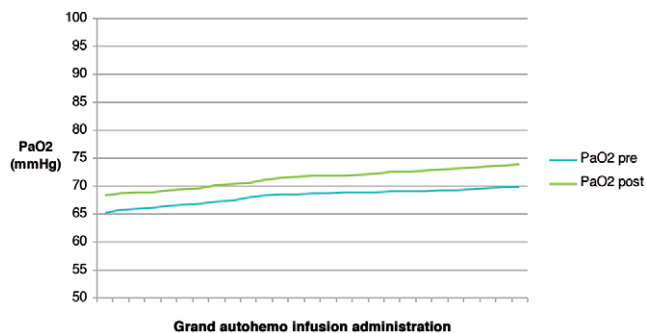


Figure 1. Pre- and post-treatment PaO<sub>2</sub> values during therapeutic cycle.

only a transient improvement after therapy, but also a progressive and lasting improvement of the basal values of PaO<sub>2</sub>.

## References

1. Luongo C, Luongo M, Cipollaro C, et al. Valutazione degli effetti della terapia sistemica con O<sub>2</sub>-O<sub>3</sub> nelle arteriopatie ostruttive croniche periferiche. Riv Ital Ossigeno-Ozonoter 2002;1:25-30.
2. Dupl a GR, Planas NG. La ozonoterapia en el tratamiento de las ulceras cronicas de las extremidades inferiores. Angiologia 1991;43:47-50.
3. Bocci V, Franzini M. L'ossigeno-ozonoterapia nelle malattie vascolari degli arti inferiori. Flebologia e linfologia. Torino: Utet; 1998.
4. Mattassi R, D'Angelo F, Bisetti P, et al. Terapia con O<sub>3</sub> per via parenterale nelle arteriopatie obliteranti periferiche: meccanismo biochimico e risultati clinici. Giorn Chirurgia 1987;8:109-11.
5. Borrelli E, Iabichella ML, Mosti G, Bocci V. Topical ozonated autohaemotherapy for the treatment of skin lesions. Proposal of a new method: concept, technique and initial clinical results. Int J Ozone Ther 2008;7:103-7.
6. Anderson JL, Halperin JL, Albert NM, et al. ACC/AHA Guidelines for the management of patients with peripheral arterial disease. Circulation 2013;127:1425-43.
7. Marchetti D. An unexpected death during oxygen-ozone therapy. Am J Forensic Med Pathol 2000;21:144-7.