

# Evaluation of vascular increase and density in tumors: study method for an integrative biological parameter applicable to carcinosarcomas of the uterus

E. Fulcheri<sup>1</sup>, I. Dellacasa<sup>2</sup>, C. Maganza<sup>2</sup>, G. Podestà<sup>1</sup>

<sup>1</sup>Dipartimento di Patologia (D.I.C.M.I.), Università di Genova

<sup>2</sup>Dipartimento di Ginecologia e Ostetricia, Università degli Studi di Genova

KEY WORDS: microvessel density, carcinosarcomas, prognostic factors, CD34

## Abstract

**The angiogenesis is one of the most important aspects in the tumoral increase. Some particularly aggressivetumors present a not sufficient angiogenesis, with consequent strong presence of necrosis; others present, instead, a relevant intratumoral neoangiogenesis, which grant a particularly fast evolution. The carcinosarcomi of the endometrium, among the tumors of the uterus, constitute a category of neoplasie with extremely low survivals (the global survival at 5 years is 25%) also in early stages. Various biological and histological factors predictive of the behavior of the neoplasia have been study in the course of the years and proposed for the diagnostic: none of these can be considered totally sure and easy to reproduce in order to integrate the staging of the tumor. Recently the study of the increase and the vascular density were pourposed. For this reason, it has been necessary to take in consideration a series of phenotypical markers of vases able to identify the new vascular structures, differentiating them from structural vases and typical vases of the organ. The choice of a marker to propose to the diagnostic must satisfy some criteria, as the easyavailable, the constant expression and the easy location inside conventional histology. They have been excluded all the phenotypical markers of the vases wall (too variable in relation to the tipology, the structure and the dimensions), while they have been taken in consideration the markers of the endothelium; among**

**these, excluding those indirect and related to the factors of the coagulation (factor VIII), the fenotipici markers of the endothelium have been tested selecting some of them (CD31, CD34). The study has been then integrated with the appraisal of the Vascular Endothelial Growth Factor (VEGF). The combination of the two systems of biological analysis allows to estimate, on sampled histological for the diagnostic routine, the pattern of vascular increase and therefore to define a prognostic factor more reliable.**

## Background

Carcinosarcomas of the endometrium, among uterine tumors, are neoplasms with extremely low survival rates, also in early stages (Gagne et al., 1989; Norris et al., 1966; Salazar et al., 1978; Dinh et al., 1989; King et al., 1980; Silverberg et al., 1990; Spanos et al., 1984; Bradley, 1995). Further, for proper tumor staging, there are no reliable and easy to reproduce biological and histological factors predictive of tumor behaviour. Carcinosarcomas are biphasic (McCluggage, 2002; Emoto et al., 1992) tumors, composed of a carcinomatous and a sarcomatous component, deriving from a common cellular clone (Emoto et al., 1993) of the Mullerian epithelium, the same tissue from which the genital tract originates. Mullerian epithelium can undergo significant differentiation. In the past, carcinosarcomas were thought to be two different tumors, called Homologous Malignant Mixed Mullerian Tumors and Heterologous Malignant Mixed Mullerian Tumors, depending on the most representative sarcomatous component and specific biological behaviour (Amant et al., 2004; Kounelis et al., 1998). Recently, these two types of tumors were identified as two different aspects of the same tumor. However, there are still doubts as to how to predict their behaviour. Whereas growth and spread pattern of the adenocarcinomatous component is similar to endometrial carcinomas, the sarcomatous component follows a growth and metastasization pattern similar to uterine sarcomas. It was thought that carcinosarcomas with a higher heterologous component

had a worse prognosis, than those in which the homologous component prevailed (Bitterman et al., 1990; Meiss et al., 1990; Gagne et al., 1989).

In the past few years, the following prognostic factors were considered: tumor stage, differentiation, volume, mitotic activity, which were all correlated with poor prognosis. Sometimes, lymph-vascular involvement has been pointed out as a diagnostic factor, as well as positive peritoneal washing. However, in the past few decades, no significant, evidence-based, biological or histological prognostic factor has been proposed.

Looking at the role of angiogenesis in some malignant tumors, like breast cancer, melanoma, or lung cancer, in which high microvessel density is correlated with a high chance of metastatic spread, we surmised that this could also be an important factor in carcinosarcoma growth, and that it could be an important prognostic factor. Two hypotheses were made:

- high microvessel density could be correlated with worse prognosis, because it corresponds to a more aggressive behaviour;
- high microvessel density could be a way to introduce an anti-tumoral therapy into the tumor.

Several phenotypical vessel markers able to identify the new vascular structures and to differentiate them from structural and typical vessels of the organ were therefore employed and tested. Then, all prognostic factors indicated in the literature were compared with the obtained results and with survival rates of women with carcinosarcoma.

## Methods

### Immunohistochemical Staining of CD34. 15

primary uterine carcinosarcomas were taken from the files of the Histopathology Service Pathological Anatomy of the University of Genoa from 2000 to 2005 (Table 1).

Cases	Stage	Age	Homologous Heterologous	Mitosis Epithelial - Mesenchymal	Lymphovascular space invasion	Follow-up	M.V.D.
NUMERO 1	pT3a;Mx;Nx G2/3	57	Homologous	26 / 8	Yes	NED 60 month	32
NUMERO 2	pT3a;M1;Nx G2	72	Homologous	10 / 17	No	DFD 18 month	10
NUMERO 3	pT1b;Mx;Nx G2	72	Heterologous	24 / 35	No	NED 60 month	12
NUMERO 4	pT1b;Mx;Nx G1	80	Homologous	11 / 2	Yes	NED 54 month	28
NUMERO 5	pT1b;Mx;Nx G3	55	Homologous	4 / 15	Yes	NED 52 month	34
NUMERO 6	Biopsie	73	Homologous	* / 21	***	***	12
NUMERO 7	pT3a;Mx;Nx G3	80	Homologous	31 / 20	Yes	LAF	14
NUMERO 8	pT3a;Mx;Nx G3	84	Heterologous	41 / 21	Yes	***	18
NUMERO 9	pT1b;Mx;Nx G2	52	Heterologous	36 / 10	No	NED 14 month	16
NUMERO 10	pT1b;Mx;Nx G3	69	Homologous	7 / 4	yes	NED 10 month	34
NUMERO 11	pT1a;Mx;Nx G2	59	Homologous	16 / 6	No	NED 10 month	12
NUMERO 12	pT1e;Mx;Nx G2	48	Homologous	11 / 10	yes	NED 4 month	195
NUMERO 13	pT1e;Mx;Nx G2	75	Homologous	10 / 13	No	NED 2 month	49
NUMERO 14	pT3a;Mx;Nx G3	59	Homologous	6 / 6	yes	NED 2 month	23
NUMERO 15	pT3b;Mx;Nx G3	70	Heterologous	8 / 20	yes	NED 1 month	179

All tissues were fixed in 10% buffered formalin and paraffin embedded. One selected tissue block with a well represented tumor with minimal foci of necrosis and haemorrhage was taken from each case.

Serial sections (3µm) were cut and stained with hematoxylin and eosin for histopathological evaluations or immunohistochemically analysed for microvessel density (MVD), which was measured in histologic sections, previous the identification of haematic vassels. Immunohistochemical analysis was performed using a mouse anti-CD34 monoclonal antibody (QBEnd/ 10) (BioGenex, Norris Canyon Road San Ramon, CA 94583 U.S.A.). CD34 is expressed on immature haematopoietic stem/progenitor cells, capillary endothelial cells, embryonic fibroblasts, and rare glial cells in nervous tissue. The QBEnd 10 antibody is a class II monoclonal antibody that recognizes a CD34 epitope, which is resistant to neuraminidase, and sensitive to glycoprotease and chymopapain.

Antigen retrieval was performed by microwave cooking the slides in citrate buffer (pH 6) and streptavidin-ABC complex technique with diamino-benzidine as chromogen was used to detect primary antibody.

We performed all immunohistochemical staining by an automatic stainer (Biogenex OptiMax Plus 2.0) and appropriate positive and negative controls were run simultaneously.

**Measuring MVD.** For MVD quantification (Gagne et al., 1989; Dinh et al., 1989; Silverberg et al., 1990), we separately examined the areas in which the epithelial or mesenchymal tissues are predominant in each tumor. Briefly, the stained slides were examined at low-power magnification (? 40 and ? 100 total magnification) to identify the areas of highest tumor neovascularization (so-called hot spots). In each section, the 5 most vascular areas were selected. Microvessels in a 200X field (20X objective and

10x ocular, Olympus BX-41 microscope, 0.74 mm 2 per field with field size measured with an ocular micrometer) in each of these 5 areas were then counted. The averages in the five 200x fields in each element of these tumors were calculated, which were thereafter referred to as Density Counts. Any brown-stained endothelial cell that was clearly separated from the adjacent

Tab 1

microvessels, tumor cells, or from other connective-tissue elements was considered as a single, countable microvessel. To better evaluate the vessel stained by anti-CD34 monoclonal antibody, Lucia Measurement on Mutech software was employed, Version 4.61, by which an exact photo of the stained vessel was obtained, also with a more enhanced red color.

## Results

The M.V.D. characterized 3 vascular pattern groups:  
*Group 1: Low MVD (from 10 to 20) (Fig. 1)*, out of 7 cases, 5

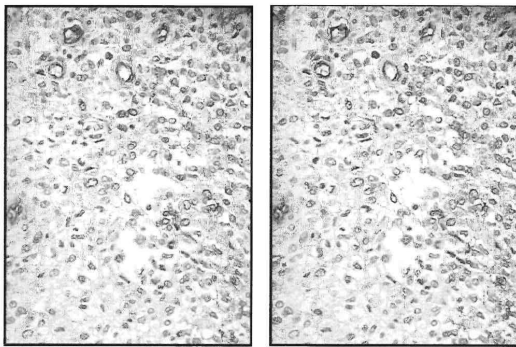


Fig. 1 - CD 34 stained Lucia Measurement. Low MVD: 10 microvessels

had a high mitotic count (more than 20 HPF), only 2 had lymph-vascular space invasion, and 4 were homologous;  
*Group 2: Intermediate MVD (from 20 to 50)*, 6 cases, none with a high mitotic count, only one case had no lymph-vascular invasion, they were all homologous;  
*Group 3: MVD 50 (Fig. 2)*, only 2 cases, none with a high mitotic count nor with lymph-vascular invasion, one was homologous and one heterologous.

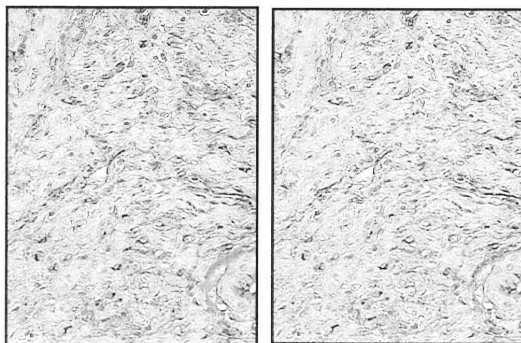


Fig. 2 - CD 34 stained Lucia Measurement. High MVD: 179 microvessels

## Discussion

The following remarks can be made:

-a reversed correlation is observed between **MVD** and **mitotic count**, as it appears in Group 1;

-there seems to be a correlation between **MVD** and **lymph-vascular space invasion**, because in Group 1 it was absent in 5 out of 7 cases, conversely, in Group 2, it was present in 5 out of 6 cases, and in Group 3 it was observed in both cases;  
- intermediate MVD is mostly associated with the **homologous** type of mesenchymal elements;  
-there seems to be no significant correlation between **MVD** and **staging**, nor with **survival**.

## Conclusions

In this study, no significant correlation was found between MVD and well accepted prognostic factors. Immunohistochemical study on MVD demonstrated that a tumor with a high **mitotic** count and low MVD is likely to be more aggressive: probably because the tumor is growing rapidly, it cannot build an adequate vascular pattern. Conversely, tumors seem to be less aggressive, if the intratumoral vascular support is more organized, which is probably due to slow neoplastic growth. Also, if tumors in Group 1 have no **lymph-vascular** space invasion, it could consistently be assumed that a low vascular tumor has a lower need to drain lymph and fluid build-up from the interstitium. On the other hand, a simultaneous lymphatic and vascular growth seems to make metastatic dissemination unlikely from an anatomic point of view. Intermediate MVD in tumors with homologous mesenchymal elements, unlike those with heterologous elements, could be interpreted as a less evolutive growth of the tumor, in accordance with a role of positive prognostic index of the homologous component, as maintained by some authors. This preliminary study needs to be extended to more representative cases series, and also to be correlated with post-surgical therapy and survival. This would allow for a better definition of MVD as a more reliable prognostic factor. In a prospective study-project, our research will be integrated with Vascular Endothelial Growth Factor (VEGF) appraisal. The combination of these two systems of biological analysis is likely to provide us with a better estimate of vascular growth and organization patterns.

## References

- Amant F, Vergote I. 2004. Importance of the endometrioid carcinoma subtype and sarcomatous component in uterine carcinosarcoma. *Gynecol Oncol* 93: 272-273.
- Bitterman E, Chun BK, Kurman RJ. 1990. The significance of epithelial differentiation in mixed mesodermal tumors of the uterus. *Am J Surg Pathol* 114: 317-328.
- Bradley J, Quade 1995. Pathology, cytogenetics and molecular biology of uterine leiomyomas and other smooth muscle lesions. *Curr Opin Obstet Gynecol* 7: 35-42.
- Dinh TV, Slavin RE, Bhagavan BS, et al. 1989. Mixed mullerian tumors of the uterus: A clinicopathologic study. *Obstet Gynecol* 74: 388-392.
- Emoto M, Iwasaki H, Kikuchi M, et al. 1992. Two cell lines established from mixed mullerian tumors of the uterus:

- Morphological, immunocytochemical and cytogenetic analyses. *Cancer* 69: 1759-1768.
- Emoto M, Iwasaki H, Shirakawa K. 1993. Characteristics of cloned cells of mullerian tumor of the human uterus. *Cancer* 71: 3065-3075.
- Gagne E, Tern B, Blondeau L, et al. 1989. Morphologic prognostic factors for malignant mixed mullerian tumors of the uterus: a clinicopathologic study of 58 cases. *Mod Pathol* 2: 433-438.
- King ME, Kramer EE. 1980. Malignant mixed mullerian tumors of the uterus: A study of 21 cases. *Cancer* 45: 188-190.
- Kounelis S, et al. 1998. Carcinosarcomas (malignant mixed mullerian tumors) of female genital tract: comparative molecular analysis of epithelial and mesenchymal components. *Hum Pathol* 29: 82-87.
- McCluggage VG. 2002. Malignant biphasic uterine tumors: carcinosarcomas or metaplastic carcinomas? *J Clin Pathol* 55: 321-325.
- Meiss JM, Lawrence WD. 1990. The immunohistochemical profiles of malignant mixed mullerian tumor: Overlap with endometrial adenocarcinoma. *Am J Clin Pathol* 94: 1-7.
- Norris HJ, Taylor HB. 1966. Mesenchymal tumors of the uterus: III. A clinical and pathologic study of 31 carcinosarcomas. *Cancer* 19: 1459-1465.
- Salazar OM, Bonfiglio TA, Patten SE et al. 1978. Uterine sarcomas: Natural history, treatment and prognosis. *Cancer* 42: 1152-1160.
- Silverberg SG, Major FJ, Blessing JA, et al. 1990. Carcinosarcoma (malignant mixed mesodermal tumor) of the uterus: A gynaecologic oncology group pathologic study of 203 cases. *Int J Gynecol Pathol* 9: 1-19.
- Spanos WJ, Wharton JT, Gomez L, et al. 1984. Malignant mixed mullerian tumors of the uterus. *Cancer* 53: 311-316.