

# Methodological approach to the 3D ultrasound reconstruction of human fetal thymus: a preliminary study

E. Olearo<sup>1</sup>, P. Gaglioti<sup>1</sup>, M. Oberto<sup>1</sup>, G.L. Panattoni<sup>2\*</sup>, T. Todros<sup>1</sup>

<sup>1</sup> Department of Gynecology and Obstetrics, University of Turin, Via Ventimiglia 3, 10126 Torino, Italy

<sup>2</sup> Department of Anatomy, Pharmacology and Forensic Medicine, University of Turin, Corso M. D'Azeglio 52, 10126 Torino, Italy

\* gianluigi.panattoni@unito.it

KEY WORDS: fetus, thymus, 3D morphology, ultrasound.

## Abstract

**The aim of this preliminary study is to propose a new methodological approach to the study of thymic morphology and volume in human fetus by ultrasound, using mathematical three-dimensional (3D) models and comparing them to the volumes obtained by Virtual Organ Computer-aided Analysis (VOCAL). Thymic volume and morphology of two fetuses at 21 and at 28 weeks of gestational age were reconstructed using VOCAL system and two different 3D models of fetal thymus were created with a CAD 3D software by an addition of geometrical solids: a conical model for the 21 weeks thymus; an elliptical model for the 28 weeks thymus. We believe that dysmorphism, volume and involution of fetal thymus should be investigated by this method during pregnancy. The relationship between the volumes obtained by VOCAL and those obtained with 3D models should be confirmed by further studies.**

## Introduction

Human fetal thymus has been studied only by bidimensional ultrasound (2DUS) techniques [1], in term of presence/absence in conotruncal anomalies [2], or as a predictor of fetal inflammatory response syndrome in intrauterine infections [3]. A universal method to estimate fetal thymic dimension is not available at the moment. In 2010, Li et al. [4] used for the first time Virtual Organ Computer-aided Analysis (VOCAL) to reconstruct thymic volume; no evaluation of thymic morphology in different gestational ages has ever been carried out. The aim of this study is to propose a new methodological approach to the study of thymic morphology and volume, using mathematical 3D models and comparing them to the volumes obtained by VOCAL.

## Materials and methods

Two uncomplicated pregnancies at 21 and at 28 weeks of gestational age (g.a.) were selected.

Fetal thymus was studied using a Voluson 730 Expert ultrasound machine (General Electric, Fairfield, CT, USA) equipped with a 5.0–7.0-MHz transabdominal probe and a combination of 3D/4D. The transverse diameter of thymus was assessed using 2D-US on an axial section of the fetal chest between the sternum and the great heart vessels. Three-dimensional ultrasound (3DUS) thymic volume was acquired immediately with the same probe. Volumes were captured through automatic sweep of the transducer, digitally stored and analyzed later. A constant setting of the machine was used; the sweep angle was set to ensure that a complete fetal thymus scan could be obtained; fast or very-fast acquisition were selected to reduce artefacts. Thymic volume was reconstructed using Virtual Organ Computer-aided Analysis (VOCAL) system, a volumetric calculation by rotation of an object about its axis. A 30° angle of rotation was selected. The 3D-US fetal thymic volume was measured by outlining the fetal thymus border of each plane manually. The built-in computer program calculated the fetal 3D-US thymic volume automatically from these individual images.

## 3D mathematical method

Two different 3D models of fetal thymus were created by a CAD 3D software. Both models were realized by addition of simple geometrical solids. The transverse diameter obtained by 2D-US was chosen as principal axis (A), other axes (cranio-caudal and antero-posterior) were obtained by the relations:  $B = \frac{3}{4}A$  and  $C = \frac{3}{4}A$ . For the conical model, the first solid was an elliptical cone with height  $h = \frac{3}{4}A$  and base constructed on the elliptical shape with  $\frac{A}{2}, \frac{C}{2}$ . Volume is defined as:  $V_1 = \frac{1}{3} \cdot \pi \cdot \frac{A}{2} \cdot \frac{C}{2} \cdot h = 0,147 \cdot A^3$ . Under the cone, a cylinder with elliptical base and height  $h' = \frac{1}{8}A$  was included. The corresponding volume was:  $V_2 = \pi \cdot \frac{A}{2} \cdot \frac{C}{2} \cdot h' = 0,0736 \cdot A^3$ . Eventually two spherical segments were included under the elliptical base with radius  $R = \frac{1}{4}A$  and height of the excluded segment  $h'' = \frac{1}{4}A$ . The corresponding volume was:  $V_3 = 2 \cdot \left[ \frac{4}{3} \cdot \pi \cdot R^3 - \pi \cdot \frac{h''^2}{3} \cdot (3 \cdot R - h'') \right] = 0,1104 \cdot A^3$ . The equation of the whole solid was:  $V_1 + V_2 + V_3 = 0,147 \cdot A^3 + 0,0736 \cdot A^3 + 0,1104 \cdot A^3 = 0,331 \cdot A^3$ . For the elliptical model, the first solid was a prolated spheroid with volume  $V_1 = \frac{1}{2} \cdot \left( \frac{4}{3} \cdot \pi \cdot \frac{A}{2} \cdot \frac{C}{2} \cdot \frac{B}{2} \right) = 0,147 \cdot A^3$ . Under

the cone, a cylinder with elliptical base and height  $h = \frac{1}{8}A$  was included. The corresponding volume was:  $V_2 = \pi \cdot \frac{A}{2} \cdot \frac{C}{2} \cdot h \approx 0,0736 \cdot A^3$ . Lastly, two spherical segments were included under the elliptical base with radius  $R = \frac{1}{4}A$  and height of excluded segment  $h = \frac{1}{8}A$ . The corresponding volume was:  $V_3 = 2 \cdot \left[ \frac{4}{3} \cdot \pi \cdot R^3 - \pi \frac{h^2}{3} (3 \cdot R - h) \right] \approx 0,1104 \cdot A^3$ . The equation of the whole solid was:  $V_1 + V_2 + V_3 \approx 0,147 \cdot A^3 + 0,0736 \cdot A^3 + 0,1104 \cdot A^3 = 0,331 \cdot A^3$

## Results

The transverse diameters measured by 2D-US were 2.09 cm and 2,45 cm at 21 and at 28 weeks g.a. respectively. The estimated volumes by VOCAL were 2,01 cm<sup>3</sup> and 5,89 cm<sup>3</sup> at 21 and at 28 weeks g.a. respectively (fig. 1).

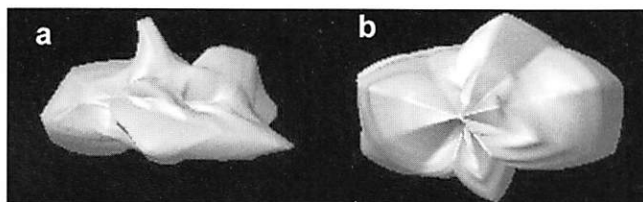


Figure 1. Fetal thymus reconstructed by VOCAL (frontal view): a) 21 weeks g.a.; b) 28 weeks g.a.

The estimated volumes with mathematical models were 3,0218 cm<sup>3</sup> and 4,8677 cm<sup>3</sup> at 21 and at 28 weeks g.a. respectively (fig. 2).

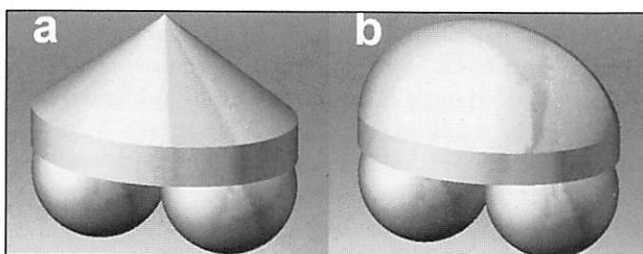


Figure 2. 3D mathematical reconstruction of fetal thymus: a) the conical model (21 weeks g.a.); b) the elliptical model (28 weeks g.a.).

## Discussion

We analyzed different 3D models and supposed that thymic morphology could be modified during gestation: the conical model seems to be appropriated for a 21 weeks thymus, while the elliptical model better represents a 28 weeks thymus. Although the two solid models are described by the same equation, they have different shape. We believe that dysmorphism as well as volume should be investigated in thymic anomalies and a geometrical model could be a useful tool to identify morphological and quantitative aspects of thymic involution during pregnancy. The relationships between the volumes obtained by VOCAL and those obtained by 3D models should be confirmed by further studies.

## References

- [1] Cho J.Y., Min J.Y., Lee Y.H., McCrindles B., Hornberger L.K., Yoo S.J. 2007. Diameter of normal fetal thymus on ultrasound. *Ultrasound Obst. Gyn.*, 29: 634-638.
- [2] Moran A.M., Colan S., Mayer J., van der Velde M. 1999. Echocardiographic identification of thymic hypoplasia in tetralogy of Fallot/tetralogy of pulmonary atresia. *Am. J. Cardiol.*, 84: 1268-1271.
- [3] El-Haeig D.O., Zidan A.A., El-Nerm M.M. 2008. The relationship between sonographic fetal thymus size and the components of FIRS in women with preterm premature rupture of membranes. *BJOG*, 115: 836-841.
- [4] Li L., Bahtiyar M.O., Buhimschi C.S., Zou L., Zhou Q., Copel J.A. 2010. Assessment of the fetal thymus by 2D and 3D ultrasound during normal human gestation and in fetuses with congenital heart defects. *Ultrasound Obst. Gyn.*, 30, in press.