

Immunohistochemical Evidence of HLA-G Expression in Extravillous Trophoblast Invading Decidual Tissues

V. Prada¹, Y. Musizzano¹, M. Mora¹, F. Puppo², E. Fulcheri¹

¹Department of Surgical and Morphological Sciences (DiCMI), Division of Anatomic Pathology, University of Genoa, Via De Toni 14, 16132 Genova, Italy

²Department of Internal Medicine (DiMI), University of Genoa, Viale Benedetto XV 6, 16132 Genova, Italy

KEYWORDS: Abortion, HLA-G, Extravillous Trophoblast

Abstract

HLA-G is a non classical HLA I gene product involved in the regulation of implantation and in the immune tolerance during pregnancy, by modulating maternal immune responses at the fetal-maternal interface. In pregnancies lacking immune tolerance and ending in miscarriage, the expression of HLA-G is very probably defective or altered. In order to contribute to further investigations about HLA-G expression in autoimmune miscarriages, we have tried to describe HLA-G immunohistochemical patterns of expression in a homogeneous cohort of normal first trimester choriodecidual specimens, in the three different extravillous trophoblast (EVT) populations ("cell islands", "cell columns", and intravascular EVT cells). We expected to demonstrate HLA-G reactivity to the tested antibody (MEMG101) in all three populations. All choriodecidual specimens were histologically and clinically reviewed to exclude any pathologic finding. Immunohistochemical identification of trophoblast cells in the selected specimens was performed via wellknown immunostains such as Cytokeratin 8/18 (CAM5.2) and NCL-PLp; anti-Ki67 was also used to point out proliferating EVT cells. Then, MEM-G101 was tested at various dilutions, with or without pretreatment, to find the optimal protocol. As expected, HLA-G specifically stained all three EVT populations, with decreasing reactivity from EVT cell islands to EVT cell columns or intravascular EVTs. The next step will be the investigation of HLA-G pattern of expression in autoimmune aborters.

Introduction

The Major Histocompatibility Complex (MHC) class I

includes two groups of genes. Group Ia genes encode the classical, highly polymorphic HLA-A, HLA-B and HLA-C antigens, which are expressed on the majority of nucleated cells, while group Ib encodes the less polymorphic, nonclassical, HLA-E, HLA-F and HLA-G antigens. HLA-G, first described in 1987 [1] is a nonclassical HLA class I (class Ib) gene product with limited polymorphism [2] and restricted tissue distribution [3], known to be involved in the regulation of implantation [4] and in the immune tolerance in human pregnancy [5-6]. At present, seven different isoforms of HLA-G are known: four of them HLA-G are known: four of them (HLA-G1, G2, G3 and G4) are membranebound, while the last three (HLA-G5, G6 and -G7) exist as soluble isoforms. Placental cells migrating into the maternal decidua synthesize both membrane and soluble HLA-G isoforms [7], which interact with inhibitory receptors on leukocytes such as ILT2 and ILT4 and, by inhibiting maternal immune responses to foreign (paternal) antigens, facilitate semiallogeneic pregnancy. Such HLA-G proteins act in different ways on immune cells: cytotoxic, CD8 positive, lymphocytes (CTL) are induced by HLA-G either to die or to decrease CD8 production; natural killer cells are immobilized, while mononuclear phagocytes increase production of antiinflammatory cytokines. At the fetal/maternal interface, all these effects of HLA-G modulate the maternal local immune responses in almost every pregnancy [8]. Conversely, in pregnancies lacking immune tolerance and ending in miscarriage, HLA-G expression very probably is defective or altered. The present study was conceived in the setting of a larger interdisciplinary research group which is investigating HLA-G expression in both human fluids and tissues from Systemic Lupus Erythematosus (SLE) patients. Histological assessment of HLA-G in choriodecidual specimens obtained from spontaneous miscarriages in women affected by autoimmune diseases, particularly SLE, could help in the management of future pregnancies in these women. Despite many studies have demonstrated HLA-G in amniotic fluid and maternal blood, only a few of them have investigated HLA-G expression by immunohistochemistry. Moreover, while HLA-G expression on extravillous trophoblast (EVT) is well established [9-10], more controversial results have demonstrated its expression in Hoffbauer mesenchymal cells [11-12], in some thymic medullary cells, in syncytiotrophoblast [13], in staminal cytotrophoblast, and in some endothelial or amniotic epithelial cells [14]. In order to provide a contribution to the

study of HLA-G expression in autoimmune miscarriages, we have tried to describe HLA-G expression patterns in a homogeneous cohort of normal first trimester choriodecidual specimens. Three different extravillous trophoblast populations are known: (1) the so-called "cell islands" covering the villi; (2) the scattered trophoblast cells migrating through the decidua ("cell columns") toward the decidual vessels, and (3) the intravascular trophoblast cells floating in the lumen of converted decidual arteries. We expected to demonstrate HLA-G reactivity in all three populations.

Materials and methods

Clinical and histological criteria of enrollment. We selected from the database of our Pathology Institute ten cases of abortion, in order to assess HLA-G reactivity in normal choriodecidual and, when present, embryofetal tissues. The four major criteria of enrollment (Tab. 1) were gestational age under 13 weeks, voluntary abortion, presence of basal and parietal decidua as well as chorionic plate, and the lack of pathological findings in the histopathological report. Hence, all spontaneous miscarriages, incomplete samples and specimens showing morphological signs of infection, abnormal karyotype or other potential causes of miscarriage were excluded. We collected clinical data of all women and histologically reviewed each slide, recording patient's history and histologic findings in Microsoft® Excel database. The main purpose of this review was to determinate the composition of any paraffin block: particularly, only those with basal decidua, including EVT cells, converted vessels and Nitabuch's stria, would have been submitted to immunohistochemistry. In addition, given the results obtained by some investigators (see above), HLA-G was tested in both fetal and neonatal paraffinembedded thymic tissue, lacking any clinical and histological evidence of thymic or immune disease.

Major criteria of enrollment
- gestational age < 13 weeks (90 days)
- voluntary abortion
- presence of basal and parietal deciduas and chorionic plate
- lack of pathological findings in the histopathological report

Table 1 - Clinical and histological criteria of enrollment

Immunohistochemistry. Curettage specimens from voluntary abortions were investigated by immunostaining for different antigens (Tab. 2), performed on serial sections (the first stained with hematoxylin and eosin (H&E), to compare their morphological expressions. Trophoblast cells were identified by using antiCytokeratin 8 and 18 (Clone 5D3, DiaPath, USA) and NCL-PLp (Novocastra, Newcastle upon Tyne, UK) antibodies. HLA-G reactivity was assessed using the antibody MEM-G/01 (Exbio, Prague, Czech Republic), which is known to recognize all HLA-G

isoforms. Finally, proliferating cells were marked with Confirm™ antiKi67 antibody (Ventana Medical Systems, Tucson, Arizona, USA).

Antibody	Source	Dilution	Target
Anti-Cytokeratin 8/18 (clone 5D3)	DiaPath, USA	1:100	Trophoblast cells
NCL-PLp	Novocastra UK	1:200	Trophoblast cells
MEM-G/01	Exbio CZ	1:100	EVT cells
Confirm™ anti-Ki67	Ventana Medical Systems USA	RTU	Proliferating cells

Table 2 - Employed antibodies and their tissue targets (RTU=ready-to-use).

Cytokeratin 8/18 Ab1 (Clone 5D3), also known as CAM5.2, recognizes all simple epithelia including thyroid, breast, gastrointestinal and respiratory glandular epithelia, as well as urogenital structures, including transitional epithelium. Keratin 8 belongs to the tipe B and Keratin 18 to the type A family of HMW cytokeratins. Clone 5D3 was obtained by using cytokeratins purified from breast cancer MFC7 cells as an immunogen, and its pattern of expression is cytoplasmic. Tissue was pretreated by digestion with trypsin (1 mg/ml PBS, pH 7.4) for 15 minutes at RT, and antibody was incubated at 1:100 dilution for 30 minutes at RT. [15-16] **MEM-G/01** reacts with denaturated HLA-G heavy chain of all isoforms. It is obtained using as an immunogen recombinant human HLA-G denaturated heavy chain; the purified antibody is conjugated with BiotinLC-NHS and the reagent is free of unconjugated biotin. It is stored (1 mg/ml) in phosphate buffered saline (PBS) with 15 mM sodium azide (approx. pH 7.4). As a starting point, we tried to find the appropriate working dilution and antigen retrieval technique. To find the optimal working dilution, **MEM-G/01** was tested at the suggested dilution (1:50) and at different decreasing concentrations (1:100, 1:500, 1:1000, 1:5000) on: A) choriodecidual specimen from elective cessation of pregnancy at 8 gestational weeks in a 36 year old woman; B) fetal thymus from stillbirth at 41 weeks, following intrauterine asphyxia; and C) neonatal thymus from a newborn decesead immediately after delivery due to gastrointestinal complications. Such dilutions of **MEM-G/01** were tested on each sample: 1) without antigen retrieval; 2) with EDTA and 98.1 °C bath; 3) with EDTA and heating in microwave oven for 3 minutes at 900W and for 13' at 360W. Results were compared and allowed us to choose the best pretreatment for further experimental investigations. Finally, **MEM-G/01** was tested at the reduced dilution of 1:100 on choriodecidual tissue taken from all ten cases. **NCL-PLp** is a rabbit polyclonal antibody specific for human placental lactogen (hPL), obtained from placental lactogen isolated from human placenta. It stains membrane and cytoplasm of syncytiotrophoblast cells and it is useful for the detection of

HPL in the placenta and in all cells showing trophoblastic differentiation. It was incubated for 60 minutes at 25°C at 1:200 dilution, performing standard ABC technique in a Benchmark automatic immunostainer. NCL-PLp is the trophoblaststaining antibody routinely used in our Institution in the setting of the investigation of early spontaneous abortions [17]. **Confirm™ anti-Ki67 (clone K2)** is a mouse monoclonal antibody which identifies the Ki67 nuclear antigen in proliferating cells and it is obtained by an immunogen recombinant protein corresponding to its Cterminal. As for cytokeratins 8/18 and for NCL-PLp, a Benchmark automatic immunostainer was used.

Results

Clinical records. The 10 women enrolled in the study were 19 to 42 years old (mean age: 31 yrs). Gestational age at the time of cessation of pregnancy ranged from 8 to 11 weeks (mean gestational age: 9 weeks). Seven women (70%) were facing their first pregnancy, while the other three had yet experienced term pregnancies (Fig. 1). Moreover, two of the latter (20% of all cases) had previously undergone elective cessation of pregnancy. None of them referred any spontaneous miscarriage, late fetal loss, stillbirth, threatened abortion, preterm or otherwise pathologic pregnancy.

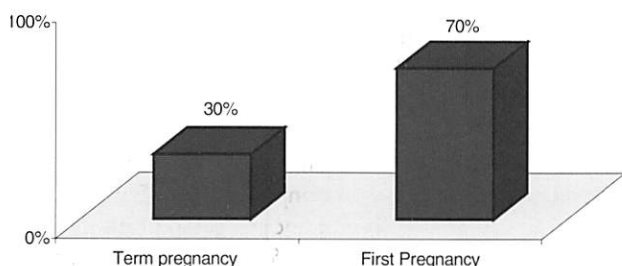


Fig. 1 - Obstetric history: main clinical records; 3 out of 10 women had yet experienced term pregnancy, and 2 among them had undergone voluntary abortion as well.

Specimen composition. Basal and parietal decidua and parts of chorionic plate were present in all cases, owing to the enrollment criteria, while only one case featured decidua capsularis as well. Embryo or fetus (depending on gestational age) were present in all cases; anyway, embryonic structures were seen only in 7 of the selected slides. Umbilical cord was found in 4 of 10 cases, and in two specimens amniotic membranes were seen as well. In three specimens decidua, chorionic disc, membranes and umbilical cord were present together (Fig. 2).

Histological features. All decidual specimens (Fig. 3) showed Arias-Stella reaction and hemorrhage (100% each), while aspecific/necrobiotic infiltrate was seen in 7 out of 10 cases (70%), thrombosis in 5 (50%), edema or necrosis in 3 (30%) and a true lymphoplasmocytic infiltrate in only 2 cases (20%).

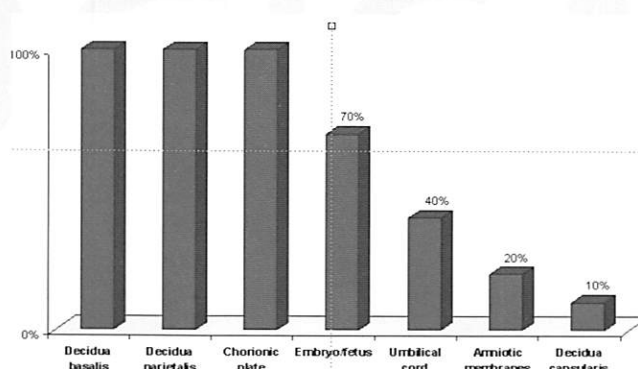


Fig. 2 - Histological composition of the specimens.

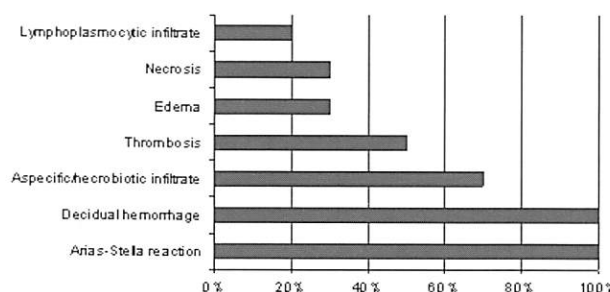


Fig. 3 - Histological features in the decidua.

Main findings in the chorionic plate (Fig. 4) were light fibrin deposition, seen in 7 cases (70%), villar edema in 3 cases (30%), waxy degeneration of the villi in 2 cases (20%), and collapsed vessels in one case (10%). All the above mentioned are non specific findings, usually seen in elective pregnancy termination owing to surgical procedures. No actual pathologic finding was seen in the embryo/fetus, umbilical cord or amniotic membranes, when present.

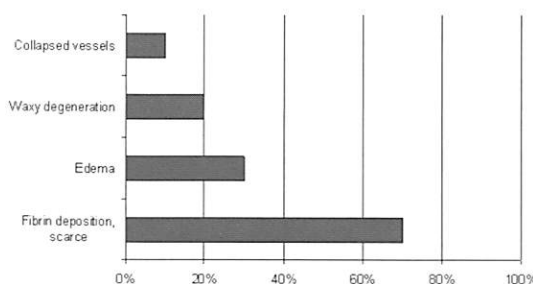


Fig. 4. Histological features in the chorionic plate.

Immunohistochemical findings. Preliminary tests on thymic and choriodecidual tissue demonstrated that the optimal procedure at 1:50 dilution was antigen retrieval by heating with EDTA and 98.1°C bath. Anyway, at the working dilution of 1:50, EVT showed strong positivity, but a weaker membrane reactivity was seen in some thymic structure as well, such as adipocytes, endothelial cells, and scattered medullary cell both in fetal and neonatal thymus. Once the dilution was increased to 1:100, immunohistochemical staining for HLA-G resulted more specific, since only EVT cells invading decidual tissues were stained, while the “false” reactivity of the thymic cells disappeared. At the higher dilutions tested, both EVT and thymus turned out negative. HLA-G was found to mark all

EVT populations: (1) HLA-G was expressed by cell islands covering the villi (Fig. 5b) previously identified in H&E (Fig. 5a), (2) by column cells migrating through the decidual tissues (Fig. 6a, 6b) and (3) by intravascular EVT (Fig. 7). To identify EVT elements on H&E slides (Fig. 8a), we marked them with CAM5.2 (Fig. 8b) and hPL (Fig. 8c) and we searched for proliferating cells with Ki67 (Fig. 8d).

Discussion

Our study was intended to contribute to a larger research project about the role of HLA-G and its expression in the setting of autoimmune diseases. Previous studies demonstrated HLA-G presence in body fluids, but the few investigating its immunohistochemical expression did not

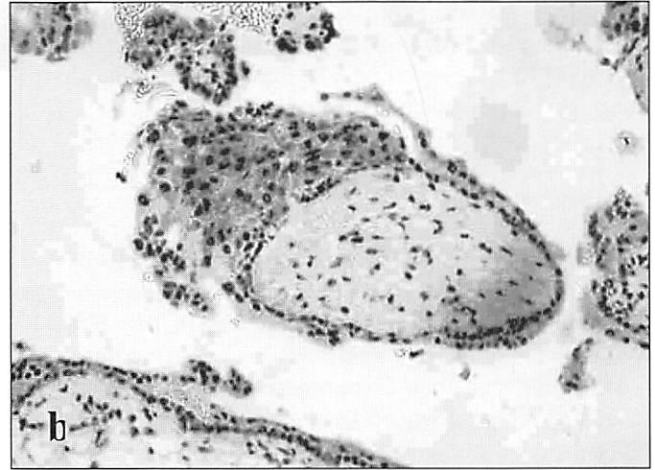
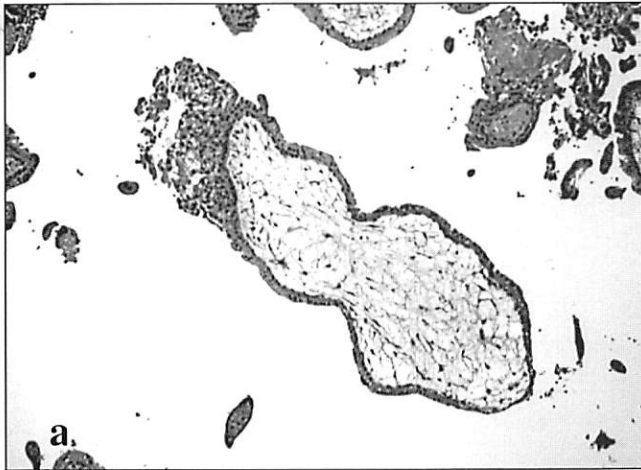
Fig. 5 - Cell island covering a villus: a) hematoxylin and eosin; b) immunostaining with MEM-G/01: the cell island expresses HLA-G.

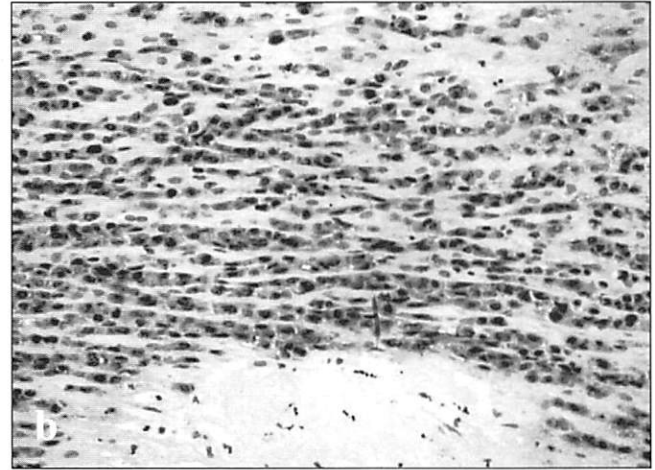
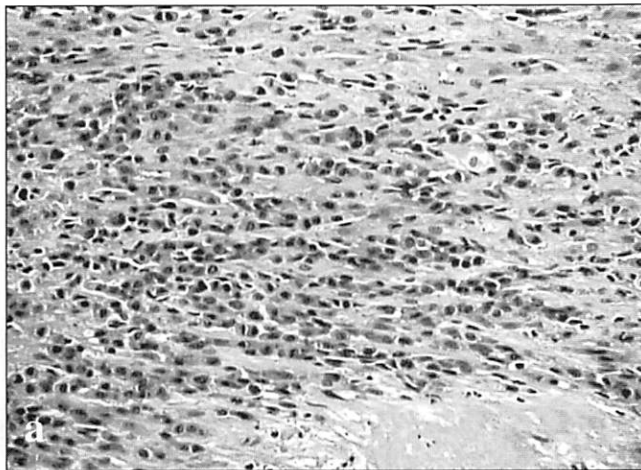


Fig. 6 - Cell columns of EVT in the decidua: a) hematoxylin and eosin; b) immunostaining with MEM-G/01: the cell columns express HLA-G.

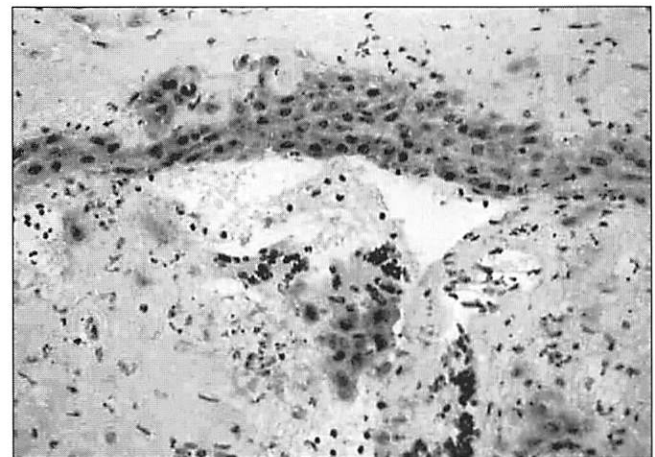
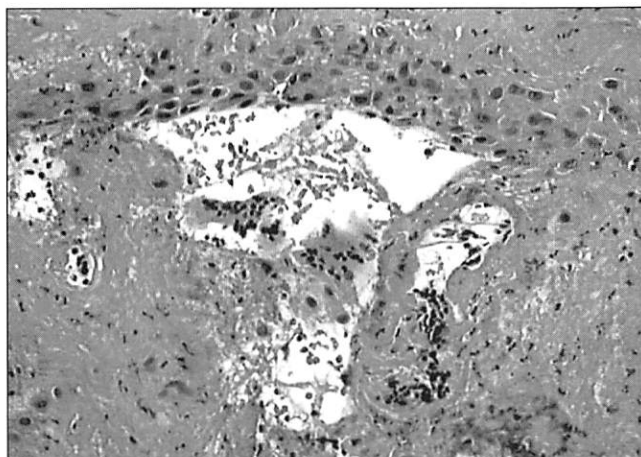


Fig. 7 - Trophoblast cells invading maternal vessels (immunostaining with MEM-G/01): EVT cells invading the vascular lumen express HLA-G.

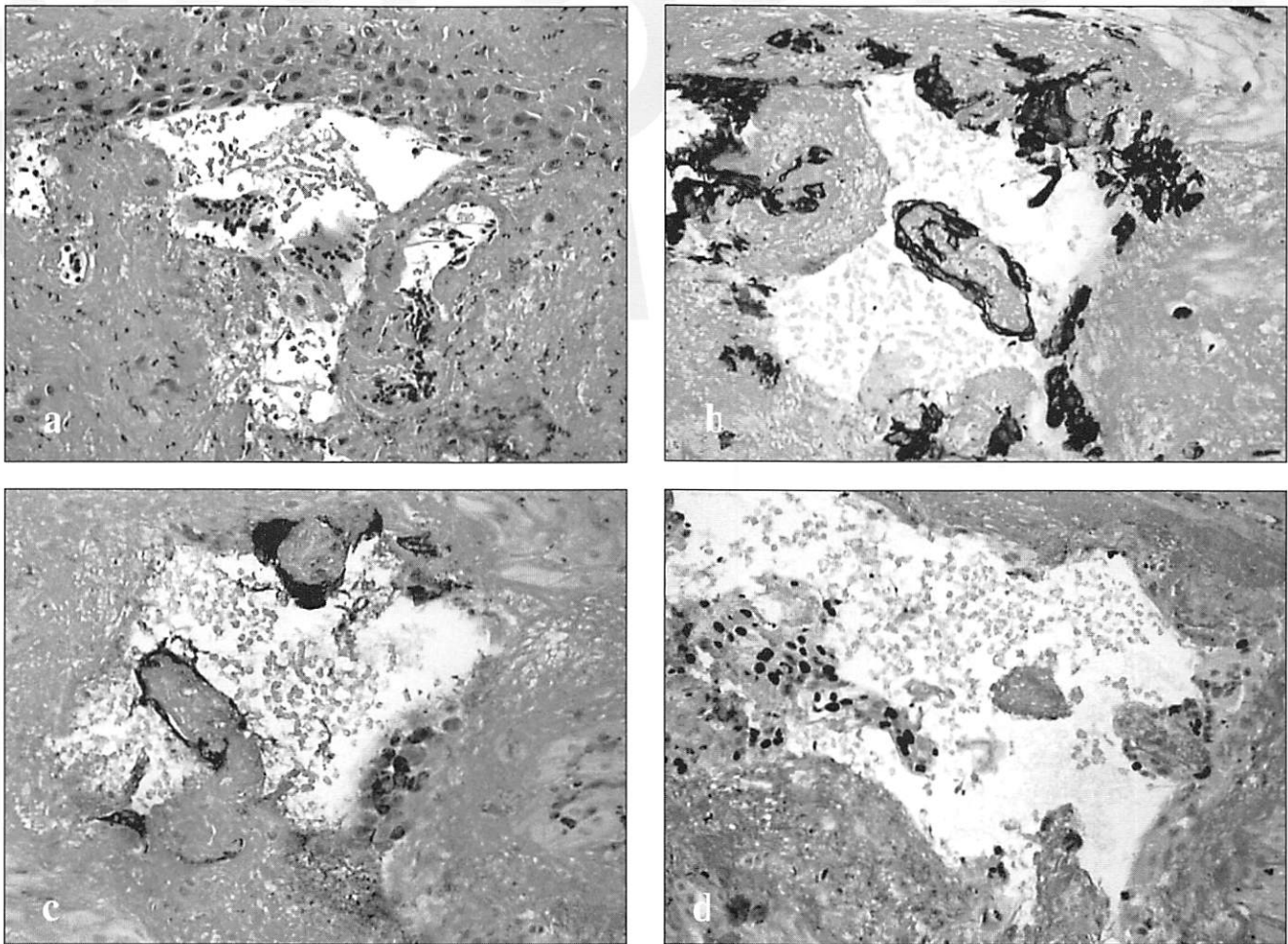


Fig. 8 - Trophoblast cells invading maternal vessels (serial sections): a) hematoxylin and eosin; b) immunostaining with CAM5.2: cytokeratins are expressed by EVT; c) immunostaining with NCL-Plp identifies EVT; d) immunostaining with Ki67 marks proliferating EVT cells.

accurately differentiate between the three populations of EVT. Moreover, expression in such nontrophoblast cells such as Hoffbauer mesenchymal cells, some medullary cells of the thymus and some endothelial or epithelial cells needed further investigation. We found that the latter are nonspecific stainings, while, at the optimal dilution of 1:100 applied to normal first trimester choriodecidual specimens, MEM-G/01 specifically stains all three EVT populations, as we expected. We also demonstrated a decreasing HLA-G reactivity from EVT cell island to EVT cell columns or intravascular EVT; anyway, in the latter immunostaining remain easily detectable and specific. In conclusion, we have tried to provide a background for further investigations in the setting of immunohistochemical characterization of curettage specimens from autoimmune patients. The next step will consist in the immunohistochemical investigation of the HLA-G pattern of expression in autoimmune aborters.

References

- [1] Geraghty D.E., Koller B.H., Orr H.T. 1987. A human major histocompatibility complex class I gene that encodes a protein with a shortened cytoplasmic segment. *P. Natl. Acad. Sci. USA.*, 84 (24): 9145-9149.
- [2] Ober C., Aldrich C.L. 1997. HLA-G polymorphisms: neutral evolution or novel function? *J. Reprod. Immunol.*, 36 (1-2): 1-21.
- [3] Hutter H., Hammer A., Blaschitz A., Hartmann M., Ebbesen P., Dohr G., Ziegler A., Uchanska-Ziegler B. 1996. Expression of HLA class I molecules in human first trimester and term placenta trophoblast. *Cell. Tissue Res.*, 286 (3): 439-447.
- [4] Loke Y.W., King A., Burrows T.D. 1995. Decidua in human implantation. *Hum. Reprod.*, 10 (Suppl.2): 14-21.
- [5] Rouas-Freiss N., Khalil-Daher I., Marchal-Bras Goncalves R., Menier C., Dausset J., Carosella E.D. 1999. Role of HLA-G in maternal-fetal immune tolerance. *Transplant. Proc.*, 31 (12): 724-725.
- [6] Rouas-Freiss N., Khalil-Daher I., Riteau B., Menier C., Paul P., Dausset J., Carosella E.D. 1999. The immunotolerance role of HLA-G. *Semin. Cancer Biol.*, 9 (1): 312.
- [7] Hunt J.S., Petroff M.G., McIntire R.H., Ober C. 2005. HLA-G and immune tolerance in pregnancy. *FASEB J.*, 19 (7): 681-693.
- [8] Apps R., Gardner L., Sharkey A.M., Holmes N., Moffett A. 2007. A homodimeric complex of HLA-G on normal trophoblast cells modulates antigen-presenting cells via LILRB1. *Eur. J. Immunol.*, 37 (7): 1924-1937.
- [9] Blaschitz A., Hutter H., Leitner V., Pilz S., Wintersteiger R., Dohr G., Sedlmayr P. 2000. Reaction patterns of monoclonal antibodies to HLA-G in human tissues and on cell lines: a comparative study. *Hum. Immunol.*, 61 (11): 1074-1085.
- [10] Blaschitz A., Juch H., Volz A., Hutter H., Daxboeck C., Desoye G., Dohr G. 2005. The soluble pool of HLA-G produced by

- human trophoblasts does not include detectable levels of the intron 4-containing HLA-G5 and HLA-G6 isoforms. *Mol. Hum. Reprod.*, 11 (10): 699-710.
- [11] Mallet V., Blaschitz A., Crisa L., Schmitt C., Fournel S., King A., Loke Y.W., Dohr G., Le Bouteiller P. 1999. HLA-G in the human thymus: a subpopulation of medullary epithelial but not CD83(+) dendritic cells expresses HLA-G as a membrane-bound and soluble protein. *Int. Immunol.*, 11 (6): 889-898.
- [12] Fournel S., Huc X., Aguerre-Girr M., Solier C., Legros M., Praud-Brethenou C., Moussa M., Chaouat G., Berrebi A., Bensussan A., Lenfant F., Le Bouteiller P. 2000. Comparative reactivity of different HLA-G monoclonal antibodies to soluble HLA-G molecules. *Tissue Antigens*, 55 (6): 510-518.
- [13] Hunt J.S. 2006. Stranger in a strange land. *Immunol. Rev.*, 213: 36-47.
- [14] Puppo F., Costa M., Contini P., Brenci S., Cevasco E., Ghio M., Norelli R., Bensussan A., Capitanio G.L., Indiveri F. 1999. Determination of soluble HLA-G and HLA-A, -B, and -C molecules in pregnancy. *Transplant. Proc.*, 31 (4): 1841-1843.
- [15] Angus B., Purvis J., Stock D., Westley B.R., Samson A.C., Routledge E.G., Carpenter F.H., Horne C.H. 1987. NCL-5D3: a new monoclonal antibody recognizing low molecular weight cytokeratins effective for immunohistochemistry using fixed paraffin-embedded tissue. *J. Pathol.*, 153 (4): 377-384.
- [16] Angus B., Kiberu S., Purvis J., Wilkinson L., Horne C.H. 1988. Cytokeratins in cervical dysplasia and neoplasia: a comparative study of immunohistochemical staining using monoclonal antibodies NCL-5D3, CAM 5.2, and PKK1. *J. Pathol.*, 155 (1): 71-75.
- [17] Musizzano Y., Fulcheri E. 2007. Peculiar features of intermediate trophoblast proliferation in decidual vascular walls in autoimmune diseases and luteal defects. *Exp. Biol. Rep.*, 1 (1): 65-76.