

# Sardinian Museum of Anthropology and Ethnography: A Case of Ankylosing Spondylitis from Sardinia

M. Sarigu<sup>1</sup>, G.U. Floris<sup>1</sup>, R. Floris<sup>1</sup>

<sup>1</sup> Dipartimento di Scienze della Vita e dell'Ambiente Università degli Studi di Cagliari Cittadella Universitaria SS 554, Km 4,500 Monserrato (CA). E-mail: marcosarigu@tiscali.it

**KEY WORDS:** Su Sercone, paleopathology, ankylosing spondylitis, osteoarcheology.

## Introduction

The specimen presented here is part of the remains of several individuals recovered after a random discovery in 1974-1975 in the collapsed natural dome near Su Sercone (Orgosolo, NU, central Sardinia, IT) by G. Cosseddu, then professor at the Institute of Anthropology, Cagliari University. It is a spinal cord fully fused, with bone production involving also a large part of the pelvis, which can be diagnosed as ankylosing spondylitis. Only recently it was handled and prepared to allow its study.

## Materials and Methods

Methods were those typically applied on macroscopic traits, both metric and non-metric (as in Martin and Saller, 1957-62). Identification of pathology follows Ortner and Putschar (1985) and Aufderhide and Martin (1998), whereas stress markers were detected after Mariotti *et al.* (2007).

A macroscopic examination has been carried out, with the analysis of the paleopathological conditions of the remain, and subsequently an X-ray completed the analysis. The specimen has then been investigated through x-rays at the "Laboratorio di Diagnostica per immagini" at the University's Policlinico, in Monserrato. The specimen belongs to an individual of unknown age, since the diagnostic bone surfaces were altered by its pathological condition.

In 1992 it was submitted for <sup>14</sup>C analysis for absolute dating (Beta Analytics Inc., Miami, Florida). Its overall length is 31 cm. Ankylosis affects the whole spinal cord, including the sacroiliac joints, presumably also in the left side. There is rib ossification in T1 and T2 (Fig. 1) and a remarkable scoliosis. Evident signs of an ante mortem fracture that leads to hypothesize fusion also in the atlas-occipital articulation. The ribs too were probably wholly fused to the rachis.

## Results

The individual is a young male whose ankylosis affects the sacroiliac, the intervertebral posterior and the costo-

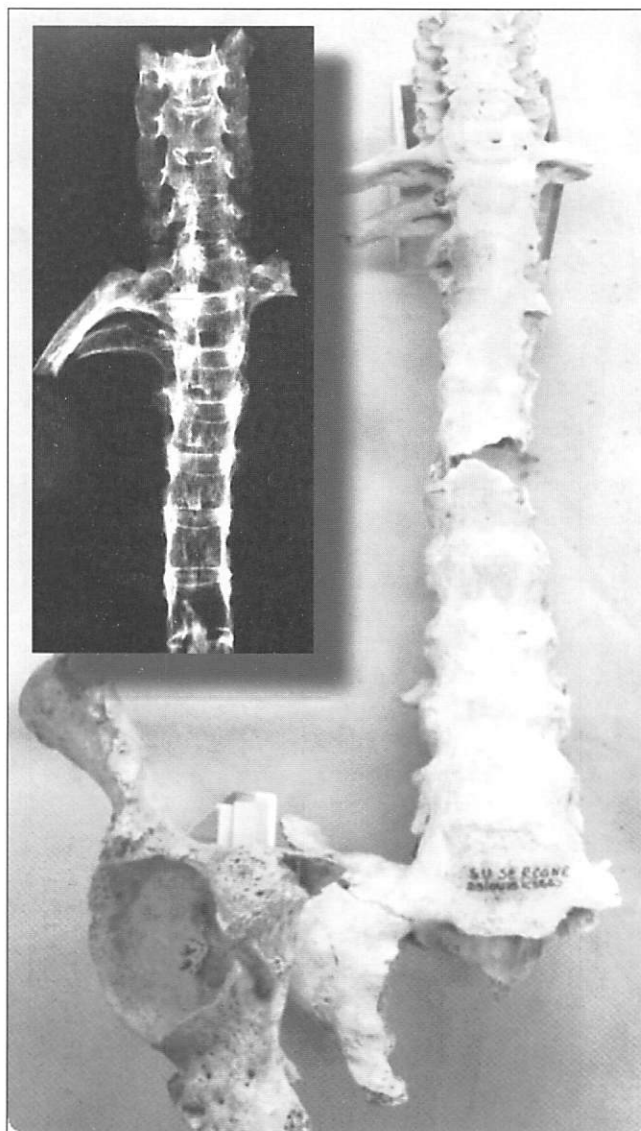


Fig. 1. Rx colonna a confronto, visione frontale

vertebral joints. Overall, the specimen shows the reduction of vertebral bodies, where bone bridges between vertebrae can be observed (syndesmophytes); the intervertebral discs do not vary their thickness nor do they appear ossified. The posterior apophyseal joints, affected together with the sacroiliac ones, show irregular surfaces, marginal erosions and ossification of the ligaments on the two sides up to the ankylosis.

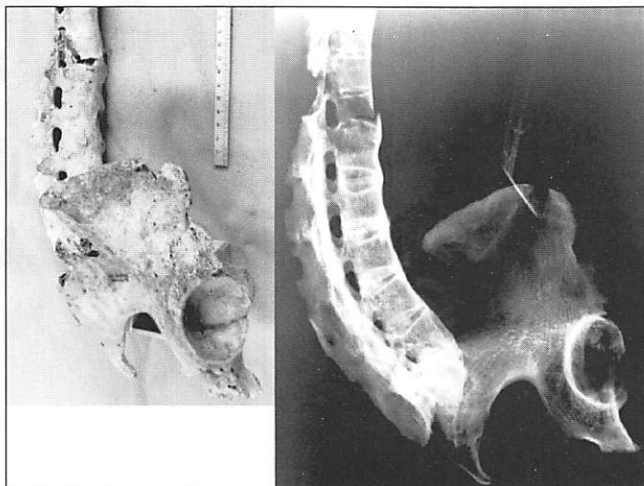


Fig. 2. RX colonna a confronto, visione laterale

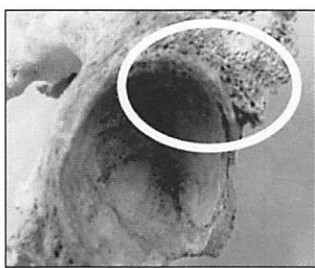


Fig. 3. Particolare acetabolo

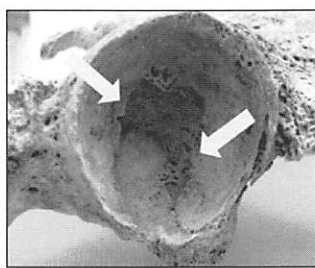


Fig. 4. Particolare acetabolo

Bone alterations are present above the coxo-femoral joint and inside the acetabular cavity, made up of irregular contours and periostotic bone formations (Fig. 2-3). X-ray examination on the remain confirmed the hypotheses formulated on ankylosing spondylitis during the macroscopic examination, with the detection of the disease's typical 'bamboo cane' pattern (Fig. 2).

## Discussion

Ankylosing spondylitis' etiology is unknown, however it is related both to genetic (based on the association with the histocompatibility antigen HLA-B27) and environmental factors (infections brought by *Yersinia*, *Chlamidiae*, *Shigella*, *Salmonella*). In Italy and Sardinia there low frequency of HLA-B\*2705 (subtype of HLA-B27). There seems to be

a reciprocal epidemiological distribution with malaria's *Plasmodium falciparum* (Mathieu, 2008).

This manifest itself with a typical posture involving the loss of mobility of the rachis; sideways vision and rotation of the shoulders and neck; reduced respiratory adaptability while under stress, neurological complications and problems to internal organs.

The specimen has been subjected to conservative treatment with the aim to preserve its integrity, and is now housed and on exhibit at the Sardinian Museum of Anthropology and Ethnography, Cagliari University. Its importance from a paleopathology standpoint lies on it being a record of this disease in a historic and geographic context (14C date: 1st century AD) where it is scarcely documented in Sardinia.

## References

- Aufderheide A., Rodriguez Martin C. 1998. *The Cambridge encyclopedia of Human Paleopathology*, Cambridge University Press, UK: 102-103.
- Canci A., Minozzi S. 2005. *Archeologia dei resti umani*. Carocci editore, Roma.
- Capasso L. 2001. *I fuggiaschi di Ercolano; paleobiologia delle vittime dell'eruzione vesuviana del 79 d. C.* "L'Erma" di Bretschneider, Roma.
- Mariotti V., Facchini F., Belcastro MG. 2007. The Study of Entheses: Proposal of a Standardised Scoring Method for Twenty-three Entheses of the Postcranial Skeleton. *Collegium Antropol.*, 31/1: 291-313.
- Martin R., Saller K. 1956-1957. *Lehrbuch der Anthropologie in Syxtematischer Dars Tellung* vol. I.
- Mathieu A., Cauli A., Fiorillo M.T., Sorrentino R. 2008. HLA-B27 and ankylosing spondylitis geographic distribution versus malaria endemic: casual or casual liaison? *Annals of the Rheumatic Diseases*, 67: 138-140.
- Ortner D.J., Putschar W.G. 1981. *Identification of pathological conditions in human skeletal remains*. Smithsonian Institution Press, Washington.
- Rogers J., Watt I., Dieppe P. 1985. Paleopathology of spinal osteophytosis, vertebral ankylosis, ankylosing spondylitis, and vertebral hyperostosis. *Annals of the Rheumatic Diseases*, 44: 113-120.
- Sarigu M. 2009. *I resti scheletrici umani di Su Sercone (Orgosolo)*. Tesi di Laurea RAN, Università Degli Studi di Cagliari Ubelaker D. 1989. *Human Skeletal Remains: excavation, analysis, interpretation*. Taraxacum, Washington.