

Multiple Circle-Shaped Lesions on Two Individuals from the Preroman Necropolis of Bazzano (Aq – Central Italy)

D.T. Cesana¹, R. D'Anastasio¹, M.L. Milia¹, A. Paolucci¹, M. Del Cimmuto¹, A. Fazio¹, M. Sciubba¹, G. Vitullo¹, L. Capasso¹

¹ Università degli Studi "G. d'Annunzio", Museo universitario, Piazza Trento e Trieste, 1, 66100 Chieti (Italy).
E-mail: denebcesana@gmail.com

KEY WORDS: cranial lesion, trauma, Abruzzo.

Introduction

The necropolis of Bazzano (L'Aquila) in Abruzzo (Central Italy) consists of more than 1250 burials dated back to a long period of time before roman conquest lasting from X century BC to I century BC.

Materials and Methods

The human remains from the grave n.108 belong to an adult male 46,6 ± 7 years old (Meindl and Lovejoy, 1985; Lamendin *et al.*, 1992).

The second skeleton, buried in grave n.110, is very fragmented. A pelvic lesion, probably due to a birth (Capasso and Di Tota, 1993), a moderate wear of pubic symphysis, ribs morphology and the canine root transparency (Brooks and Suchey, 1990; Iscan *et al.*, 1984; Lamendin *et al.*, 1992) suggest it could be a female individual of 58,9 ± 7.

Results and Discussion

Some enthesopathic and sindesmopathic lesions are observed in the scapular cingulum of T108, especially on the right side and correlated to an involvement in some heavy work activity and a poor lifestyle.

The general paleopathologic analysis of T108 revealed some arthritic manifestations localized in the sternoclavicular (both sides), scapula-humeral left, elbow and coxo-femoral joints.

The atlas shows asymmetric occipital condylar articulations and the axis shows an arthritic alteration.

On the *squama frontalis*, in the supraorbital area, two cranial lesions are macroscopically evident; they present a circle shaped morphology measuring 30 mm and 20 mm maximum diameters respectively (Fig. 1A). The skeleton does not show other traumatic manifestations which could be correlated to these cranial lesions.

The inner table corresponding to the lesion results to be porous, while the outer table is depressed and the surrounding bone tissue forms a double edged border with

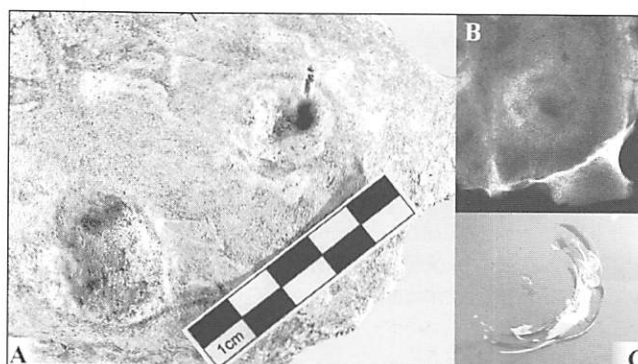


Fig. 1. T 108. A) Macroscopic aspect; B) Radiographic analysis C) Car glass fracture pattern.

semilunar shape observable macroscopically (Fig.1A) and radiographically (Fig. 1B).

The paleopathological analysis of T110 shows an early arthritic degenerative process of the vertebral column suggesting a low social status, confirmed by the analysis of a dental wear consistent with a poor diet.

The cranial lesion on the frontal bone (Fig. 2A) in the supraorbital right area shows a circular and crater shaped morphology with a 14 mm maximum diameter. The lesion is similar to the one observed in T108 but, comparing the resorption stages, T110 seems definitely more advanced healing. Such cranial lesions can be classified as comminuted depressed fracture due to blunt trauma (Lovell, 1997). In these cases the object hurt these individuals with a low speed impact not involving a complete fracture of the inner table through the diploe, as demonstrated by the radiographic analysis (Fig.2B).




Fig. 2. T 110. A) Macroscopic aspect; B) Radiographic analysis.

The localization on the supraorbital area, the absence of other lesions in the post-cranial skeleton and the similarity (regularity) of the shape exclude the hypothesis of an accidental fall.

The aspect of the point of impact on the external table of the cranial vault suggests an angle of incidence reduced tangent the frontal bone.

A comparison has been found in the dynamic of the accidental crash of a stone on a plane surface like a car glass (Fig. 1C). From a physic point of view the shock waves are comparable to those caused in the water or on a solid material (glass, bone, etc) by an object thrown tangent which produced concentric waves.

For these reasons it is presumable that the cranial lesions had been caused by an object thrown such as simply a stone. Preliminary paleopathological data need to be integrated and completed with archaeological and cultural information from the funerary context (including grave goods, not yet available).

In conclusion we can hypothesize that the individuals T108 and T110 were injured and survived for long time after a traumatic event, probably a stoning or an intentional assault with a blunt instrument. Concerning this interpretation, it is

necessary to continue researching in literature some case of stoning or similar events documented in paleopathology in order to compare these cases.

References

- Brooks S.T., Suchey J.M. 1990. Skeletal age determination based on the os pubis: a comparison of the Asca'di-Nemeske'ri and Suchey-Brooks methods. *Hum. Evol.*, 5: 227-238.
- Capasso L., Di Tota G. 1993. Le alterazioni scheletriche connesse alla gravidanza e al parto. *Annali Soc. Ortoped. Traumat. Italia Centr.*, 9: 307-322.
- Iscan M.Y., Loth S.R., Wright R.K. 1984. Age estimation from the rib by phase analysis: white males. *J. Forensic Sci.*, 29: 1094.
- Lamendin H., Baccino E., Humbert J.F., Tavernier J.C., Nossintchouk R.M., Zerilli A. 1992. A simple technique for age estimation in adult corpses: the two criteria dental method. *J. Forensic Sci.*, 37: 1373.
- Lovell N.C. 1997. Trauma analysis in paleopathology. *Yearbook of Physical Anthropology*, 104: 139-170.
- Meindl R.S., Lovejoy C.O. 1985. Ectocranial suture closure: a revised method for the determination of skeletal age at death based on the lateral-anterior sutures. *Am. J. Phys. Anthropol.*, 68: 57-66.