

Virtual Autopsy of two Egyptian Mummies from the Florentine Collection: a Preliminary Anthropological Analysis

M. Borrini¹, P.P. Mariani¹, G. Rosati²

¹ Università di Firenze, Dipartimento Scienze dell'Antichità, Medioevo e Rinascimento e Linguistica – Accademia Italiana di Scienze Forensi. E-mail: matteo.borrini@gmail.com

² Università di Firenze, Dipartimento Scienze dell'Antichità, Medioevo e Rinascimento e Linguistica

KEY WORDS: mummies, radiology, virtual autopsy.

Introduction

[...] *The encounter with two Egyptian mummies, glimpsed in a museum, irreparably provokes mixed feelings in our imagination; a thin miscellany of attraction and repulsion. The embalmed body, because of its antiquity, represents the touchable connection between our present and the past thousand-years full of questions. And the everlasting anxiety suddenly resurfaces from our subconscious about death, which is so deep-rooted in the human being. [...]*

When Willhem Conrad Roentgen discovered the X-rays, the 8th November 1895, the innovation was immediately seen as an important turning point in the world, not just because it represented the birth of the radiology: three month after the discovery, the British Egyptologist Flinders used the new technique to conduct the first radiographic study on a mummy from the Natural Sciences Museum of Vienna, revealing the not human but animal contents (Petrie, 1898). Since its early history, the value of radiological equipment has been recognized and quickly evolved for practical uses. During World War I some railway carriages were provided with small radiographic laboratories for medical use. Radiology has undergone a technological evolution since the development of the CT scan which gives more clear and highly diagnostic images, allowing us to realize some outright "virtual autopsy". The *virtopsy approach* has been used both for medical and historical-anthropological purposes as shown by several studies conducted on Egyptian mummies. As a matter of fact by using the non-invasive radiological methods it is possible to know in advance the content of a sarcophagus without extracting or unbandaging the mummy, avoiding risks for its conservation. The study of two mummies from two Florentine collections was undertaken in order to evaluate the contents of the inhumation and provide an osteological analysis of the deceased.

Materials and Methods

The sample consists of two sarcophagi: One from the Fredrick Stibbert Museum, and the other from the Franciscan Ethnographic Museum in Fiesole. A preliminary typological and philological study (started for a graduation thesis level and still in progress) of the sarcophagus from Fiesole shows just one "offering formula" inscription, while the sarcophagus from the Stibbert Museum, richer in texts and well preserved decorations, presents some important formulas such as pyramid texts, chapters from the "book of dead" (151 and 33) and person's names (among which is possible to read the owner's one "Irty.r.w" and her father's "Iwfaa", priest of Montu). From an iconographical point of view, thanks to the collaboration of national and foreign museums (Museum of Boston, Bolton Museum and British Museum) and by the comparison of some stylistic elements, such as the way of representing the face and the ornaments, it has been possible to date the two sarcophagus, presumably located in the "third intermediate period" 760-660 BC during the XV Egyptian dynasty. The museums' authorities asked for an anthropological analysis to be performed *in situ*, without moving the relics from their relative positions. For this reason it had been necessary to make use of a portable radiographic device with the backup of the radiologist Dr Rossini and his technical team. The recent scientific literature, which shows the use of this field equipment also in crime scenes, with the advantage of examining the remains *in loco*, supports the choice of this radiographic instrument, despite that it presents some difficulties in the use compared to more powerful and digital hospital instrumentation. Two small laboratories have been created in the museums; one for the x-ray photographs, and the other for their development; all used instrumentation which had been sterilized to avoid contamination. During the carrying out of the x-rays, a metal metric reference, which had been easily visible and identifiable, was placed nearby the mummy to help for the perspective distortions correction and to simplify further anthropometric analysis. The obtained radiographs have been digitalized and processed by current forensic

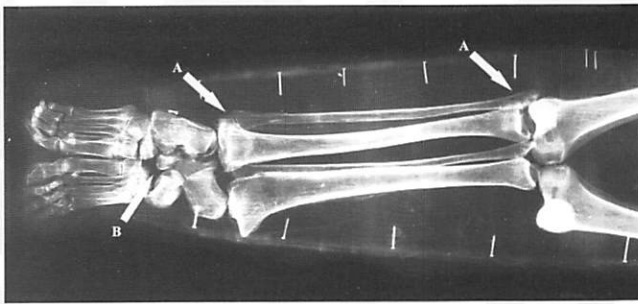


Fig. 1. The Stibbert's mummy. Leg bones are completely reversed: the knees are in the place of ankles and vice versa. The anatomical relation between tibia and fibula is still preserved (A); the overturning of legs also damaged feet involving a small disarticulation of tarsal bones (B).

standards (Reis, 2007) using the Adobe Photoshop CS3 software to back to scale the images to 1:1 and to assemble them together by the "photo merge" function, in order to obtain an overall view of the entire subjects' body. On the digitalized support, it was possible to stress some details by using filters and optic correcting level ("adjustable layer" function), to simplify the anthropological and anthropometric analysis.

The changeover from 3D to 2D vision represents an important aspect of this research due to its implication: it has been necessary to change the measurements reading procedures for skeletal remains (traditionally registered by calipers, goniometers, Ried's osteometric tablet), because it was possible to work only on two-dimensional margins, even having an entire subject. Due to this peculiar situation, some anthropometric measures had been necessarily left even if potentially useful because of the subjects' positions and their appearance on the x-rays.

Considering the forensic structure of this work, we used the FORDISC® 3.1 (Ousley and Jantz, 1996) statistic software, in addition to the traditional morphometric evaluations of the measurements obtained (Martin and Saller, 1957).

This software compares the osteometric measurements regarding the sex and ancestry of the subject with a database of 13 known populations, both modern and archaeological.

Results and Discussion

Comparing the metric data obtained both from the software and the comparison with Martin and Saller manual's values, it is possible to estimate the belonging for both mummies to a Mediterranean human type group, Egyptians-Theban.

Due to the position of the Fiesole individual, age assessment was limited to evaluation of chest plate alterations (Barrès *et al.*, 1989) while the Osiris' position on the Stibbert relic made the method inapplicable on it; other traditional methods (as Suchey-Brooks, Lamendin or Iscan) are avoided to not damage the bodies, while radiological dental methods resulted unusable for a superimposition of the two mummy sides on the lateral x-ray. The Fiesole's mummy presents an age-at-death of between 24 and 40 years; the Frederick Stibbert mummy presents general

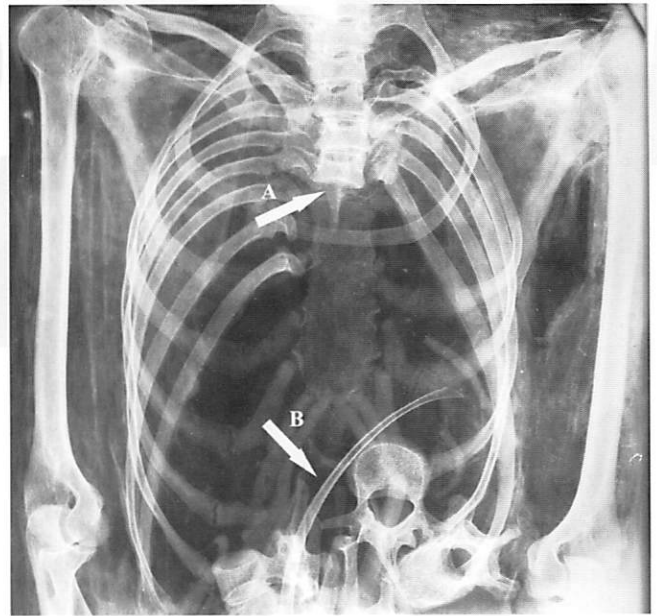


Fig. 2. Fiesole's mummy. The spinal column is preserved only as up to the 6th thoracic vertebra (A), the other vertebrae and ribs appear jumbled in the abdominal cavity (B).

skeletal conditions suggesting a similar young adult age. The x-ray approach also revealed traces of the mummification process: particularly in the breaking of the sphenoid area visible on the Stibbert's mummy, probably as a consequence of the hook action for brain evisceration.

Another relevant piece of data is the presence of two radiopacal areas located in the abdominal area of this mummy: presumably bandages with resin or organs replaced into the body after the mummification.

The bodies' position reports further details about the embalming ritual: while Fiesole's mummy shows outstretched arms with the hands on the pubes, the Stibbert's one shows the typical Osiris' position, generally reserved for high social classes, as also suggested by the bandaged organs placed in its abdomen.

Further osteobiographical details have been reconstructed by the radiographs' examination.

For instance the Fiesole's mummy shows a nearly complete loss of the dental elements (upper canines; upper premolars, except the second on the right; upper molars, except the second on the left; lower canines; premolars and molars) and periodontal disease; also Stibbert's mummy shows the loss of the entire dental elements except for the frontal ones. The alveolar bone reabsorption confirms the antemortal edentulous.

The lack of abscesses and infectious degenerations, the absence of carious lesions and the presence of occlusal wear surface associated to a periodontal disease apparently contradicting the general dental-skeletal state and the non senile age, they suggest for both mummies a diet rich of abrasive materials such as collagen, cellulose and silica. No other pathological condition connectable to the periodontal diseases are discovered in the subjects, consistent with Filer (Filer, 1995), who noticed in the royal mummies of the British Museum (among which Ramesse II, Thuya, Yuya and Merenptah) how the denture was in good

health without evidence of pathologies while it showed a high degree of occlusal wear due to eating habits. Under a pathologic point of view, a reduction of the meniscus area, a slight arthrosis on the medial left femoral condyle and an appreciable arthritic coxofemoral degeneration on the same side on the Fiesole's mummy are discovered. The acromion shows a clear degeneration of the acromioclavicular joint with calcification of the rotator cuff ligaments commonly known as periarthritis. The Stibbert's mummy instead shows a skeletal structure less abounding in pathologies; noteworthy a slight coxoarthrosis on the right side associated with acetabular thickening without spicules and space reduction between the *caput femoris* and the hip bone; it is however, necessary to interpret this last modification as the consequence of the increase on the contralateral area due to a modern manipulation of the corpse.

This preliminary virtopsy also revealed evidence of post-mummification alterations to the remains. Fiesole's mummy was profaned by grave robbers with the intent of finding some jewels and amulets, usually present in the abdominal cavity: the spine is intact to the sixth thoracic vertebra, below this point the vertebrae and ribs are disarticulated and mixed up into the abdominal cavity. The sacrum has been found outside the body, in the sarcophagus. The wrappings were penetrated from the posterior surface but an attempt has been made by the perpetrator to rebandage the defect making it difficult to detect with the naked eye. No other lesions have been discovered and the hands are untouched in the original: this evidence suggests that the invasive intervention by the desecrators did not reach the front surface and the pubic area of the mummy.

Evidence of modern tampering to the Stibbert mummy is shown by unoriginal bandages and the presence of a wooden board used to support the body; x rays also revealed how the left hand, which emerges from the bands, is completely disarticulated and repositioned with a 180° angle respect the radius-ulnar joint: the hand is in a palm position on the contrary of the forearm position. The right humerus presents a linear fracture without healing in the olecranal fossa and a complete separation of the distal epiphysis which keeps a tight elbow articulation

with the radius and ulna. Symmetrically, the left ulna is out of its natural anatomic proximal seat. The data from the two elbows suggests that these lesions occurred when the desecrators tried to remove the bandages from the mummy in an Osiris' position. Most likely during this activity some movements that misaligned the rachis also took place, as it can be seen between the thoracic and lower lumbar vertebrae. It is also quite remarkable that the wrong position of the legs (Fig. 1) is certainly assignable to the unbandaging operations that violators executed to pillage the mummy from amulets and jewels: fibulas and tibias appear rotated 180° with the proximal epiphysis near the ankles and the distal epiphysis at knees level.

Conclusion

Finally the authors, conscious that the use of a CT scan could better answer some unsolved questions such as the personal data of the Stibbert's mummy, like to highlight how the *virtopsy approach* is valid also turning to editing software and traditional measurements evaluation which preserve the relics' conservation in their original expositive place.

This preliminary analysis on these two Florentine mummies will certainly carry on as there are still samples which must be examined and studied to complete and close the entire anthropological analysis.

References

- Barrès D.R., Durigon M., Paraire F. 1989. Age estimations from quantitation of features of chets plate X rays. *J. Forensic. Sci.*, 34: 228-233.
- Filer J. 1995. *Disease* (Egyptian Bookshelf), British Museum Press, Londra.
- Martin R., Saller K. 1957-6. *Lehrbuch der Anthropologie*, Fischer, Stoccarda.
- Ousley S., Jantz L. 1996. Fordisc 2.0 personal computer discriminant functions. *Int. J. Osteoarchaeol.*, 8: 128-133.
- Petrie W. F. 1898. Deshaheh, *The Egypt Exploration Fund*, 15: 25-31.
- Reis G. 2007. *Photoshop CS3 for Forensic Professionals*, Wiley Publishing, Indiana (USA).