

3d Computer-Assisted Analysis and Scanning Electron Microscopy in the Morphological Study of Fetal Nuchal Translucency

G.L. Panattoni*, C. Torre*, G. Mattutino*, E. Castelli**, S. Bontempo**, T. Todros**

* Department of Anatomy, Pharmacology and Forensic Medicine. University of Turin

** Department of Gynecology and Obstetrics. University of Turin

Abstract

Nuchal translucency (NT) is an echo-free area detectable by ultrasound in human fetus at 9-14 weeks of gestational age, at the level of the soft tissues of the nuchal region. The 3D morphological features of a cavity corresponding to NT were examined directly in a specimen of human fetus, by computer-assisted methods and compared with previous findings obtained by scanning electron microscope. In order to reconstruct the 3D morphology of NT cavity, 66 serial sagittal sections of a human fetus (11 weeks of gestational age, C-R L: 48 mm) were digitalized, processed by Adobe Photoshop 4.0 to enhance contrast and detect edges, rotated into alignment based on fiducial points and analysed by NIH Image 1.61 software for Macintosh. These images were utilized to create a stack and to obtain new two-dimensional images corresponding to different sectional planes. This methods allowed to describe the fetal cavity, that shows spatial relationships and morphological characters of an enlarged lymph sac.

Introduction

Nuchal translucency (NT) is a transient anechoic area, normally detectable by ultrasound in human fetuses at 9-14 weeks of gestational age at the level of the soft tissues of the nuchal region. Several studies (1,2) have demonstrated an association between an abnormal ventro-dorsal diameter of NT (≥ 2.5 -3 mm) and aneuploidy, particularly Down's syndrome. Increased NT has been found to be a marker of other underlying pathologies, but the most common association appears to be with cardiac abnormalities; for this reason, tests using NT measurement in the first trimester are commonly utilized in clinical practice.

Some hypotheses were made to assess the natural history of normal NT and to explain pathological NT: one is that NT is due to an abnormal development of the lymphatic vessels, but its origin is still unclear. In our previous works (3,4), we examined the sonographic patterns of NT in

normal pregnancies and identified two symmetrical cavities corresponding to sonographic NT in a normal fetus. The morphological features of the cavities, observed by light and scanning electron microscope (SEM), suggested that they are the superficial recesses of the jugular lymphatic sacs and the appearance of NT is related to drainage mechanism of the lymph vessels into the venous system during development. In particular, our data suggested that normal NT is due to a temporary lack of connection between jugular sacs and internal jugular veins, with consequent enlargement of the sacs. More recently, we analysed these results by computer-assisted methods of image processing, in order to obtain data on the 3D morphology of NT and to compare them to our previous results. In this paper, we describe the methodological aspects of these last studies.

Image processing method for 3D-reconstruction of NT

To reconstruct the 3D morphology of NT cavity, we utilized 66 serial sagittal sections (7 μ m in thickness) of the nuchal region of a human fetus (11 weeks of gestational age, C-R L: 48 mm). The sections were stained with haematoxylin-eosin and examined by light microscope (LM). The images of NT cavity were digitalized by scanner Microtek ScanMaker II, processed by Adobe Photoshop 4.0 software to enhance contrast and detect edges, rotated into alignment based on fiducial points and oriented according to a vertical plane tangential to the nuchal skin of the fetus.

These images were analyzed by NIH Image 1.61 software to obtain a 3D reconstruction of NT cavity and new two-dimensional images corresponding to different sectional planes. "NIH Image" is an image processing program, developed at the Research Services Branch of the National Institutes of Health (NIH). This program, that is designed for many applications (from DNA gel analysis to 3-dimensional volume reconstruction), can acquire, edit and analyze images with a broad range of functions, including contrast enhancement, density profiling, etc. "NIH Image" is able to convert a series of 2D images into a volume, called a stack, i.e. a 3D reconstruction that can be resliced in different planes and viewed from different orientations. It is also possible to generate an animation sequence by

projecting through a rotating 3D data set onto a plane. This program allowed to obtain a 3D model of each NT cavity with a rhomboidal shape on the frontal plane (fig. 1), irregular edges, maximum transverse diameter of 560 μm and cranio-caudal diameter of 810 μm . Projected on the sagittal plane, the cavity shows a maximum antero-posterior diameter of about 500 μm . The distance between the cavity and the surface of nuchal skin varies from 300 to 800 μm .

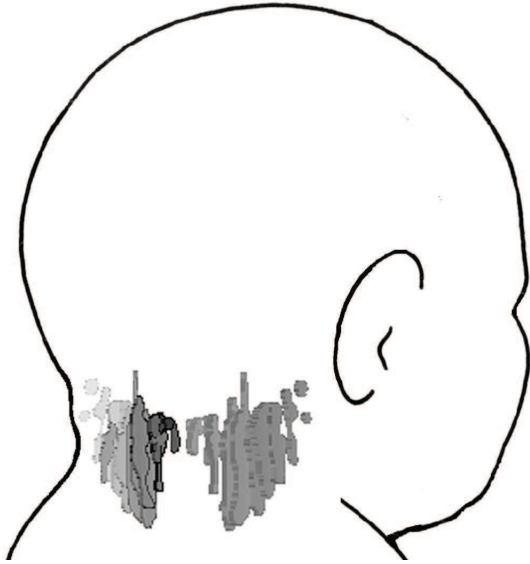


Fig. 1. 3D reconstructions of NT cavities, imaged on the nuchal region of a fetus.

Conclusion

The comparison of the 3D reconstruction of NT with our previous findings obtained by light and scanning electron microscope and with the reconstructions of the fetal

limphatic system reported in the embryological literature seems to confirm the hypothesis that the two symmetrical cavities are enlarged jugular lymph sacs. In fact, in the previous microscopic observations the cavities showed histological features of lymphatic spaces: they are lined by a single layer of flattened cells showing characters of fenestrated endothelium and are surrounded by a loose subcutaneous mesenchymal tissue. Moreover, the 3D computer-assisted analysis of NT morphology confirms that the sonographic image of NT seems to be the result of superimposition of these cavities projected on the sagittal plane. The appearance of an echo-free area with larger dimensions and more regular shape is due to the low resolution of the sonographic images with respect to the microscopic images.

Key words

Nuchal translucency, human fetus, 3D morphology, scanning electron microscopy.

This work was supported by a grant of the M.I.U.R. (ex 60%) of Italy.

References

- [1] Nicolaides K.H., Azar G., Byrne D., Mansur C., Marks K., 1992. Fetal nuchal translucency: ultrasound screening for chromosomal defects in first trimester of pregnancy. *Brit. Med. J.*, 304: 876-869.
- [2] Hyett J.A., Moscoso G., Nicolaides K.H., 1995. First-trimester nuchal translucency and cardiac septal defects in fetuses with trisomy 21. *Am. J. Obstet. Gynecol.*, 172: 1411-1413.
- [3] Castelli E., Lombardo P., Panattoni G.L., Todros T., 1998. Fetal nuchal translucency: just a sonographic image or a real anatomical structure? *J. Biol. Res. - Boll. Soc. It. Biol. Sper.*, 74: 15-18.
- [4] Castelli E., Todros T., Mattutino G., Torre C., Panattoni G.L., 2003. Light and scanning electron microscope study of nuchal translucency in a normal fetus. *Ultrasound Obst. Gyn.*, 21: 514-516.