

# Tissue Identification and Histologic Findings in Four Specimens from Egyptian Canopic Jars

Luca Ventura<sup>1</sup>, Cinzia Mercurio<sup>1</sup>, Cristina Guidotti<sup>2</sup>, Gino Fornaciari<sup>3</sup>

<sup>1</sup> Department of Pathology, City Hospital, L'Aquila, Italy;

<sup>2</sup> Archaeological Superintendence of Tuscany, Firenze, Italy;

<sup>3</sup> Department of Oncology, Section of History of Medicine and Paleopathology, University of Pisa, Italy

KEY WORDS: canopic jars, histology, lung, silicoanthracosis.

## Abstract

**Canopic jars content represents a relatively rare material, with few studies available. Object of our study were dehydrated fragments found in four canopic jars from the Egyptian Museum of Florence, belonging to a single, anonymous individual of the New Kingdom. Tissue samples were embedded in agar to prevent fragmentation and rehydrated with Sandison solution for 2-5 days. Rehydrated samples were post-fixed in 10% buffered formalin, routinely processed and paraffin embedded to obtain sections stained with different methods. Two specimens showed histological features of lung with multifocal deposition of anthracotic pigment and small polarizable crystals, allowing the diagnosis of pulmonary silico-anthracosis. The histologic study of the other two samples was unsatisfactory: attached on the slides remained only small amorphous fragments, containing birefringent fibers, probably related to the linen packets wrapping the organs. Such findings confirm that histological methods may provide useful results even with material obtained from canopic jars.**

## Introduction

The canopic jars content represents a relatively rare material and a limited number of studies is available about this topic (Walker et al., 1987). Histologic evaluation of these materials yields useful information about health status and diseases of ancient Egyptians (Shaw, 1938; Walker et al. 1987).

Object of the present study were the dehydrated fragments found in four canopic jars from the Egyptian

Museum of Florence, belonging to a single, anonymous individual of the New Kingdom (1550-1069 BC, XVIII-XX Dynasties).

## Material and Methods

Tissue samples were rehydrated with Sandison solution for 2-5 days, after preliminary embedding in agar (Ventura et al., 2001), performed in order to prevent tissue fragmentation and swelling (Fig. 1). Rehydrated samples were post-fixed in 10% buffered formalin for 1 day, routinely processed and embedded in paraffin to obtain 4 µm-thick sections stained with the following methods: hematoxylin-eosin, Masson's trichrome, reticulin, periodic acid-Schiff also after diastase digestion, Perls, van Gieson and Ziehl-Neelsen.




Fig. 1 - The samples rehydrated after preliminary embedding in agar.

## Results

The specimens in the first two jars (with human and hawk's heads) showed histological features of lung tissue with multifocal deposition of anthracotic pigment, fibrosis (Fig. 2) and the presence of small polarizable crystals, mostly within fibrotic areas (Fig. 3). These findings allowed the diagnosis of pulmonary silicoanthracosis. No hemosiderin was evident in Perls stained slides.

The histologic study of the samples found in the other two jars (with jackal's and baboon's heads) was unsatisfactory. Despite the large number of rehydration attempts, attached on the slides remained only small amorphous,

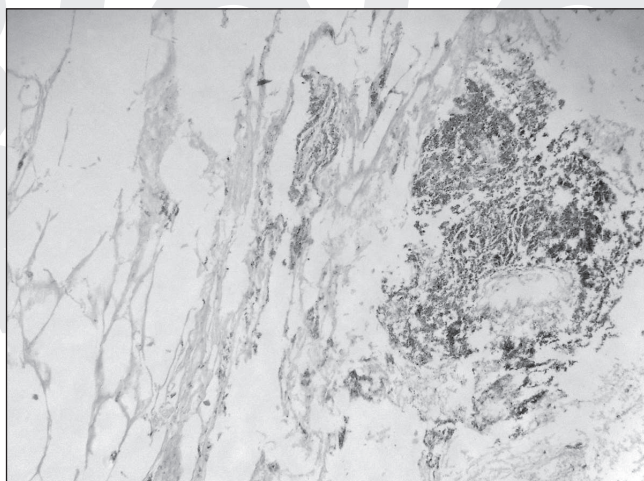


Fig. 2 - Lung with anthracotic pigment deposition and fibrosis (specimen FI 2198).

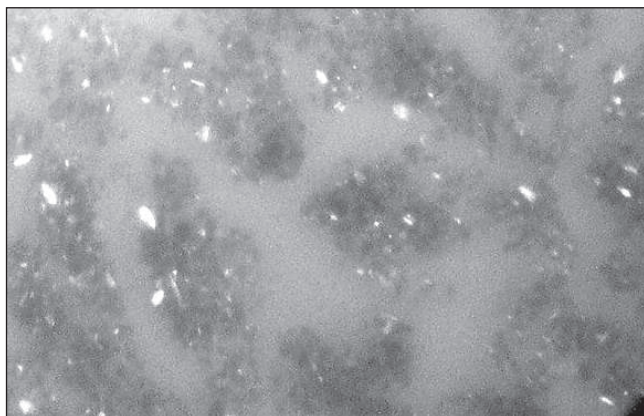


Fig. 3 - Polarizable crystals found within a fibrotic area (specimen FI 2198).




Fig. 4 - Wide birefringent fibers within amorphous material (specimen FI 2200).

brownish fragments, containing birefringent fibers, probably related to the linen packets wrapping the organs (Fig. 4).

## Discussion

Histological examination allowed to recognize the organs of origin and identify pathological conditions in two of the specimens. The presence of pulmonary silicoanthracosis confirms that these pneumoconioses were relatively common in ancient Egypt.

Pulmonary anthracosis represents an extremely common finding in ancient bodies, being related to the inhalation of carbon particles from indoor heating and cooking fires (Aufderheide, 2003; Cockburn et al., 1998). In some cases anthracotic pigment deposition is accompanied by fibrotic reaction of the tissue, due to other toxic substances.

Silicosis is a different form of pneumoconiosis secondary to the inhalation of silica and silicates contained in sandy soils (Aufderheide, 2003; Cockburn et al., 1975). Variable degrees of lung fibrosis from such deposits has been reported in mummies, usually in combination with anthracosis (silicoanthracosis) (Aufderheide, 2003).

The diagnosis is microscopically established in dark-colored lungs after exclusion of hemoglobin products and observing refractile silicates crystals by polarized light (Aufderheide, 2003). The presence of small crystals within pulmonary fibrotic areas helps to distinguish true silicosis from postmortem sand contamination (Walker et al., 1987; Aufderheide, 2003).

Such findings confirm that routine histological methods may provide useful results even with material obtained from canopic jars.

## Literature Cited

- Aufderheide AC. 2003. The scientific study of mummies. Cambridge University Press.
- Cockburn A, Barraco RA, Reyman TA, Peck WH. 1975. Autopsy of an Egyptian mummy. *Science* 187: 1155-1160.
- Cockburn A, Cockburn E, Reyman TA. 1998. Mummies, disease and ancient cultures. Second Edition. Cambridge: University Press.
- Shaw AFB. 1938. A histological study of the mummy of Har-mosû, the singer of the eighteenth dynasty (circa 1490 B. C.). *J Path Bact* 47, 115-123.
- Ventura L, Taglieri L. 2001. Agar embedding technique in histopaleopathology. *Paleopathol News* 116: 7-9.
- Walker R, Parsche F, Bierbrier M, McKerrow JH. 1987. Tissue identification and histologic study of six lung specimens from Egyptian mummies. *Am J Phys Anthropol* 72: 43-48.