

Facial Reconstruction Project

Federico Cesarani¹, Maria Cristina Martina², Valter Capussotto³, Andrea Giuliano³, Renato Grilletto⁴, Rosa Boano⁴, Anna Maria Donadoni Roveri⁵, Maurizio Celia⁶, Giovanni Gandini²

¹ Struttura Operativa Complessa di Radiodiagnostica, Presidi Ospedalieri Riuniti, Azienda Sanitaria Locale 19, Asti, Regione Piemonte. Italy

² Istituto di Radiologia Diagnostica ed Interventistica. Università di Torino, Azienda Ospedaliera S. Giovanni Battista, Ospedale Molinette. Corso Bramante 84, 10126 Torino, Italy

³ Gabinetto Interregionale di Polizia Scientifica per il Piemonte e la Valle d'Aosta di Torino, Torino, Italy

⁴ Museo di Antropologia ed Etnografia. Dipartimento di Biologia Animale e dell'Uomo Via Accademia Albertina 13, 10123 Torino, Italy

⁵ Soprintendenza al Museo delle Antichità Egizie di Torino. Via Accademia delle Scienze 6, 10123 Torino, Italy

⁶ Dirigente della Polizia di Stato – Imperia, Italy

KEY WORDS: mummy, Facial Reconstruction, three-dimensional MDCT, Manchester protocol

Abstract

Facial reconstruction of mummies and corpses is important in anthropological, medical and forensic studies. The purpose of our study was to evaluate the role of three-Dimensional Multidetector CT examination for 3D facial reconstruction. We present a multidisciplinary work performed by radiologists, anthropologists and forensic police in reconstructing the possible physiognomy of an ancient Egyptian mummy.

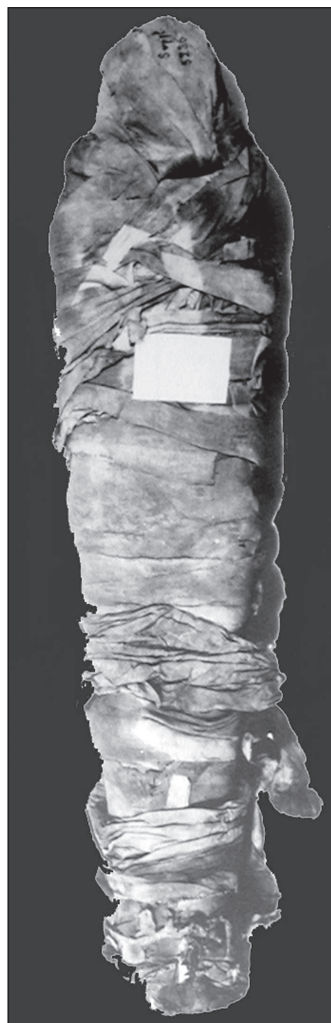Three-Dimensional data were obtained from a well-preserved completely wrapped Egyptian mummy from the collection of the Egyptian Museum in Torino, Italy, dated from XXII or XXIII dynasty (945-715 BC). Data were used as a model for the rapid prototyping stereolithographic technique, a method which allows the creation of 3D model with digital data using synthetic materials such as resin or nylon.

Introduction

We report the results of a multidisciplinary study performed by radiologists, anthropologists and forensic police to reconstruct the physiognomy of an ancient Egyptian mummy. The study produced a model of the face of an individual who lived nearly 3,000 years ago. Our purpose was to evaluate the role of MDCT examination in 3D facial reconstruction.

Materials and methods

The facial reconstruction concerned the mummy of Harwa (accession number, SUPPL 5226, CGT 13011), an artisan who lived during the XXII or XXIII Dynasty (945-715 BC). The mummy was found in the Valley of the Queens by E. Schiaparelli during his archaeological excavations in 1903-1906 (Schiaparelli, 1923) (Fig. 1).



The procedures used to produce the final model can be divided into several steps.

The first step was data acquisition using an MDCT scanner (Light Speed QX/i, GE Healthcare).

Preliminary anteroposterior and lateral scout images were obtained to optimize the field of view. The following parameters were used for the dedicated acquisition of the head: helical scanning, 0.8-sec rotation time, 1.25-mm slice thickness, 7.5 mm/sec table speed, 0.7-mm reconstruction interval, large field of view, 120 kV and 140 mA. Three hundred fifty-five images were obtained, with a scanning time of 27.4 sec. The second step consisted of post-processing with a Precision 530 workstation

Fig. 1 - mummy of Harwa.

with Intel Xeon 1.7 GHz dual processors and 2,048 MB of random access memory (Dell Computer) with Vitrea version 2.5 software (Vital Images). After the analysis of external aspects of the head, which was automatically reconstructed by the software, the virtual removal of the bandages was performed (Fig. 2).

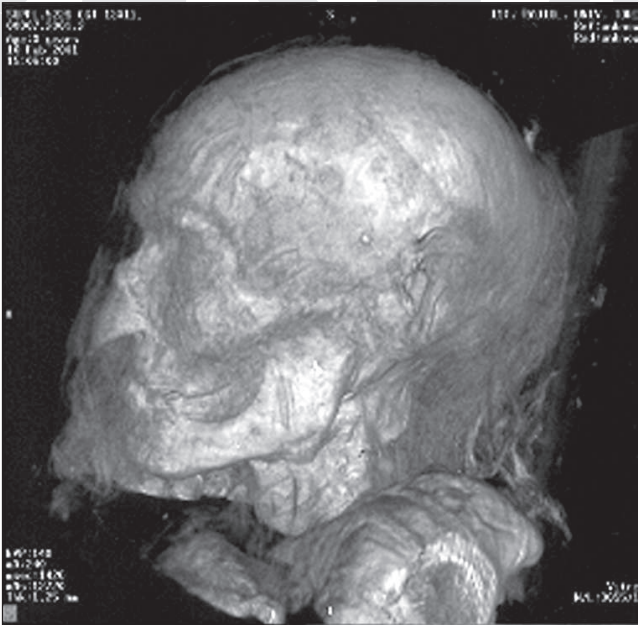


Fig. 2 - First 3D reconstruction of face of mummy includes residual soft tissues after virtual removal of bandages.

The third step consisted of generating the computerized CT data to obtain two resin models. The first was a highly precise cast of the skull and the second was the face of the mummy with its residual soft tissues still present under the bandages. For the skull model, the bone structures were easily distinguished from the soft tissues according to their density (Fig. 3), but for the second model an accurate delimitation of the soft tissues of the face had to be performed on each CT slice. This was achieved by cooperation between the radiologists and the computer-assisted design technician to exclude the bandages and debris from the reconstruction.

These data were then transferred to a Vanguard selective laser sintering system (3D Systems Italia) for reproduction of the resin model. The selective laser sintering system produces a model by polymerizing thin layers of plastic material using the computer-assisted design file of an object. We used Polyamide powders (Duraform). The reconstruction was performed in steps of 0.1 mm, working from the neck to the vertex. After the model cooled, excess powders were removed and computerized system checked the resulting model against the mathematic model to detect possible inaccuracies.

The final facial reconstruction was obtained on the skull cast by the combined work of the anthropologist and forensic artist using the Manchester reconstruction method (Prag and Neave, 1997) and the information provided by the residual soft tissues. In particular, pegs were positioned at marked points on the resin skull model according to the

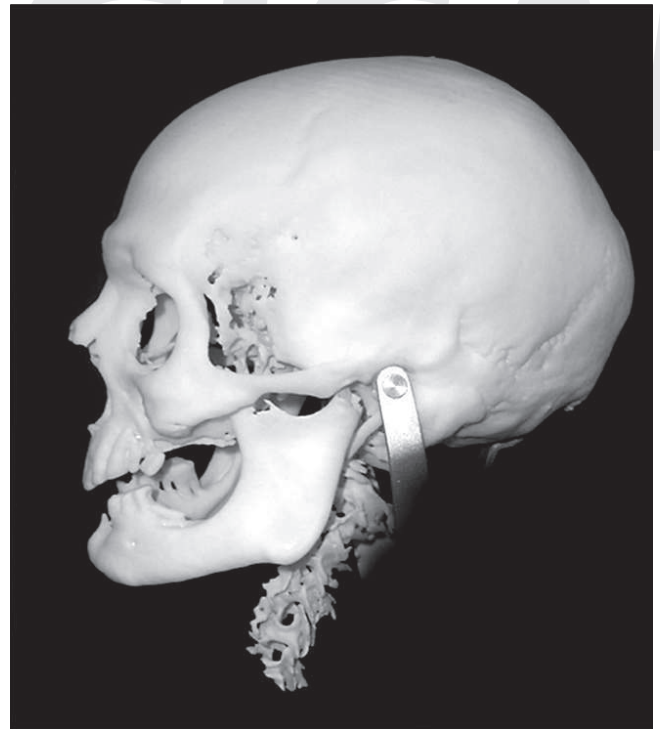


Fig. 3 - Resin model of skull obtained using selective laser sintering system.

protocol parameters to determine the correct thickness of the soft tissues. The model with the residual soft tissues provided important information about the morphology of the nose, mouth and ears (Fig. 4).




Fig. 4 - Final model shows facial reconstruction according to funerary mask style.

We decided not to add a beard, moustache, hair or makeup so as to limit artistic interpretation and give precedence to the scientific data.

Results

The facial reconstruction allowed the identification of a man approximately 45 years old at the time of death. We must emphasize that the reconstruction did not allow us to establish the fatty layers of the face. Muscle insertions were clearly visible on the skull bones reconstructed according to the CT data and they helped the forensic artist and anthropologist to infer possible thickness of the muscles; however, fat does not leave signs on the skull. For this reason, as well as dehydration and the embalming procedures, we do not know how fat the face was. The reconstruction parameters established for an average individual were attributed to the face of Harwa, according to the CT data of previously studies (Cesarani et al., 2003) and the cranial indexes.

Details of the soft tissues were reproduced with high accuracy. In fact, a small lesion was reproduced on the superficial surface of the left temporal area. Visible on the axial scans as a small isodense homogeneous lesion without calcifications, it is probably a nevus.

Conclusion

Facial reconstruction from human remains is fundamental

in forensic science for the identification of bodies. However, it is also of interest in archaeology and palaeoanthropology. Indeed, it is one of the ways in which archaeologists seek to characterize the individuals of certain societies and it can supplement the data collected by traditional physical and forensic anthropology. In particular, we wish to emphasize the role played by virtual unwrapping. CT is the only non-invasive method to obtain fundamental data for 3D reconstructions of the head and body, especially in wrapped mummies. Multidisciplinary cooperation was essential during the different phases of reconstruction. Although we followed a strict scientific protocol, variability in the final results can be admitted because of some subjective interpretation of the forensic artist.

Literature Cited

- Cesarani F, Martina MC, Ferraris A, Grilletto R, Boano R, Fiore Marochetti E, Donadoni AM, Gandini G. 2003. Whole-body three-dimensional multidetector CT of 13 Egyptian human mummies. *AJR* 180:597-606.
- Prag J, Neave R. 1997. *Making faces using forensic and archaeological evidence*. London: British Museum Press
- Schiaparelli E. 1923. *Relazione sui lavori della Missione Archeologica Italiana in Egitto (anni 1903-1920), Vol. I. Esplorazione della Valle delle Regine*. Torino: Regio Museo delle Antichità.