

# The Museum's Mummies: An Inside View

David T. Mininberg

MD, MA 860 Fifth Avenue, New York, New York, 10021

KEY WORDS: mummies, egypt, CAT scan

## Abstract

**We have performed CAT scan imaging of the thirteen mummies in the New York The Metropolitan Museum of Art. This non-invasive technique allowed us to ascertain the age (+/- 5 years), the height and the sex of these individuals. In two cases we were able to establish the cause of death – one man dying as the result of trauma and one woman dying of sepsis secondary to an abscess in the mandible. We discovered two necklaces of amulets on one of the mummies and integrating the CAT scan images, we were able to identify the amulets. These two necklaces had previously been unknown to the museum staff. In one instance, the museum has the encaustic portrait mask in place on the mummy itself, so we were able to compare the portrait with the CAT scan image of the mummy and establish that in this particular case the image was a true portrait rather than an idealized portrayal of the person.**

## Introduction

People have always been fascinated by mummies. How and why were they made? What is the secret of their preservation? In the 18<sup>th</sup> century a proper European gentleman would return home with many souvenirs of his grand tour including an Egyptian mummy. In order to satisfy people's curiosity, a group of his peers would be invited to an unwrapping performed by a prominent local surgeon and attended by members of the scientific community. Occasionally, jewelry, amulets or papyri would be found. Afterwards the mummy was discarded. Modern technology in the form of CAT scanning allows us to "virtually" unwrap the mummy to obtain the anatomic and scientific information we need to better understand the

ancient Egyptians. After this non-invasive information gathering procedure the mummies are intact for possible future investigations.

## Materials and methods

The CAT scanning was done with a Philips Tomoscan M Mobile CT System. Additional detailed images were obtained with a General Electric C arm. These systems were generously provided to us, in the museum, by the manufacturers. Eastman Kodak supplied all the discs and film. Additionally, each of the companies provided engineering and technical support as we worked. Weill Medical College of Cornell University – The New York Hospital Department of Radiology provided its chief and a senior technician for the duration of this study.

The Metropolitan Museum of Art Department of Egyptian Art's curatorial staff and conservators were available throughout this study with advice and encouragement. We all wore plastic gloves when in contact with the mummies to protect them from any bacteria or oils on our hands. Imaging techniques were standard with some slight modifications to accommodate unusual thickness of a mummy's wrapping. The CT sections were made at 5mm intervals with areas of particular interest studied at 2 mm intervals. The scanning was done with the mummies prone. We were concerned that moving the mummies into other positions might be deleterious for them. The images were studied in real time so that any needed adjustments could be made.

## Study population

Our study population, which is displayed in Table I, spans essentially the entire Pharaonic era from 3000 BC to 200 AD. The records of the archeological sites and digs are also helpful in dating the mummies.

## Results

We were able to determine the age, sex and height of the individuals in our study. Our markers for the sex of the individual were predominantly the configuration of the pelvis

and the jaw. Standard radiological criteria were applied to make these determinations. Our population includes 8 men and 5 women. The age of the individuals was assigned based on the degree and extent of degenerative joint disease, the number and condition of the teeth and the degree of parietal atrophy, again applying standard radiological criteria. Using these methods we could determine the age +/- 5 years. Our study population's ages ranged from 4 to 50 years old. Their stature (height) was determined by measuring the femur and tibia or fibula or both when possible.

The standard regression equations of Trotter and Gleser (1952) were used to calculate the heights (Table 2). Our measurements and calculations were facilitated by the

study group. Neferi (MMA 20.4) was a 25-30 year old woman who lived during the Ptolemaic period (332-30 BC). Her skeletal remains are in pristine condition with the sole exception of the molar region of her jaw. On the left side there is a walled off abscess with evidence of bone erosion (Fig. 1). This finding points to septicemia as the cause of death in an era before the availability of antibiotics or surgical drainage to treat the condition.

Nesi Amun was a 50 year old man who lived during Dynasty 25 (715-656 BC). He sustained significant trauma as evidenced by a fractured pelvis, fracture of the left humerus, striking disarray of his ribs and a linear skull fracture. The site of the humeral fracture has abundant callus formation

indicating that he survived the trauma for many weeks (Fig. 2). There are extraneous bones in the abdominal cavity along with triangular shaped rods extending from the posterior aspect of the skull and traversing the spinal canal as well as one rod on each side of the retroperitoneal, paraspinal spaces. These rods have been identified as *Cyperus papyrus* (Tackholm and Drar (1950)). We postulate that the undertakers had placed these rods and bones to stabilize the mummy at the time of mummification. Of interest, modern neurosurgeons and orthopedic surgeons use rods to stabilize and strengthen the spine.

We considered the most likely explanation for the cause of death to be either injury while working on a construction site, military wounds or the result of a vehicular accident as horses and chariots were in use at that time. We consulted with Dr. Charles Hirsch, chief medical examiner of New York City. He and his staff stated that these injuries were the typical constellation seen today in victims of a motor vehicle accident.

This fits our mummy, making appropriate changes for the agent of the trauma. One of our study group allowed us to address the question of how true to life are the portraits painted on the wood panels covering the area of the face found on mummies from the Greco-Roman period. The Fayum portrait mummy (MMA 11.139) was a 20-25 year old man at the time of death who lived in the 2<sup>nd</sup> C.A.D. He was in good general condition with no discernible cause of death. We enlisted the assistance of Peggy Ott, an anthropologist, and Stephen Mancusi, a forensic artist who works with the New

York City Police Department. They worked from the CT scans only. We also told them the individual's age and the time in history during which he lived. The image Mr. Mancusi rendered is a remarkably close likeness to the painted

NAME	PERIOD	AGE	SEX	LOCATION
Predynastic burial 99.3.5	Predynastic	? 50	M	
Not on view				
Nephtys 11.50.15	Dynasty 12	40 -45	F	Gallery 8
Khnumhotep 12.182.131	Dynasty 12	45 - 50	M	
Gallery 9				
Ukhotep 12.182.132	Dynasty 12	30 -35	M	
Gallery 9				
Amenemhat 19.3.208	Dynasty 18	4	M	
Gallery 24A				
Kharushere 86.1.35	Dynasty 20-25	30 -35	M	
Gallery 21				
Nesi-Amun 26.3.11	Dynasty 25	50	M	Gallery 24A
Neferi 20. 4	Ptolemaic	25 - 30	F	Gallery 24A
Ta-sheri-en-Isset 12 182.48	Ptolemaic	30	F	Gallery 27
Irti Rutja 86.1.52	Ptolemaic	30 - 35	?	Gallery 27
Esmin 86.1.51	Ptolemaic	40 - 45	M	Gallery 27
Artemidora 11.155.5	1st C.A.D.	25	F	
Gallery 32				
Fayum Portrait Mummy 11.139	2nd C.A.D.	30 -35		
M	Gallery 31			
"Hartford" mummy 25.3.219	3rd C.A.D.	30	F	Not on view

Table 1 - Human Mummy.

NAME	AGE	HEIGHT: FEMUR and FIBULA	HEIGHT: FEMUR and TIBIA
Nephtys	40-45	166.5± 3.86	Tibia only 166.6 ± 4.0
Khnumhotep	45-50	Femur only 168.07 ± 3.94	169.40 ± 3.74
Ukhotep	30-35	Femur only 190.80 ± 3.94	190.57 ± 3.74
Amenemhat	4	96.45 ± 3.62	99.8 ± 3.74
Kharushere	30-35	Femur only 167.6 ± 3.94	166.0 ± 3.74
Nesi-Amun	50	Fibula only 166.5 ± 3.86	Tibia only 166.6 ± 4.0
Neferi	25-30	166.93 ± 3.62	166.37 ± 3.74
Ta Sheri en Isset	30	189.46 ± 3.62	189.56 ± 3.74
Irti Rutja	30-35	169.42 ± 3.62	169.4 ± 3.74
Esmin	40-45	174.66 ± 3.62	174.69 ± 3.74

Table 1 - Human Mummy.

previous work of Boyd and Trevor (1953), Dupertuis and Hadden (1951), Keen (1953,1955) and Pearson (1899). We were able to determine the cause of death in two of our

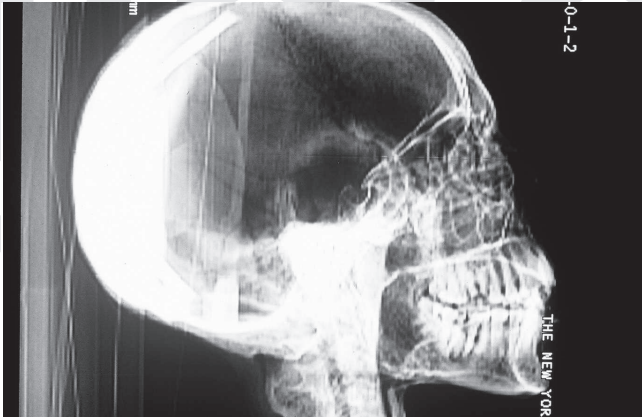


Fig. 1 - The abscess in Neferi's jaw eroded into the bone with subsequent septicemia and death.

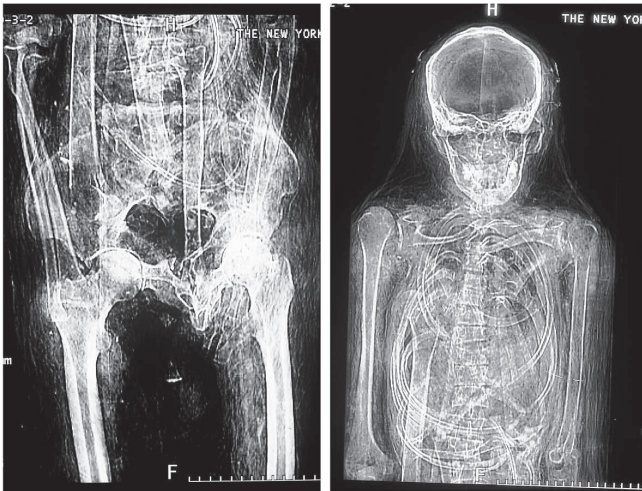

Fig. 2 - Nesi Amun's fractured left humerus, with callus, and the fractured pelvis with extraneous papyrus rods in the spinal region.



Fig. 3 - The encaustic painted wood panel portrait juxtaposed with the essentially identical portrait reconstructed from the CAT scan images.

portrait, well within the limitations of the technique used (Fig. 3). Fortunately we had the mummy and the portrait together, not a common happenstance, so we are able to state with complete confidence that in the case of this individual the painted panel is indeed a true portrait. The dramatic findings in Esmin (MMA 86.1.51) highlight the advantages of the "virtual unwrapping" that can be

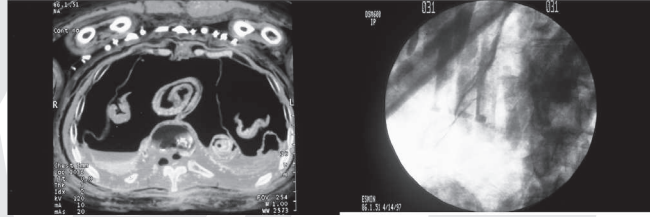


Fig. 4 - One of the two necklaces of amulets found in Esmin's wrappings along with a detailed image of some of the amulets.

accomplished with modern technology. Esmin was a 45-50 year old man who lived during the Ptolemaic period (332-30 BC). His well preserved bones are seen and his internal organs have been removed, wrapped in linen and returned to the abdominal cavity. There are two necklaces of amulets lying on his chest (Fig. 4). The lower necklace has thirteen amulets and the upper one has ten amulets. Close up, detailed images of these amulets were made using a C-arm. At the time these images were being made Isabel Stunkel, an Egyptologist from Germany and an expert on amulets, was a visiting scholar at The Metropolitan Museum of Art. From our images she was able to identify all the amulets but one.

## Discussion

Our investigations enabled us to determine the age, sex, height, anatomy and to a significant extent the pathophysiology of the individuals in our study group. Technology transfer brought the methods of medical science to the study of these ancient individuals without disrupting the mummies or violating their integrity. These mummies are human remains and need to be thought of and respected as such. Our procedures strike a balance between the desire to learn as much as possible and the unique and delicate nature of the material.

Radiological imaging of Egyptian mummies began almost as soon as the technique was available. In 1898 WMF Petrie, a pioneer Egyptologist, applied this new technology to mummies he had excavated (Petrie 1914). Individual mummies were studied by Bernassi and Ragni (1973), Bridgman (1967) and Danforth (1930). A group of 20 mummies in the Turin museum was surveyed by Delorenzi and Mancini (1973). Gray (1973) compiled the radiographic findings in 193 mummies. A special group, the royal mummies, was studied by Harris and Wente (1980).

Individual and groups of mummies have been studied with CAT scanning by Baldock and Hughes (1994), David (1979), David and Tapp (1992), Davies (1993), Germer (1997), Jack (1989) and Lupton (1988).

Our study group is somewhat unusual in that we were able to determine the cause of death in two of the individuals. Finding and identifying the necklaces of amulets was good luck and an uncommon event. Mummies with healed fractures, as seen in Nesi Amun, have been reported by Jones (1980), Ruffer (1921) and Salib (1962). Ruffer (1921) also discusses a mummy in whom the rib of a palm leaf was used as a stent to the spine and overall stabilization for collapsed vertebrae. This latter situation is analogous to the use of the

Cyperus papyrus stalk and the extraneous bones in Nesi Amun.

An evolutionary reduction in tooth size and complexity with selection for caries resistant teeth is manifest by the simpler fissure patterns of the teeth (Greene 1972). Oral hygiene was practiced only sporadically and operative dentistry was extremely uncommon. This scenario might account for Neferi's abscess and the subsequent septicemia. There is some evidence for possible root canal work and the placement of prostheses (Asbell 1948).

The amulets found comprising the two necklaces on the mummy of Esmin, like other amulets, were believed to derive their magical qualities from their form, color and material.

They could have an apotropaic function (protection or aversion), function by assimilation (assumption of the attributes of the figure represented) or as a votive offering. The material of the amulet was itself symbolic with jasper (red or yellow) equated with dynamism, feldspar (green) representing new life and lapis (indigo) conjuring up the night sky and delight (Andrews 1994, Petrie 1914).

Our Fayum portrait mummy is part of the practice of its time, which included making portraits of the deceased as part of the funerary ritual. The shapes of the panels used vary according to the town or region of origin. An individual's portrait usually was painted on a panel reflecting his hometown, regardless of where he was buried. The mummy was often kept at home for an extended period before burial, with the portrait being an important feature of this presence (Corcoran 1995). The concept of the mummy still being with the family is exemplified by the mummy's presence at the funeral banquet table (Borg 1997). Other attempts to use CT scan images to reconstruct a likeness of the individual have been made by David (1979), Filer (1997), Fleming et al. (1980) and Germer (1997).

## Acknowledgments

I am indebted to Dr. Dorothea Arnold, curator in charge of The Department of Egyptian Art, The Metropolitan Museum of Art, and her staff for their assistance and support. This study could not have been completed without the knowledge and skills of Drs. R. Freiburger, S. Behrman, M. Deck and D. Sostman as well as Mr. E. Perez and the other members of the Department of Radiology at The New York Hospital. The generous technical support of Philips Medical Systems, General Electric and Eastman Kodak is also gratefully acknowledged.

## Literature Cited

- Andrews C. 1994. Amulets of Ancient Egypt. London, British Museum Press.
- Asbell M. 1948. The dental art of ancient Egypt. Outlook and Bulletin. Southern Dental Association. 17: 124-26.
- Baldock C, and Hughes SV. 1994. 3-D Reconstruction of an Ancient Egyptian mummy using x-ray computer. J Roy Soc Med 87:806-8
- Benassi E, Ragni G. 1973. The amount of information that can be derived from the radiographic study of mummies as exemplified by a mummy from the late Ptolemaic period. J Hum Evol 2: 47-8
- Borg B. 1997. As dead as a guest at table? Continuity and change in the Egyptian cult of the dead. In: Bierbrier ML. ed. Portraits and Masks: Burial Customs in Roman Egypt. London. British Museum Press.
- Boyd JD, Trevor JC. 1953. Problems in reconstruction: Race, sex, age and stature from skeletal material. In: Simpson K. ed. Modern Trends in Forensic Medicine. London, Butterworth and Co. Ltd.
- Bridgman CF. 1967. A mummy comes to life. Science on the March. 49:20-2
- Corcoran LH. 1995. Portrait Mummies from Roman Egypt (I-IV Centuries AD) With a Catalog of Portrait Mummies in Egyptian Museums. The Oriental Institute of The University of Chicago, Chicago.
- Danforth MS. 1939. Report on X-ray films of an Egyptian mummy. Bull Mus Art R I School Des. 27:36-7
- David AR. 1979. Ed. The Manchester Museum Mummy Project: Multidisciplinary Research on Ancient Egyptian Mummified Remains. Manchester; Manchester University Press.
- David AR, Tapp E. 1992. The Mummy's Tale. In: The Scientific and Medical Investigation of Hatsef Amun, Priest in the Temple of Karnak. Michael O'Mara Books Ltd. London
- Davies WV, Walker R. 1993. Biological Anthropology and the Study of Ancient Egypt. London. British Museum Press.
- Delorenzi E, Mancini M. 1973. Radiological Observations on the Mummies in the Egyptian Museum, Turin. J Hum Evol 2: 49-50
- Dupertuis CW, Hadden JA. 1951. On the reconstruction of stature from long bones. Am J Phys Anthropol. 9: 15-44
- Filer J. 1997. If the face fits. A comparison of mummies and their accompanying portraits using computerized axial tomography. In: Bierbrier ML. Portraits and Masks: Burial Customs in Roman Egypt. London. The British Museum Press.
- Fleming S, Fishman B, O'Connor D, Silverman D. 1980. The Egyptian Mummy. Secrets and Science. Philadelphia. University Museum. University of Pennsylvania.
- Germer R. 1997. Life After Death in Ancient Egypt. F. Elliot. transl. New York, Prestel
- Gray PH. 1973. The radiography of mummies of ancient Egyptians. J Hum Evol. 2:51-53
- Greene DL. 1972. Dental anthropology in early Egypt and Nubia. J Hum Evol. 1:315-24
- Harris JE, Wente EF. 1980. Eds. An X-ray Atlas of the Royal Mummies. Chicago. University of Chicago Press.
- Jack LA. 1989. A Mummy Revealed – The Faces of Djed. Rotunda, The Magazine of The Royal Ontario Museum
- Lupton C. 1988. Mummies are Forever. Milwaukee Public Museum, 38:3-8
- Jones FW. 1980. Some lessons from ancient fractures. Br Med J. 281:455-8 (letter)
- Keen EN. 1953. Estimation of stature from the long bones. A discussion of its reliability. J Forensic Med. 1:46-51
- Keen EN. 1955. Estimation of stature from the long bones. J Forensic Med. 2:190-1 (letter)
- Pearson K. 1899. IV. Mathematical contributions to the theory of evolution; Part V: On the reconstruction of the stature of prehistoric races. Philo Trans R Soc, Series A. 92:196-244
- Petrie WMF. 1914. Amulets. London. Constable and Co. Ltd.
- Ruffer MA, Moodie RL, Eds, 1921, Studies in the Paleopathology of Egypt. Chicago. University of Chicago Press
- Salib P. 1962. Orthopedic and traumatic skeletal lesions in ancient Egyptians. Br J Bone Joint Surg. 44:944-7
- Tackholm V, Drar M. 1950. Flora of Egypt. Cairo. Fouad I University Press, vol. II, Bulletin of the Faculty of Science. No.28
- Trotter M, Gleser GC. 1952. Estimation of Stature from long bones of American Whites and Negroes. Am J Phys Anthropol. 10:463-514