

# A Titicaca Mummy Bundle and an Atacameño Mummy in the Collection of the National Museum at Rio de Janeiro, Brazil

Veronica Wesolowski<sup>1</sup>, Claudia Rodrigues-Carvalho<sup>2</sup>, Debra K. Meier<sup>3</sup>

<sup>1</sup> ENSP/FIOCRUZ, Brazil (wesowski@woc.com.br)

<sup>2</sup> Museu Nacional/ UFRJ, Brazil

<sup>3</sup> Teaching, Learning & Teacher Education-University of Nebraska, USA

KEY WORDS: South American mummy, dental disease, mummy conservation.

## Abstract

**At the beginning of the last century, scientific missions visited neighboring countries. These missions resulted in the exchange of archaeological and ethnographical collections, and improved the National Museum exhibitions of Peruvian and Chilean materials. A well preserved bundle was excavated from a chullpa, or stone tomb of the Titicaca Lake region. It is one of the best preserved mummies in our collection. Inside a specially coiled basket is a man sitting exhibiting annular skull deformation and interesting dental decay, possibly associated with coca chewing. Another very well preserved body with genitals comes from an Atacameño burial. A wool cap identifies his cultural affiliation. This second man was unearthed in a tomb in Chiu-Chiu, north of the Atacama desert in Chile, and shows signs of trauma in the face. A comparison of the different conditions that helped preserve the two mummies and their cultural and biological characteristics will be presented here.**

## Introduction

The National Museum of Rio de Janeiro was founded in 1818. Today it is an important research institution regarding several knowledge areas. The museum's collections are extremely diversified. Part of the collections contain archaeological and anthropological pieces from Brazil and from other parts of the world.

Among the pieces of the archaeological and anthropological collection, there are several mummies. Two of these mummies are from the west of South America

(Bolivia and Chile). They were donated to the museum collection in the second half of the XIX century. At this time, these mummies are under a "rediscovery" process and the purpose of this paper is to organize and provide information about the current research. This research is in its preliminary stage, so the information being presented is mainly descriptions of findings.

## Aymara mummy

The Aymara male mummy is from Alto Peru (Bolivia). The individual's age of death is between 30 and 40 years old. (Conselho Administrativo do MN, 1861). This mummified body was donated to the National Museum of Rio de Janeiro, in 1881, by Frederico Puga Boene, director of the Valy Paraíso Museum.

The body is from a Chulpa. It is surrounded by a fiber bundle coiled around the deceased, leaving apparent the feet and face. The head is now uncovered as a consequence of the destruction of the upper part of the basketry (Fig. 1). In general the preservation of this mummy is good. Insect damage can be seen at the scalp, where the skin is partially destroyed, contrary to the rest of the body, where the macroscopic tissue integrity is maintained.



Fig. 1 - Aymara mummy, frontal view. Photo by V. Wesolowski.

There are several visible pathological and cultural modifications of the mummy. The head shows circumferential binding deformation (Buikstra & Ubelaker, 1994), commonly found on mummies from this geographic region. Alveolar abscesses are present in the first upper left molar and in the second lower left molar. Extensive cavities are found in these same teeth. At the vestibular part of the right maxilla, there is a huge area of cortical bone destruction along the molars and pre-molars. There isn't any outer cortical bone left and the inner cortical bone is partially affected. The alveolar bone has been destroyed and the first molar, second molar and second premolar were lost (Fig. 2) The right upper incisors are dislocated, probably because of the compression caused by this expansive lesion. There is moderate dental wear and bone retraction along the upper and lower alveolar arches indicating periodontal disease.

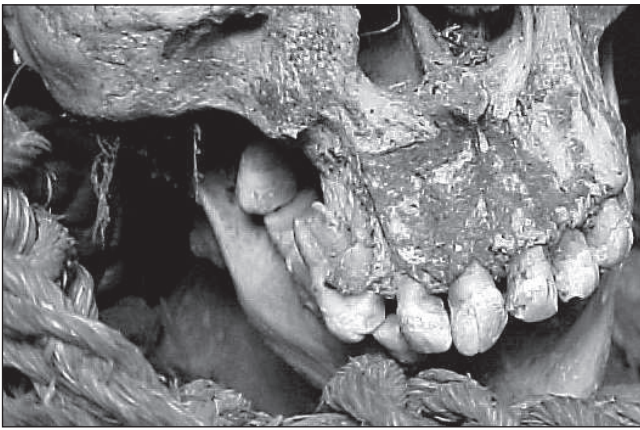


Fig. 2 - Destructive lesion in right maxilla. Photo by V. Wesolowski.

### Atacameño mummy

According to administrative documents this mummified body was donated to the National Museum, Rio de Janeiro, by Antônio Pedro de Carvalho Borges in 1866.

This male mummy is from the Chiu-Chiu site in the Atacama Desert, Chile. At the time of his death he was between 30 to 40 years old (Fig. 3). According to documents, this body was associated with three bags: one made in wool containing maize, another made in leather containing chewing paste, and the third one, made in an unidentified material, containing poison and some goods for weaving. The objects could not be found in the collection at this time.

The preservation of this mummy is also good. There are signs of past insect damage but the tissue integrity is maintained in most of the body which is still completely covered by the skin. Hard stable efflorescence crystals (crystalline deposit) formed along parallel lines on the surface of the skin, all over the body. Marks of the textiles that originally enveloped the body, can still be seen on the well preserved skin.

A few osteological observations were made. The vertical occipital flattening of the head suggests intentional skull deformation (Buikstra & Ubelaker, 1994) that is also

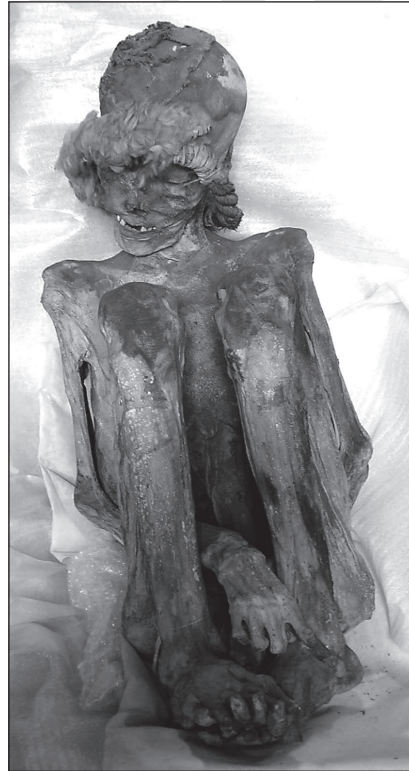

Fig. 3 - Atacameño mummy, frontal side view. Photo by V. Wesolowski.

common in the Atacama Desert. The stature of the individual was calculated from humerus (158,23 m), tibia (161,99m), femur (158,57m) and femur + tibia (160,28) measurements (Trotter & Glesser, 1958). The dentition couldn't be observed by visual inspection due to integrity of the lip tissue. No signs of disease can be seen in the mummy's skin. There was a lesion in the left molar region that strongly suggests a traumatic injury etiology, but this can't be x-ray scanned yet. (Fig. 4).




Figure 4 - Probably traumatic injury at left molar bone. Photo by V. Wesolowski.

Sampling different materials from the bodies, CT scanning, and also endoscopic exams are being planned to detail the scientific description of both mummies.

Controlled atmosphere bubbles are being prepared to assure their preservation in the tropical climate of Rio de Janeiro.

## Conclusions

Many museums around the world had often underutilized old anthropological collections. These collections, if analyzed with new attention and techniques, can provide new data. These data, if combined with other information, can improve our knowledge about ancient diseases and mortuary practices. Our objective with these descriptions of the findings was to give biographic information about these two mummies and also call the attention to the potential of studies regarding old museum collections.

## Literature Cited

- Conselho Administrativo do MN. 1861. Registro das Actas do Conselho Administrativo do Museu Nacional n. 1, Acta de 4/3/1881.
- Buikstra JE, and Ubelaker DR. 1994. Standards for data collection from human skeletal remains. Arkansas Archaeological Survey Research Series, n. 44. Fayetteville: Arkansas Archaeological Survey.
- Trotter M, and Glesser GC. 1958. A re-evaluation of estimation of stature based on measurements of stature taken during life and long bones after death. *Am J Phys Anthropol* 16: 79-123.