

Forensic Anthropological and Pathological Analysis of the Guanche Mummies From Necochea (Argentina)

Conrado Rodríguez-Martín¹, Ricardo Guichón², Nora Flegenheimer², Mercedes Martín Oval¹

¹ Instituto Canario de Bioantropología, Organismo Autónomo de Museos y Centros-Cabildo de Tenerife

² CONICET-República Argentina

KEY WORDS: Guanche, Canary Islands, mummies, forensics, pathology

Abstract

The two Guanche mummies sold to Argentinean businessmen at the end of the 19th century are known as NEC-1 and NEC-2. NEC-1 is a young female, very gracile, showing severe stress markers. NEC-2 is a young male, tall and robust for the time in which he lived, and shows a lethal lesion in the skull with a trephination in the base. In this paper we present the most prominent forensic anthropological data of both mummies, as well as the pathologies observed, the differential diagnosis of the lesion in NEC-2, and the possible causes of death of both individuals along with the methods used in these studies.

Introduction

Two Guanche mummies coming from the former Casilda Museum (Tacoronte, Tenerife, Canary Islands, Spain) sold to a group of Argentines at the end of the XIXth century (Rodríguez-Martín, 1995) were repatriated by the municipal authorities of Necochea (Province of Buenos Aires, Republic of Argentina) to Tenerife in September 2003. An interdisciplinary team performed analyses of these specimens in order to know state of preservation after a century out of the archipelago, exact geographic origins, mummification type, physical characteristics, diet, nutritional status, and pathological findings. The mummies were labelled NEC-1 and NEC-2 being NEC the abbreviation of Necochea.

Forensic anthropological study

A classical physical examination based in naked-eye and radiographic examination was carried out showing the following findings:

Anthropological data NEC-1

This mummy came from Güimar (southern slope of Tenerife), the sex is female and is aged in the interval 20-24. The estimated stature is 137 cms, far from the female mean stature for the Guanche females that is estimated around 158-160 cms (García-Talavera, 1995). The robustness is minimal

Mummification type: typical Guanche type (anthropogenic with sun / smoke exposing, external treatment with plants and ointment, corpse covered by animal skins, without organs removal) (Estévez, 1995).

The state of preservation is rather good and its chronology (radiocarbon dating) is 1150 BP.

Other data characterizing this specimen are: several bones of at least two other skeletons are observed inside the "fardo" (a group of them belongs to a young-adult female with a stature of 140-143 cms and the second group are of an adult male, 170-172 cms).

Anthropological data NEC-2

The origin of this specimen is located in the municipality of La Orotava, in the site so-called Arautapala belonging to the prehispanic menceyato (kingdom) of Taoro (northern slope of Tenerife).

The mummy was sexed as male and aged between 25 and 29 years at the moment of death. Physical features were an estimated stature between 172-173 cms (1-2 cms taller than the mean Guanche stature for males, García-Talavera, 1995) and a medium robustness.

The mummification method was the typical Guanche type (anthropogenic, described above).

The state of preservation was stated as poor (in comparison with the photographs taken before it was sold to Argentina at the end of the XIXth century). Some remains of lung and pericardial tissues were found inside the thoracic cavity during the autopsy.

Chronology (radiocarbon dating): 1000 BP

Other data observed during the examination of NEC-2 were: lower limbs flexed at the level of the knees. This was an absolutely uncommon finding in a Guanche mummy prior to the study of this specimen.

Chemical dietary reconstruction

Stable isotope analysis were carried out in the Estación Experimental del Zaidín, Centro Superior de Investigaciones Científicas (Granada, Andalucía, Spain) and the Paleobiology Laboratory at the Department of Pathology (School of Medicine, University of Minnesota, Duluth Campus). Both mummies presented high N15 content what is consequence of animal proteins contributing highly to diet (+ 70%).

If we perform a comparison with the Guanche population it is possible to note that, in general, Guanche mummies show the same N15 value than the mummies repatriated by the Municipality of Necochea, meanwhile comparison with the Guanche skeletal population varies depending of the place in the island: NEC-1 and NEC-2 show 20% more than the skeletal population in the northern slope and 5-10% more than in the southern slope (Aufderheide et al., 1995; Tieszen et al., 1995).

Pathological study

The radiographic examination (flat radiology and CT scanning) and the autopsy performed on these specimens showed the following pathological findings:

Nec-1

Radiology: apparent postmortem fracture in the posterior part of the skull. Bones of other two individuals inside. No pathological data observable.

Dental study: enamel hypoplasia, calculus in the anterior teeth and dental attrition (2-6 Patterson grades).

Cause of death: unknown

Nec-2

Radiology:

Flat X-Rays:

- The left frontal sinus was involved by a pathological process (sinusitis?) and the left temporal bone shows a probable osteolytic lesion.

CT Scan:

- Schmorl nodes were seen in the thoracic and lumbar spine.

- A huge osteolytic process, triangular in shape, involving almost the whole anterior half of the left temporal bone was clearly seen, specially with 3D cranial reconstruction.

Pathology:

The temporal osteolytic lesion shows punched out appearance.

Dental study:

Antemortem fracture of the left lower central incisor and postmortem fracture of the right central incisor were detected in the dental study, as well as calculus in the whole maxillary teeth and lower incisors, canines and first premolars. Slight attrition (1-3 degrees of Patterson) is present in both jaws (anterior teeth).

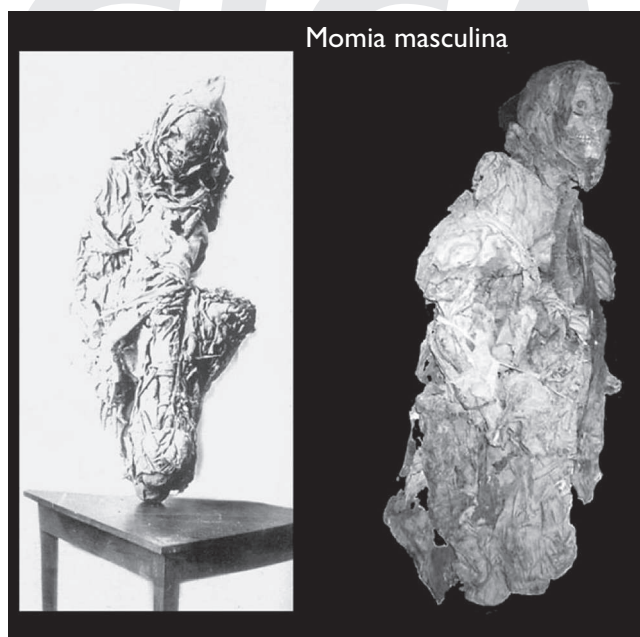


Fig. 1 - Male mummy (NEC-2). XIX century photograph in comparison with the present state of preservation

Cause of death:

The cranial lesion.

Differential diagnosis of the osteolytic cranial lesion: Malignant skin tumour (malignant melanoma and basal cell carcinoma): these tumors normally appear in persons over 50 years, specially those with high degrees of sun exposure. Metastases are scarce and show long evolution. However, basal cell carcinoma is very invasive in the surroundings of the lesion (Robbins, 1975).

Plaque meningioma: this tumour is highly destructive and may destroy most of the cranial vault (Lichtenstein, 1977), however is of slow evolution.

Skeletal malignant tumours (osteosarcoma, Ewing's sarcoma, skeletal lymphogranulomatosis, solitary plasmocitoma, and malignant meningioma of the sphenoid). Osteosarcoma is very uncommon in the skull and always show some osteoblastic reaction (Aegerter and Kirkpatrick, 1975). Ewing's sarcoma is very uncommon too in the skull, it shows the typical onion skin pattern, and never produce such a destruction in the bone (Schinz et al., 1953). The pathological and radiological patterns of skeletal lymphogranulomatosis, solitary plasmocitoma, and malignant meningioma of the sphenoid are rather different than that observed in our case.

Skeletal benign tumours (chondromyxoid fibroma): although this tumor affects persons in the second and third decades of life (Revell, 1986) and is very destructive, it is very uncommon and shows slight bone reaction and sclerosis in the margins of the lesion, features that are absent in NEC-2. Very few cases involving the skull are described in the medical literature (Aegerter and Kirkpatrick, 1975; Resnick and Greenway, 1998). Other tumours and tumour-like conditions (dermoid and epidermoid tumours, lymphoma). Although dermoid and epidermoid tumours show a punched out appearance, they are typical in individuals older than 40 years.

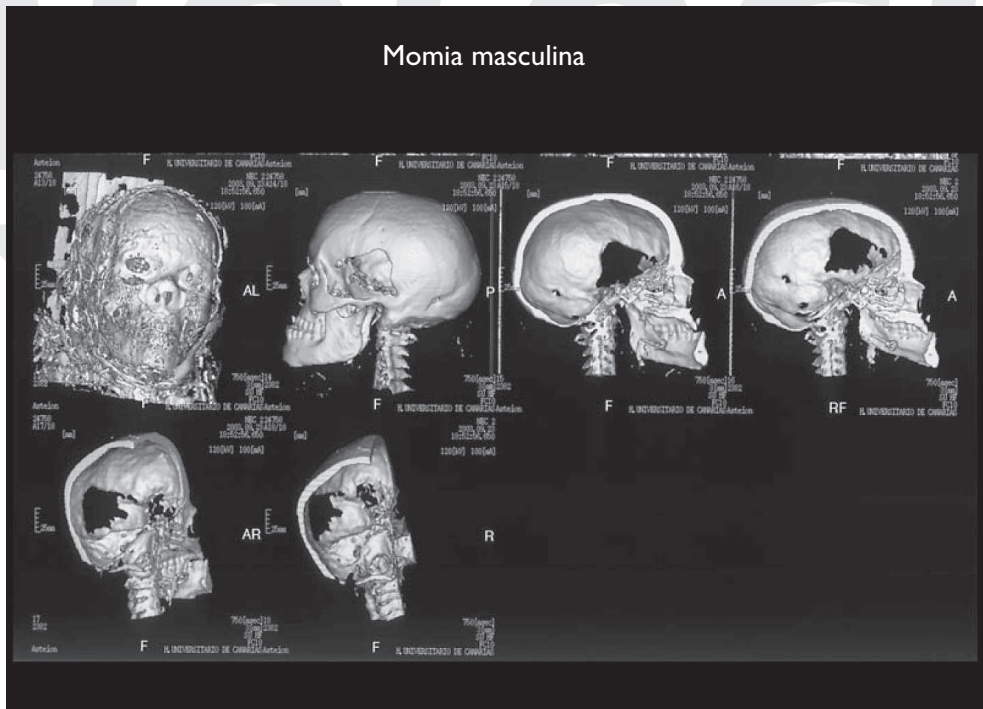


Fig. 2 - Skeletal 3-D reconstruction of the cranial lesion of NEC-2.

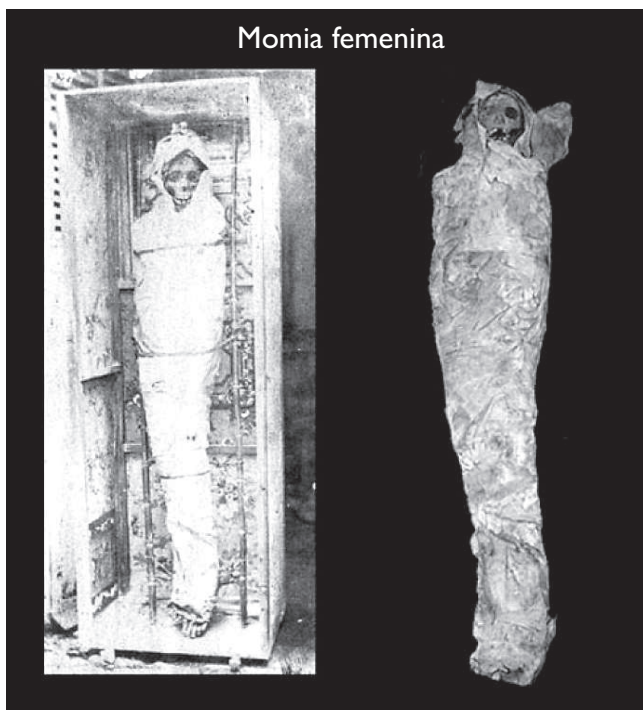


Fig. 3 - Female mummy NEC-1. XIX century photograph in comparison with the present state of preservation.

Sarcoidosis: this condition appears in adults between 20 and 40 years of age and involves the face more than the skull showing osteolytic pattern (Resnick, 1998), although it is very uncommon and of long evolution.

Histiocytosis-X (eosinophilic granuloma): it is almost exclusive of persons younger than 20 years, showing well limited margins (Aufderheide and Rodríguez-Martín, 1998). It is not malignant in nature.

Osteolytic metastatic carcinoma: these types of tumours are typical of older persons and never show the huge

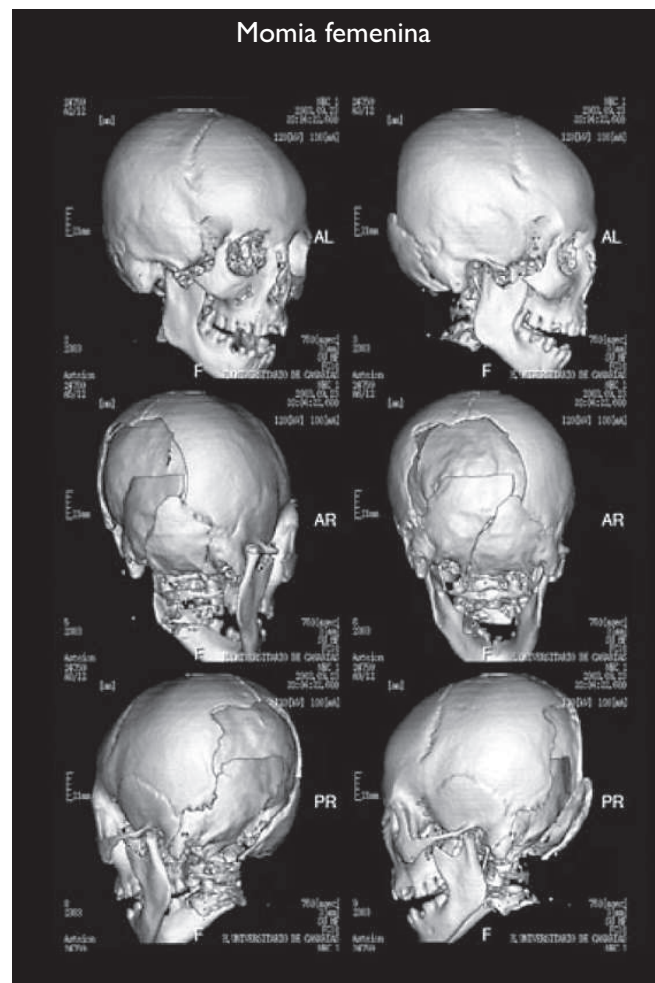


Fig. 4 - 3-D skeletal reconstruction of the skull of NEC-1.

destruction observed in this case (Aufderheide and Rodríguez-Martín, 1998)

Infection (sinusitis, bacterial meningitis, TB, extradural abscess, temporal abscess, and cranial osteomyelitis): of all the infection mentioned here only sinusitis with temporal abscess development is a plausible cause of the lesion.

Probable diagnosis

After performing a differential diagnosis between the conditions mentioned in the previous paragraphs, in our opinion, the most probable diagnosis of the lesion responsible of the death of NEC-2 is sinusitis involving the left temporal bone. Temporal abscesses are usually produced by sinusitis involving the frontal sinus (as occurred in this case) or mastoiditis (Carnevale et al., 1971). The evolution is very fast and acute with suppurating encephalitis and there is no spontaneous solution without medical or surgical treatment (Robbins, 1975). The most common involved bacteria are: staphylococci, streptococci, and pneumococci, being Gram + and anaerobic bacteria less common than the previous.

Literature Cited

- Aegerter E and Kirkpatrick JA. 1975. Orthopedic diseases. Physiology, pathology, radiology. 4th ed. Philadelphia:WB Saunders.
- Aufderheide AC and Rodríguez-Martín C. 1998. The Cambridge Encyclopedia of Human Paleopathology. Cambridge: Cambridge University Press.
- Aufderheide AC, Rodríguez-Martín C, Estévez F and Torbenso M. 1995. Chemical dietary reconstruction of Tenerife's Guanche diet using skeletal trace element content. Actas del I Congreso Internacional de Estudios sobre Momias (Museo Arqueológico de Tenerife-OAMC-Cabildo de Tenerife), Vol. I: 33-40.
- Carnevale V, Comolli E, and Casiraghi JC. 1971. Patología quirúrgica del sistema óseo. In Michans JR (ed.): Patología quirúrgica. Buenos Aires: El Ateneo, vol. II: 404-477.
- Estévez F. 1995. El estudio de las técnicas de momificación aborígenes en la historia de la antropología canaria. Actas del I Congreso Internacional de Estudios sobre Momias (Museo Arqueológico de Tenerife-OAMC-Cabildo de Tenerife), Vol. I: 59-64.
- García-Talavera F. 1995. La estatura de los Guanches. Actas del I Congreso Internacional de Estudios sobre Momias (Museo Arqueológico de Tenerife-OAMC-Cabildo de Tenerife), Vol. I: 177-186.
- Lichtenstein L. 1977. Bone tumors. 5th ed. Saint Louis: Mosby.
- Resnick D. 1998. Sarcoidosis. In Resnick D (ed.): Huesos y articulaciones en imágenes. 2^a ed. Madrid: Marbán, p. 1189-1195.
- Resnick D and Greenway GD. 1998. Tumores y lesiones pseudotumorales de los huesos: imágenes y anatomopatología de las lesiones específicas. In Resnick D (ed.): Huesos y articulaciones en imágenes. 2^a ed. Madrid: Marbán, p. 991-1063.
- Revell PA, 1986. Pathology of bone. Berlin and Heidelberg: Springer-Verlag.
- Robbins, SL. 1975. Patología Estructural y funcional. 1^a ed. es. Madrid: Interamericana.
- Rodríguez-Martín C. 1995. Una historia de las momias Guanches. Actas del I Congreso Internacional de Estudios sobre Momias (Museo Arqueológico de Tenerife-OAMC-Cabildo de Tenerife), Vol. I: 151-162.
- Schinz HR, Baensch WE, Friedl E, and Uehlinger E. 1953. Röntgen-Diagnóstico. 5^a ed. Barcelona: Salvat.
- Tieszen L, Matzner S, and Buseman SK. 1995. Dietary reconstruction based on stable isotopes (¹³C, ¹⁵N) of the Guanche, pre-hispanic Tenerife, Canary Islands. Actas del I Congreso Internacional de Estudios sobre Momias (Museo Arqueológico de Tenerife-OAMC-Cabildo de Tenerife), Vol. I: 41-57.