

Autopsy of the mummy of "Fin-Renard", Bourges, (France)

Pierre Thillaud¹, Yves Glon², Philippe Charlier³, Jean-Noel Vignal⁴

¹ School High Studies, Sorbonne, Paris. France

² Radiological Medicine, Paris. France.

³ Service of Pathological Anatomy and Citology, Lille. France.

⁴ Institute of Criminal Research of the Police, Fort de Rosny-sous-Bois. France.

KEY WORDS: Paleopathology, Mummy, Gallo-roman, Bourges(France)

Abstract

Discovered in 1908 in a lead coffin conserved in a stone sarcophagus, the mummy of the "Fin-Renard" from Bourges, central France, was immediately identified as that of a gallo-roman child. The circumstances of his death as the extraordinary conservation of his body were the object of many conclusions related to contemporaneous medico-historical knowledge and limited by partial investigation potentiality. The preparation of the exhibition *Maternité et petite enfance dans l'Antiquité Romaine* ("Maternity and childhood in Roman Antiquity") presented at the Museum d'Histoire Naturelle at Bourges in 2003/2004 necessitated the re-examination of the body. The application of the most actual paleopathological methods and techniques permitted a more precise observation of this unique but surprising French specimen. However, after many radiographic, scannographic, fibroscopic and microscopic studies, the little mummy conserves many of its mysteries

On the 15th of September 1908, in a place called Fin-Renard in Bourges (France), some men found a stone sarcophagus containing a lead coffin with the mummified body of a child dating from Gallo-roman time. For unknown reasons, they played soccer with the corpse and fractured limbs and neck. As a matter of fact, now are still remaining the trunk, the right hand and some various fragments (a piece of head, face and right arm). Due to the organization of the exhibition *Maternité et petite enfance dans l'Antiquité romaine* at Bourges in 2003, the *Musée du Berry* remembered this exceptional mummy and asked Thillaud and al.(2003, 2004) to study it.

The sex of the child is undoubtedly male, according to macroscopic examination with a base-fractured penis. Due to the absence of intact long bone, the determination of age at death is difficult. Medical imaging helped us a lot. A conventional radiography of the right hand showed the post-mortem destruction of the distal extremities of both radius and ulna, but also of the first carpal line. Two bones were present on the second carpal line. The capitatum and the hamatum were partly modeled. A trapeze was ossified, as the epiphyses of metacarpal bones and phalanges. According to classical data on the skeletal development, the child could be dead at an age comprised between 2 years and 5 months and 5 years. The TDM images of epiphysis points taken of the left humeral bone give an age superior to 2 years. The absence of an ossification center on the right lesser trochanter indicates an age at death inferior to 3 years. This child could be dead around 2 years and a half. This conclusion goes with the total length of the coffin measuring 100 cm, as male child of 2,5 years are now 90,2 +/- 3,2 cm tall.

The general aspect of the trunk and, particularly the ochre and white deposit covering the superior part attracted the first archaeologist since 1910 (they thought it could be an Egyptian-like technique of embalming). In fact, after a serious cleaning of the trunk, we saw that the surface of thoraco-abdominal, dorso-lumbar and scapular region presented two different aspects (Fig. 1). The first one, grayish, corresponding to the epidermis. The second, a white and hard one, covered in many parts the first one; it was composed essentially with lead and charcoal. The mummification was indeed performed by the interaction of the coffin-charcoal-charged water with the lead coffin and the secondary deposition on the dead body. The extremely well-limited white deposit in the lumbar region may reflect the presence of a shirt which tissue was impregnated with time by lead and charcoal.

According to radiographic images taken in 1985, a Pott's disease was diagnosed on the 6th thoracic vertebra (T6). The year later, thanks to a TDM exam, this diagnosed was changed into a vertebral bone tumor that could be the cause of death. New images were performed and showed the absence of the T6 body but the presence of the posterior arch (Fig. 2). Using a fiberscope, we examined the thoracic cavity and revealed the perfect conservation of the 5th and 7th thoracic vertebrae (T5 and T7)... and the



Fig. 1 - On this view of the back-face of the trunk, after cleaning, one may observe: brown zones of exposed skin; other zones covered by a white coat made of chalky and lead, with origin comes from the chemical particularities of percolation waters and deposited at the surface of the body.

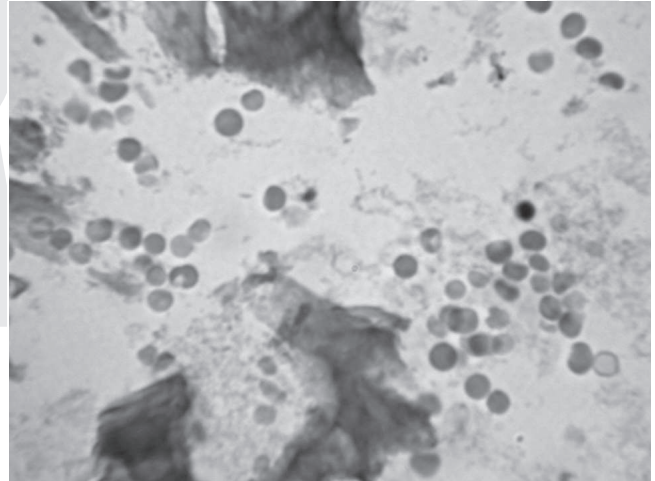


Fig. 3 - On this histological preparation of the left temporal bone (x 450), we may distinguish a focus of red blood cells with their characteristics: intense red colour and biconcave form. Two erythroblasts with their dense nucleus are recognizable. No one parasite, nor haemoglobinopathy were observed.

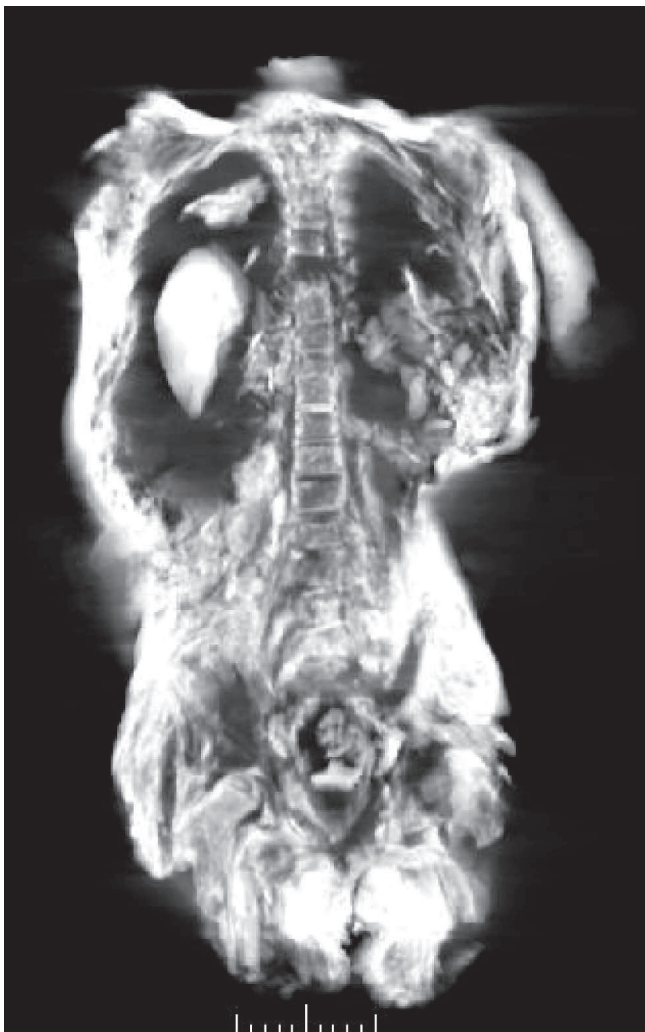

Fig. 2 - This bi-dimensional image of the trunk obtained by tomography is a frontal view. The vertebrae are in the center of the image, and one may distinguish easily the thoracic and lumbar parts of the spine with the absence of the body of the 6th thoracic vertebra.

presence of the 6th thoracic vertebra (T6) at the top of the right thoracic cavity! The only one explanation that could be given to such a post-mortem anomaly is the brutality of the exhumation (and funeral games...).

The absence of any superficial lesion that could explain the cause of death gave us some good reasons to perform some histological examinations. The microscopic visualization of cranial bone showed the presence of red blood cells and some well conserved lymphocytes (Fig. 3). Observed under polarized light, collagen fibers showed no anomaly. Their regular disposition indicated a normal and physiological growth. A part of the rectal cavity was studied and showed the preservation of all four digestive levels.



Fig. 4 - The hairs and, more precisely, the determination of the natural or not red colour engaged us to make complementary analysis. The exam under binocular lens showed an homogeneous coloration, sign of a probable natural colour.

Another slide interested part of neuro-vascular humeral group: were still visible the nerves and vascular structures, without any anomaly. Some hairs, and particularly their

fascinating red coloration, were studied under binocular and microscopic examination. The natural coloration was then confirmed (Fig. 4).

At the end of this paleopathological research, the body of the Fin-Renard conserves many parts of its secrets. The most frustrating could be the circumstances of death between 2 and 3 years old, for unknown reasons, because no-one lesion was identified on all the pieces. Everything indicates a harmonious growth. However, this little Gallo-roman boy was a real red-haired! Do we have to see in this originality the reasons of a so cautious inhumation? The answer to this question doesn't concern us but may

be given by historians. It shows very well the complementary of our two scientific disciplines.

Literature Cited

- Thillaud PL. 1996. Paléopathologie humaine, Sceaux: Kronos B.Y., 238p.
- Thillaud PL, Glon Y, Charlier P, Vignal JN. 2003. La momie gallo-romaine du Fin-Renard. In: Gourevitch D, editors. Maternité et petite enfance dans l'Antiquité Romaine. Bourges. Ville de Bourges. p 102-110.
- Thillaud PL. 2004. Les secrets de la momie de Bourges, enquête paléopathologique. *Hist Sci Med* 38 (3): 361-364.