

C.A.D. (Concept Aided Design) study of excerebration. Application to 20 Egyptian mummy heads from the Marro Collection (Turin)

Christophe Bou¹⁻², Philippe Pomar¹, Jacques Treil¹, Emma Rabino-Massa³, Georges Larrouy¹

¹ CNRS UMR 8555 Anthropobiologie. Toulouse - France

²Forensic Odontology. Faculty of Odontology. Bordeaux - France

³Department of Animal and Human Biology, University of Turin - Italy

KEY WORDS: CAD (Concept Aided Design), excerebration, Egyptian mummy - Turin

Introduction

With medical scanning evolution and 3D software reconstruction, we can realize for some time past non destructive anthropological studies over mummies (Bou et al. 1998; Bou et al. 1997)

This concept of «virtual reconstruction» is very interesting because during the last 150 years, many studies on egyptian mummies has been made by egyptologists and anthropologists, however works about distribution and spécific methodology of excérèbration are few (David, 1997; Harwood-Nash, 1979).

The art of mummification reached its height during Dynasty XXI (1085-945 BC).

The excerebration, a non constant process, was a tactful working, its frequency increase as far as Greek period with fifty per cent (Nicolaëff, 1930).

As already pointed out by studies, in the Middle kingdom the percentage of excerebration is small, and seems to be applied on upper social class (Strouhal, 1980) (Tab. 1).

According to Herodotus: “in the most expensive manner to embalm, first they draw out the brain through the nostril with an iron hook, taking part of it out in this manner, the rest by the infusion of drugs”.

Methodology of excerebration

Probably during the period of greatest technical expertise the brain was removed first

An opening was made with a «chisel through the nostril» by sphenoidal or/and ethmoidal way with often much damage to the facial skeleton (Macke, 1992) (Fig. 1).

According to Leek, then: “the task was achieved by passing hooks up the noose through the ethmoidal bone at the base of the skull into the cerebral substance which was disrupted and removed, possibly partly by postural drainage” (Leek, 1969).

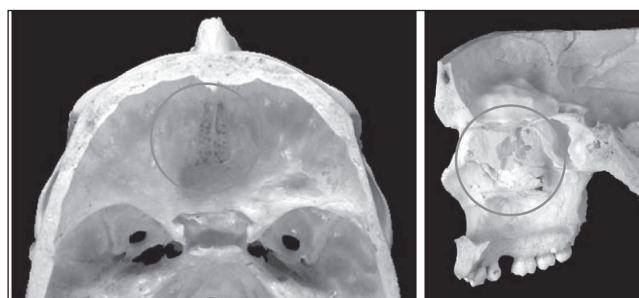


Fig. 1 - Ethmoidal bone.

This incomplete method involve the use of a irrigation method with acorrosive fluid in order to wash the brain out.

With excerebration, we realize that embalmers had a perfect knowledge of anatomy, and especially the weakness area at the base of the skull for ethmoidal and sphenoidal way.

The objective of this study is to assess the excerebration way of twenty egyptian mummy heads of the Turin Institute of Anthropology using a new concept of CAD (Concept Aided Design)

Methodology

We used computed tomography data (DICOM), personal computer, reconstruction software (AMIRA / C2000) and simulation software (AMAPI / 3DS) to study excerebration. In first time 2D axial, frontal and 3D reconstruction permit

Authors	Sample study location	Number	Excerebration (%)
Nicolaëff (1930)	Saqqarah/Thèbes	413	105 (23,2%)
Leek (1969)	Assouan	327	183 (56%)
Macke (1991)	Queen valley	135	84 (62%)
Strouhal E (1980)	-	4	4 (100 %)
Dunand/ Lichtenberg (1980)	Douch mummies	51	33 (65%)

Table 1 - Excerebration studies

us to visualize the shape and size of the way of excerebration when it exist., then a study more specific over the loss of substance can allow us to simulate the handling with a virtual hook of the embalmer. Study sample: Twenty mummy heads (Marro Collection) of the “Department of Animal and Human Biology. University of Turin (Italy)” (Rabino-Massa, 1997) (Fig. 2). The dating of this sample study would be the Middle Kingdom, from Assiut and Gebelein.

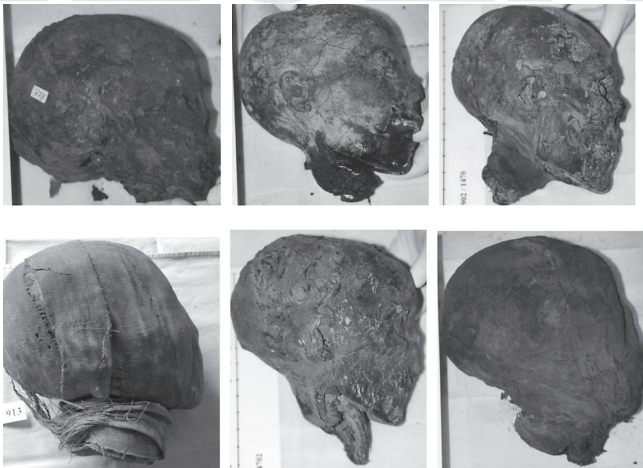

Fig. 2 - Mummy heads (Marro Collection / Turin).

Results

Our results show that over twenty mummy heads, eleven were excerebrated (55%), ten by ethmoidal way, one by occipital way.

This result of excerebration is surprising, very high, comparatively to another data for the same period.

The excerebration by ethmoidal way show a great variability of shape and size.

In the most common, embalmer choose the left nostril to perforate the cribriform plate of ethmoide bone, deflecting the nasal septum on the right (Fig. 3).

The destruction of ethmoid bone can be made in the front with an penetration axis more vertical. On the contrary a destruction made back part at the base of the skull, with destruction of sphenoid bone exist. In this case the penetration axis is more horizontal

It's exist a significant relationship between size and shape of the loss of substance, and the complete removal of the brain.

In order to realize an more complete analysis, frontal and sagittal 3D reconstruction allow us to visualize the excerebration way and above all the loss of substance (Fig. 4).

In a second time, with efficient tools of 3D reconstruction software, we realize in first time a segmentation of bone structure around the loss of substance of excerebration, then a virtual 3D reconstruction was made for each of them (Figs. 5-6-7).

It's also interesting to have more information about excerebration and over all the limits of mechanical action done by the hook of the embalmer, therefore we realize a segmentation of the loss of substance (Figs. 8-9).

In the next and final step, 3D virtual hooks were

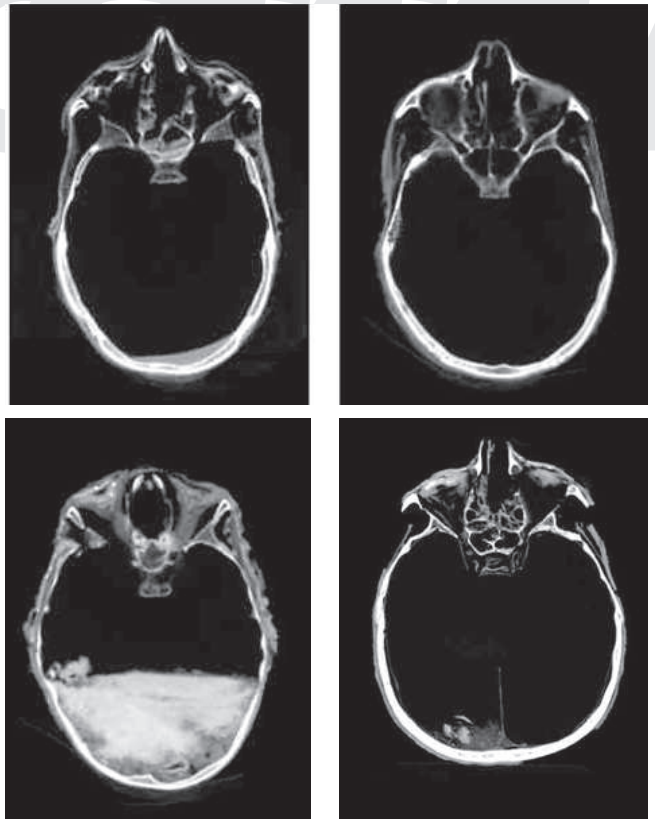


Fig. 3 - 2D axial excerebration way.

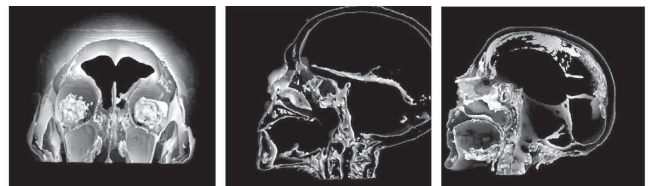

Fig. 4 - 3D frontal and sagittal excerebration way.




Fig. 5 - In this two sample, we can see a bilateral destruction, then lefthandedness to the ethmoid bone with preservation of perpendicular plate.




Fig. 6 - The excerebration of this head is very large on either side, destroying both ethmoid and sphenoid bone.

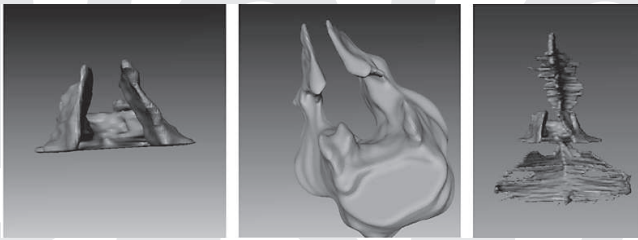


Fig. 7 - Excerebration with global anterior destruction. The limited access mode can explain the presence of the falx of the brain (Segmentation and 3D reconstruction).

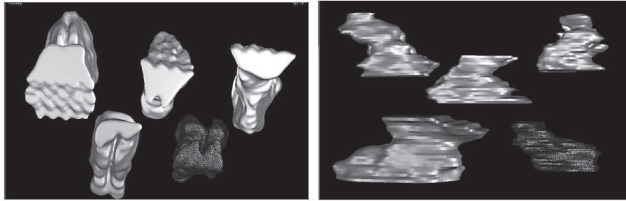


Fig. 8 - Segmentation and reconstruction of loss of substance at the time of excerebration.

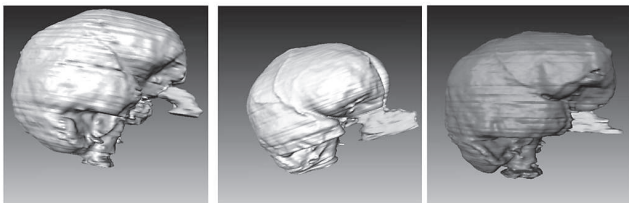


Fig. 9 - 3D reconstruction of the loss of substance with the brain.

manufactured according to size and shape of Egyptian tools (Fig. 10).

Respecting shape and size of loss of substance we can simulate the various position of the hook in the brain. In order to maximize the accessibility, we can with deformation tool of the software, curve the hook, as the embalmer, and visualize the boundaries of the hook.

It's also possible to calculate the various angles of the hook, allowing then to have the area where the brain was disrupted by the embalmer (Fig. 11).



Fig. 10 - 3D simulation of two hooks.

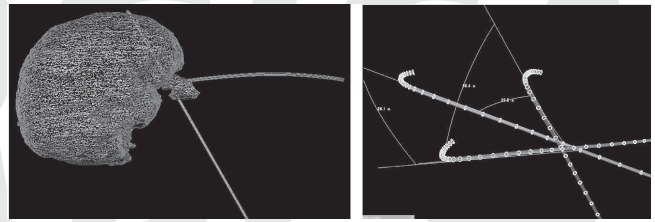


Fig. 11 - 3D simulation of «méchanical excerebration».

Conclusion

With CAD (Concept Aided Design) the virtual anthropology is a reality, we can preserve physical integrity of these human remains mummified, and above all it allow to study and compare more anthropological data. Until now the study of excerebration was “anecdotic, but a more complete research of the principle of excerebration, with a study sample more significant, a methodology with a protocol using 3D reconstruction and simulation, can allow us to assess a probable evolution and diversity of mummification.

Literature Cited

- Bou C, Pomar P, Pessey J., Rabino-Massa E. 1998. Reconstitution faciale 3D d'images tomodynamométriques par CAO: l'exemple d'une étude anthropologique. *Revue Laryngol Otol Rhinol*, 119:333-335.
- Bou C, Pomar P, Treil J, Rabino-Massa E, Donadoni-Roveri A. 1997. Méthodologie d'examen anthropologique 3D: application sur des têtes de momies égyptiennes de la collection MARRO de Turin. *Atti del Convegno «Nuove tecnologie nella tutela e nel recupero delle raccolte naturalistiche museali e scientifiche.»* Torino, 10/11 novembre 1997: 91-95.
- David Ar. 1997. Disease in Egyptian mummies: the contribution of new technologies. *Lancet* June 14, 349 (9067): 1760-3.
- Harwood-Nash Dc. 1979. Computed tomography of ancient Egyptian mummies. *J Comput Assist Tomogr*. Dec, 3(6): 768-73.
- Leek F Filce. 1969. The problem of brain removal during embalming by the ancient Egyptians. *Journal d'égyptologie et d'anthropologie*, 55: 112-116.
- Macke A. 1992. Les orifices d'éviscération endocrânienne aux basses époques. Une étude à propos de 84 crânes provenant de la vallée des Reines. *Annales du Service des Antiquités Egyptiennes*, tome LXXII.
- Nicolaeff. 1930. Quelques données au sujet des méthodes d'excérération par les Egyptiens. *L'Anthropologie*. 40: 77-92.
- Rabino-Massa E. 1997. Le collezioni scientifiche museali: la collezione antropologica egiziana «G. Marro» del Museo di Antropologia di Torino. *Atti Convegno «Nuove tecnologie nella tutela e nel recupero delle raccolte naturalistiche Museali e scientifiche.»* Torino 10-11 novembre 1997: 1-5.
- Strouhal E. 1980. Embalming, excerebration in the Middle Kingdom. *Science in Egyptology, proceedings of the "Science in Egyptology" symposia*, ed A Rosalie David: 141-154.