

# Pathophysiology of Mummification

Ezio Fulcheri

Università di Genova, Di.C.M.I. Sezione di Anatomia Patologica. Ezio.Fulcheri@unige.it

**KEY WORDS:** Italian mummies, embalming, histological analysis

Italian mummies are a biological, historical, and cultural heritage of significant value.

However, only in the past few years has this heritage been properly appreciated, quite recently if compared to the history of Paleopathology. Its importance in quantitative terms and the abundance of biological, anthropological, and medical information offered to researchers are more and more appreciated.

Also, because of Italy's huge cultural and artistic heritage, mummies of historic figures, who have been of significant value for Italian culture, are often linked to significant and abundant figurative or literary works of art, and to historic documents, thus providing an invaluable added value.

As already mentioned, this wealth of mummies has only recently been discovered and capitalised upon.

There are two main areas of research: one, on natural and artificial mummies of historic figures, in particular from the Renaissance period, who belonged to the Italian aristocracy. Needless to say that Professor Fornaciari is the master of this research field; and the other one, on the mummies of Saints.

Artificial mummification, or embalming, has continued over the centuries as a very rich and structured tradition, until today. The last known mummification of monarchs dates back to December 19, 1847. It was performed on Mary Louise of Austria, Duchess of Parma, who was the wife of Napoleon and who ruled over the Duchy of Parma that had been annexed to the French Empire. In the religious field, I would like to recall the mummification of San Luigi Orione in 1981, which was done to complete a partial natural mummification that had been damaged by the tomb conditions.

However, apart from these two very special categories of mummies, there is a great number of, mainly natural, mummies distributed all over Italy.

Natural mummies are more abundant than artificial ones. For this reason, when assessing our biological-cultural heritage, in addition to the number of embalmed individuals, we also have to consider all buried corpses that have undergone natural mummification. From a paleopathological and bio-anthropological point of view, these natural

mummies are extremely interesting, because they do not represent a selected population sample, nor a caste; quite the contrary, they constitute a randomised sample distributed all over Italy of different populations, in both geographic and ethnic terms. Actually, Italy is like a bridge over the Mediterranean and it has for centuries hosted and experienced the transit of different populations, who have contributed to building up an unparalleled ethnic and genetic mosaic. Even the late Andrei Sandison, who came here in Turin to study Marro's Egyptian collection, when referring to the Egyptian mummies, used to observe that many natural mummies are paradoxically better preserved than many artificial ones. This is because embalming was not always performed in a proper way, it was often carried out quickly, superficially, in an incomplete and clumsy way, and poorly finished.

All the mummies from Navelli, Venzona, Ferentillo, Urbania, Savoca, and Comiso, or the many others who live their wonderful lives in our beautiful Peninsula deserve to be mentioned. They are living their special lives so well, that they have inspired Professor Grilletto, an Egyptologist and anthropologist in Turin, to write about the "Wonderful Life of Mummies".

The catacombs or "Latomie" of the Capuchin Friars in Palermo are one of the most picturesque and impressive places ever, where a great number of mummies can be seen. Following an estimate I made after a personal guided recognition in 1991, there are 1852 mummies that are exhibited and that can be investigated, 1252 of them are arranged in corridors, and 600 in coffins. But there are many others collected in large rooms and in side corridors. It is a partially natural mummification. The corpse is somehow prepared and then mummification is promoted by placing the corpse in special, very narrow places called "colatoi" (drainers). In these places, mummification is promoted, by draining all organic fluids produced by the early putrefaction and liquefaction of internal organs, through a sort of net featuring a grid and gutters. In this way, body dissolution processes cannot be self-maintained, nor escalated.

When visiting the catacombs, in the long corridors literally covered by mummified corpses – either exposed or placed in coffins – one cannot but notice the great differences in preservation conditions of the various individuals. In

particular, one can see perfectly mummified corpses alternated with those showing a very poor mummification. At this point, we should reflect why is it so, and think of the reasons why, assuming equal techniques and environmental conditions, there are so many differences.

In 1991, I had the opportunity to examine a sample of mummified tissues from Ferentillo, a small town near Terni. There are currently 25 mummies from Ferentillo. In that occasion, we studied one third of them. The differences in quality observed were so great that it was even impossible to make any comparison between them.

Although well known, I believe it is useful to remind it here in this Lecture, that natural mummification is a post-mortem transformation process, and, in order to fully understand it, it is important to focus on its very early stages. Actually, even in Forensic Pathology treaties, little attention is given to these early events, because they are a sort of twilight zone between Pathologic Anatomy – which mainly studies fresh tissues – and Forensic Pathology, which has to deal with severely damaged tissues.

Post-mortem transformation processes begin with three fundamental steps, that can never be avoided.

The first one is tissue autolysis, namely the breaking of sub-microscopic cell structures, the lysis of cytoplasmic organs with release of chemical substances, and the breaking of intercellular bonds.

Autolysis of basal layer cells of the epidermis is particularly visible on the skin: it becomes even more manifest and significant if the body lies in a humid or wet environment, thus leading to a peculiar 'glove' or 'flap' like detachment of the entire epidermis (epidermolysis).

Self-digestion takes place after autolysis; this process is spurred by gastric, pancreatic, and spleen juices acting on gastroenteric mucosa and on the epithelium of annexed glands.

In this way, stomach, duodenum, jejunum, ileum, and colon, together with salivary glands, pancreas, and liver are destroyed, or, better said, they are self-destroyed as if following a pre-set plan.

In this way, intestinal and gastric contents are released, thus paving the way to the third stage, namely putrefaction. Therefore, putrefaction follows self-digestion. It is promoted by the action of bacteria that live inside the body as beneficial gut flora, especially in the gastro-enteric tract and in the feces, or of bacteria from the outside.

If putrefaction develops in a turbulent way, this will cause all viscera and the body in general to liquefy.

Conversely, if putrefaction is stopped early on in the process or it is prevented by whatever cause, body transformation processes may take other directions and other routes, thus leading, for example, to skin corification and tissue mummification.

Natural or artificial mummification is essentially based on the following two fundamental bio-physical actions: bactericide or disinfectant action and dehydration.

The first one aims to remove bacteria supporting putrefaction and stop the ensuing production of toxins and chemical degradation fluids. The second one is aimed at the almost total removal of water from tissues.

However, owing to its complexity, the human body features different tissues with different chemical, physical, structural, histological, and cytological properties, which, in turn, has a major impact on water content and on the resistance to the action of enzymes and body fluids.

While self-digestion, as we have mentioned before, mainly involves splanchnic organs and among them abdominal ones, autolysis is a ubiquitous process, although with different intensity and expression depending on the anatomic substrate. If, for example, we take the skin (which is the body cover and the contact surface with the external environment), autolysis takes place on very different anatomic structures, such as the epidermis, the connective fibrous-elastic dermis and the fibrous-adipose and fibrous-muscular hypodermis. These are four different tissues covering the body, that are quite different as to their resistance to physical forces, bacterial action, different in water content, in they way they are able to contract and




Fig. 1- Autolysis of basal layer cells of the epidermis (epidermolysis). Hematoxylin-eosin.

coarctate or, conversely, exfoliate and flake (as we have already mentioned when speaking about massive epidermolysis) (Fig. 1).

Finally, vascularisation and the capillary and pre-capillary vascular mesh is also quite different, with vessels full of blood, which is an important element for red blood cell agglutination in the tissues and in the vessels themselves, leading to erythrolysis and to the capillary progression of toxins, bacteria, and enzymes into the tissues.

In a work, or rather, in a series of studies that began in 1998, we stressed the importance of the histological examination of a small skin sample to monitor mummy preservation conditions.

The main purpose of these investigations was the preservation of mummies, specially those kept in museums, as well as to better control external infesting, infecting, and polluting agents.

We also pointed out that from the histological examination of a skin sample it was possible, with a good degree of confidence, to determine the type of mummification and embalming techniques employed. This study would, at least, allow a better interpretation of the whole set of historical and archaeological information about the find.

As an example, we would like to mention the restoration performed in Genoa on the mummy of the Priest Pasherienaset. The mummy, which belongs to the 25<sup>th</sup> Saitic dynasty originating from Edfu, was kept in a wonderful sarcophagus, and adorned in rich clothes and jewels. "I will live for ever" recited the inscription on the sarcophagus and a long theosophic treaty gave an explanation of these words. However, degradation was severe and urgent restoration actions became necessary. The histological examination of some small skin fragments, a sort of target biopsies, disclosed a high amount of organic and inorganic substances employed during embalming. A chemical analysis of the specimens completed the study and laid the basis for calibrating and planning subsequent restoration. We could also mention the case of the Blessed Odorico da Pordenone, who was recently restored in Udine during a canonical recognition performed in 2002. Only with a chemical test of substances found at the surface and a histological examination of targeted skin biopsies was it possible to determine with certainty the number and the type of preservation actions carried out in the past and, among them, also the most rudimental ones, in which also lacquers and varnishes were employed.

Therefore, histological skin examination is an essential step in preservation actions which, in this way, are, let's say, 'tailor-made'.

However, a histological skin examination also allows to assess epidermis preservation conditions, which is as important as the former aspect.

For example, when an integer epidermal layer is observed, consistent with the dermis and a non homogenised, structured dermis, epidermolysis in wet environment can be ruled out, hence it is an indirect way to confirm an excellent and rapid mummification.

Actually, the absence or presence of a documented epidermolysis also depends on the amount of water in the tissues. A dehydrated skin of an older individual will be less likely to undergo epidermolysis, which, conversely, in the highly hydrated skin of a child, will be massive and take place quite early on. Even the thickness of cell layers, of flat epithelia and their keratinization (which varies depending on the body surface anatomic region) has a strong impact on the development of the previously mentioned processes. Well, we can state that the mere study of skin epidermolysis can provide quite comprehensive information, since epidermolysis itself is affected by so many variables that are different from individual to individual.

In Marro's Egyptian collection kept in Turin, there is the oldest documented case of sacral meningocele. The mummy of the infant is lying prone, as if not to press the dome formation on the sacral region, and it is placed on a dense layer of compact sand (Fig. 2).

All skin layers are perfect, pigmented and thin. A quick mummification in the hot, aseptic and sterile sand of the desert brought about the conditions leading to excellent preservation (Fig. 3).

And yet, an examination of the deeper tissues and also of the cartilaginous skeleton (which was studied by taking small samples of exposed areas) sprang an unpleasant surprise on

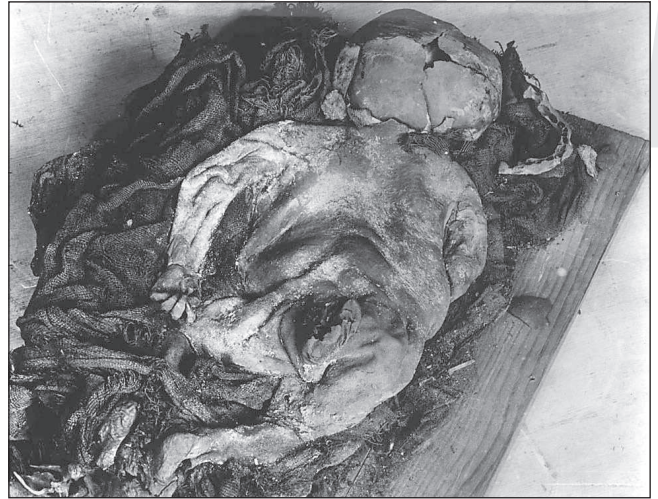

Fig 2 - Case of sacral meningocele on Egyptian mummy of XI dynasty (2050-1955 a.C.). Marro's Egyptian Collections, Museum of Anthropology and Ethnography of Turin.

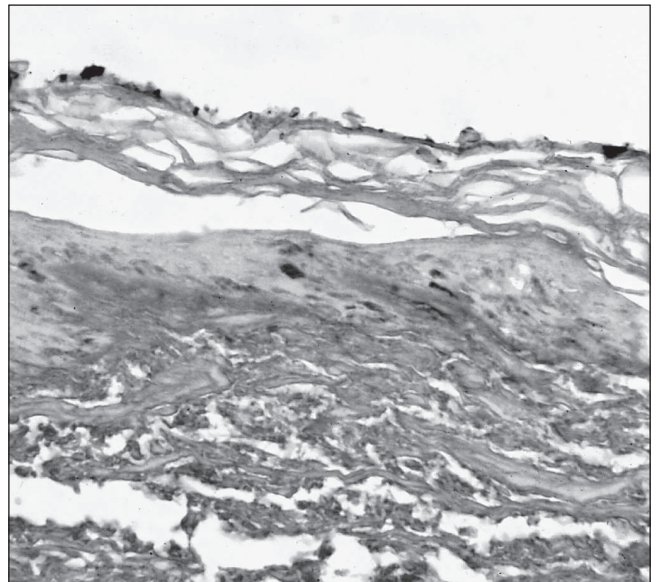


Fig. 3 - Excellent preservation of epidermal layer. Hematoxylin-eosin.

us. No splanchnic organ examined could be interpreted by histological examination, nor any connective or muscular tissue was satisfactorily preserved. Even part of the skeleton, as properly documented by CT scan, was altered, destroyed, and broken up.

What is the reason for this profound difference between the two – the superficial and deep – body sections, if not the very type of mummification? It was too quick. Mummification was perfect only on the surface, whereas the very features of the body – rich in water proportionally to its mass and poor in elastic fibres and hyaline fibrous tissues – have brought about the conditions for a massive sequence of post-mortem liquefaction processes to take place. This is the so called "egg shell" effect, well known to all pathologists, when fixing anatomic pieces in coarctating fluids and in fixatives whose action is far too quick. The fixative is no longer able to penetrate through all the tissues, if the outermost portion of the specimen has been fixed too quickly.

How quick and effective the mummification process was, can indeed be understood from the degree of homogenisation of dermal fibres, and of the deep dermis in particular. However, the study of the hypodermis, rich in fat cells, yields even more interesting information.

Fatty tissue consists of cells with a large fluid-filled cytoplasm. Lipid transformation is indeed one of the processes taking place during autolysis, namely, and this should be stressed, when no organic, secreted juices, nor bacteria are expected to be involved. Lipids are oxidised under the influence of lipolytic enzymes. Typically, adipoceres are formed, which are heavier and larger and form intracellular fatty acid crystals. The latter ones agglutinate

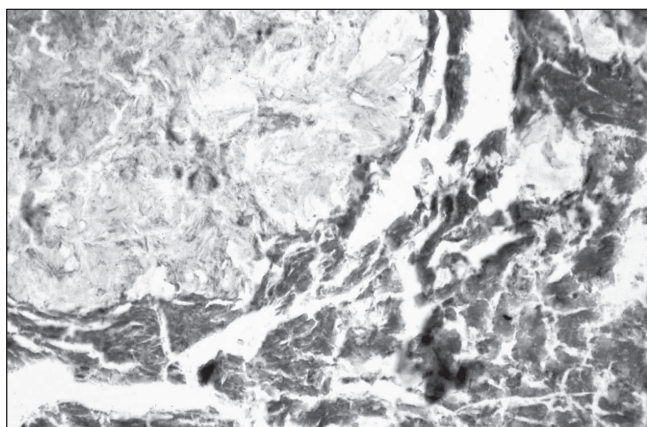


Fig. 4 - Lipid transformation during autolysis. Hematoxylin-eosin.

and accumulate, thus breaking up the subcutaneous fatty and cell tissue (Fig. 4).

The transformation of lipids and proteins into masses of adipoceres takes place in a warm environment and it normally leads to poor mummification.

However, this process is not only spurred by temperature, but, even more, as we are going to discuss later on, by the amount of fatty cells and, in other words, by the amount of fatty tissue and by the thickness of the *panniculus adiposus*. In this way, and for the second time, we have been able to confirm that the body characteristics can actually affect all natural mummification stages and most embalming operations.

Having finished with these thanatological remarks on mummification, I would now like to tackle an issue which is more strictly connected to Pathologic Anatomy. Before every post mortem examination, the pathologist examines the cadaver, assessing its age, determining the gender, identifying its ethnic origin and population features, assessing its anthropological features (e.g. if it is short-limbed, normotype, or long-limbed), and determining its trophic state and nutrition conditions. Trophic state means the amount of muscle mass and nutrition conditions means fatty reserves.

This preliminary analysis allows you to define the anthropological and biological substrate on which diseases have acted that have led to the patient's death. This is also the schedule that a paleopathologist must follow, and perhaps even more so, when examining a mummy.

However, in paleopathology, this methodological background is not only necessary to understand the anatomic substrate on which diseases have acted, but also to understand the type and features of mummification. This last point is essential for a proper post-mortem examination and in order to carry out a whole set of targeted tests.

Actually, any examination, from the simplest to the most sophisticated one, can be invalidated from the very start if we are confronted with a poor mummification. In such a case, the examination becomes a sterile, useless show of skills and techniques that has no diagnostic value whatsoever, nor any benefit in enhancing knowledge. Unfortunately, these actions are not only sterile, but they can even be harmful, because they are likely to damage or destroy precious materials. Obviously enough, because of our scientific training, priority must always be given to specimen preservation, whenever we must decide on whether an invasive examination should be performed, even when it may possibly help us achieve excellent results. For this reason, we are upset when we learn about complex post-mortem examinations or complicated tests performed on materials unlikely to yield any valuable information. Or, even worse, failure to consider the so called 'examination limiting factors' often leads to an uncontrolled production of a high number of disturbing scientific works and results, that spread confusion among the scientific community, just like real "false positives" of research.

An issue that needs to be addressed in future conferences on mummies is the one related to research quality controls and checks on the reproducibility of results. Paleopathology is a serious, authoritative, and constructive science and, as such, it has to be defended and supported.

Today, endocrine tumours can be correctly classified through the application of immunohistochemical or molecular biology techniques, by which the biological and genetic characteristics of these tumours can be identified. In this way, a high number of variants, each of them with major biological differences, could be identified, and appropriate and specific therapies could be developed accordingly. A correct diagnosis by the Pathologic Anatomy Department is however possible only when fixation of the neoplastic tissue is fast enough and correct fixatives are employed. Conversely, untimely or inappropriate fixation, while making any test valueless, can cause even more damage by providing false positive outcomes, with dramatic implications for the patient, who will undergo unnecessary surgeries or incorrect therapies.

Let us now go back to the issue of interpretation.

The first natural mummy I had the opportunity to examine was not very old, it was actually a very recent one. It is a mummy discovered in Genoa and examined by Professor Aldo Franchini, Director of the Institute of Forensic Medicine. This mummy was found in an old noble palace in the Medieval centre of Genoa: it was the mummy of an almost centenarian woman. The old lady was found in the month of August sitting in an armchair in front of a large fireplace. Complete mummification had taken place which was consolidated in a fortnight (this was the time she had

been reported missing). A well ventilated room, air circulation produced by the fireplace, the dry climate typical of the month of August and, above all, her body structure had all contributed to mummification. The old lady was in fact tall, long-limbed, very thin, and showing senile decay approaching marasmus.

This story is important to remember that there are other factors apart from external conditions (environmental conditions) leading and triggering mummification. Indeed, we have just seen that intrinsic body conditions make up an 'inner environment' which interacts with the external one. The age of the individual is the first variant to the system. Conversely, the second variant is the amount of fatty tissue in the individual.

It is important to remind it here, that the amount of fatty tissue is the expression of the individual's general nutrition condition and not of the degree of muscular mass trophism. Therefore, assuming equal weights, the lean to fatty mass ratio is to be considered as a variant.

Physical anthropology has set valuable characterisation guidelines for constitutional types and auxological patterns. Pende's school in Genoa is to be credited with the most valuable contributions on this issue, still important today on an international level.

Brachymorphic individuals are more likely to become obese than longilineal ones. Physical exercise or work may shape the constitutional profile, but they will never be able to change it.

I am not going to delve here on constitutional features of the various ethnic groups (that you know very well), characterised by the very distribution of fatty masses, especially around the hips and the glutei.

When discussing the complex relation between constitution and obesity, we cannot but remind here the important role played by food behaviour and obesity, which is a real borderline between normal and pathologic conditions, between physiological and pathological behaviours. The two extremes of this variable and rich range full of shades are anorexia nervosa and severe bulimia-related obesity. These pictures are then complicated by other borderline or frankly pathologic conditions related to endocrine variations and imbalances.

Endocrine profiles vary and change significantly over an individual's life. On top of this discontinuous pattern, dysendocrinias proper may develop, that are linked to specific situations, for example during pregnancy or in post-menopausal age.

Also, there are different types of pathologic obesity, caused by genital syndromes, such as adipose-genital dystrophy and eunuchoidism, just to mention a couple of them.

This sort of assessment may be important when studying mummies. Before the actual examination, it is necessary to take anthropometric measurements and collect constitutional data about the body: the weight of the mummy, its stature, but also its skull, chest and abdominal circumference, arm and forearm circumference, compared to the overall limb length, thigh and leg circumference correlated with the other circumference values. These are simple and yet poorly coded parameters, since they are

believed to be useless or unreliable. The prevailing notion is that mummies cannot be assessed by their external measurements or appearance, because they are just ... mummies, hence they are dried up, writhed, and coarctated! This is no sterile exercise, nor is it a simplistic approach to the problem that only apparently follows the methods of an old approach to the macroscopic examination of mummies. At this point, I would like to tell you my experience with the mummy of Dona Maria Coronel, born in 1334 and who died in 1409, whom I have examined in Seville. She was a nun, very famous in Spain, who joined the congregation after spending the first part of her life in the lay world. She was the widow of the nobleman Joan de la Cerda. When she became widow, she joined the monastery of Santa Chiara. King Pedro I, who fell in love with this beautiful young woman, attempted at her vow of enclosure. Dona Maria, in order to escape the king's love assaults, disfigured her face with boiling oil, thus producing a large scar. On her mummy, we were able to document what until then had been thought to be just an agiographic legend. The mummy was in poor preservation conditions, but, above all, a massive amount of fatty tissues that had built up during old age was evident (Fig. 5). In spite of non perfect mummification conditions, we were able to obtain excellent histological specimens only of the epidermis and the dermis, but not of the other explorable organs. Significantly enough, however, the skin was literally separated by small and atrophic



Fig. 5 - Mummy of Dona Maria Coronel (1334-1409). Excellent preservation of epidermis.

muscular masses and, like a shell, it would enfold the whole body, like a sort of armour plating, forming large folds around the arms and the abdomen. Hence, her strong senile gynecoid obesity had affected and characterised mummification, a real physio-pathology of mummification.

How can we talk then of physio-pathology of a post-mortem transformation process? And yet we have seen that there is a strong correlation between the para-physiologic condition of an individual before his/her death and its mummification, specially if its a natural one. Just like there is a strong influence of the individual's pathologic conditions before death on the type of mummification in terms of rapidity and bio-transformation processes. This is the reason why we can talk of physiopathology of mummification.

However, death is prepared by baseline disease and intervening diseases. The final cause of death has its onset on this substrate: it is often a disease of minor entity, an acute complication. The final cause of death brings an end to a disease cycle and, with it, to the life of the individual.

In Pathologic Anatomy, this logical model must be followed. An algorithm is developed following a so called 'epicritic' type of reasoning, which links up all the events and traces back the patient's medical history. On the autopsy table, it is often quite easy to determine the final cause of death, while it is difficult to the identify the baseline disease and its evolution stages.

When carrying an autopsy on a mummy, it is often easier to define the final cause of death than to follow epicritic reasoning: this is much more complex.

The progress of the baseline disease, even when lasting several years, modifies and fashions the patient in a significant way.

We could mention, for example, all debilitating and cachexia-triggering diseases, first of all malignant tumours. In terminal cachexic cancer patients, fatty tissues, that have almost totally disappeared, are only to be found in the retro-orbital cavity, in the mediastinum and in the renal loggias. Muscles become atrophic and also abdominal viscera progressively reduce their noble parenchymal portion, heading towards progressive atrophy similar to the one found in senile age.

Other long-term diseases may also affect the body metabolism and, subsequently, the accumulation of lipids, thus leading to obesity, they may trigger degeneration processes of connective tissues or cause huge amounts of fluids to accumulate in already mix-oedematous tissues. Oedema itself – which is common to different pathologic pictures – is nothing but a symptom of sometimes very different diseases, ranging from chronic renal failure, to venous and lymphostatic disease, and heart disease.

This is just a first and also most evident example of two sets of contrasting situations which, through disease, can actually shape and model the body.

However, when examining a corpse from the outside and during macroscopic diagnosis, there are quite a few more to be considered.

It is not even possible to provide a summary list of all the major diseases, because it would be reductive and in any case incomplete. Here, I would only like to briefly mention some conditions that can deeply alter a body shape and, above all, its structure and normal relations between its

various constituents

I would like to tell a couple of stories that I think are paradigmatic.

The first one refers to the already mentioned Blessed Odorico da Pordenone, a Franciscan friar who walked the roads of China and was the first to evangelise these lands following Marco Polo's travels. He died in 1331 wasted and tired following a debilitating, probably a toxoinfectious disease. When examining the mummy, abdominal viscera were in perfect preservation conditions, the colon, empty and without feces, was in perfect conditions, all organs, ligaments and the diaphragm had maintained all their relations. Abdomen putrefaction, owing to this pathologic substrate, for sure, could not have been triggered.

The second story refers to San Juan de la Cruz, whose mummy is kept in Segovia. San Juan died in Ubeda in 1591, following severe and massive erysipelas. His skin was raised by real flows of pus through fistulas from side to side. Attempts by physicians to perform surgical incisions and drainage were to no avail. Despite the very severe degradation conditions of the mummy, histological examinations could demonstrate that mummification itself had taken place in a very peculiar way. Many parts had mummified after putrefaction, and severe putrefaction damage was visible also on the muscles that were broken up into amorphous masses. Fistulas and massive lympho-adenomegaly could still be documented.

Let us now try, in a sort of medical-clinical excursus, to suggest this method of analysis by applying it to some infectious diseases, while thinking at the related different body involvement. These are common diseases that have raised the interest of paleopathologists since the historic beginning of this discipline. These diseases may affect large segments of the population and therefore must be well known and studied. Among the audience here there are some world experts in these studies on the evolution and spread of infectious diseases.

Tuberculosis, in its chronic form, is a totally debilitating disease linked to wasting and cachexia.

The plague spreads without giving time to the infected individual to develop any structural body change, so much so that paleopathologists consider it as an important model for the analysis of populations exterminated in a short period of time, without any distinction between healthy and sick individuals, as a sort of dramatic and cruel experiment. Bacterial infections may develop showing different symptoms depending on the attacked organ. They may damage the kidneys or the heart, specially the cardiac valves, and also cause extensive oedemas.

Widespread infection, septicaemia, gangrene – specially if caused by anaerobic bacteria – are due to bacterial colonisation of the entire body. After death, also hematic defence is lost, hence all vessels turn into pathways for further infection spread. During the post mortem transformation phase, autolysis and self-digestion are almost totally skipped, because a tumultuous putrefaction is immediately triggered.

Finally, we mention liver cirrhosis, which may cause the death of a plethoric and fat individual (the typical picture of the

“wealthy drinker” who is a heavy drinker and eater) or, in the opposite case, of the thin and cachectic, wasted individual (in this case the picture of the so called “poor drinker”, who gives up on food to be able to buy alcohol). I’ll keep the example of these two opposite pictures to confirm the thesis of the pathologic substrate, which affects mummification. In the first case, we have a high amount of fatty tissues, of fluids and a bulky abdominal mass, with dilated – specially intestinal – viscera. Mummification will be difficult and it is unlikely to reach excellent results. In the second case, an extremely advantageous situation promoting mummification is brought about, because a reduction of fluids and water content has already been set forth during life.

An exception may further confirm our reasoning. In alcohol-related liver cirrhosis, ascites – namely a huge collection of fluids in the peritoneum – are a constant finding. This type of water tank will be able to produce a paradoxical effect in mummification. Namely, mummification will be perfect in the limbs, the head and the neck, but it will be really poor at abdominal level. The guts are likely to liquefy and become macerated, and the final picture will be of an empty cavity. Ascites can also be observed in other pathologic conditions, for example in cancer of the genitalia or of the gastro-enteric tract, in malabsorption cases, especially in children, in dysmetabolic diseases, and in degenerative liver diseases, as well as, although less known, in infectious diseases, such as malaria.

This is the patho-physiological background we must keep in mind when studying mummified individuals. Today it is difficult to talk about a «mummy autopsy», because we all get the shivers, when thinking of opening and eviscerating a mummy. Only targeted, minimally invasive examinations are performed today, which, therefore, need to be carefully calibrated.

We have gone from total body evisceration to endoscopic biopsies, and then to micro-autopsy with targeted biopsies. Probably, in a not too far away future, we will perform bio-molecular and genetic autopsies in order to study the body from within its pathologic mechanisms. By then, this lecture of mine could appear old fashioned and obsolete. Quite the contrary, I would like to convince you about the modernity of this approach and the need to set a style based on observation and on a proper planning of targeted actions. The knowledge of the type of individual under examination, of the physiological substrate (with reference to the individual’s age and constitution), and of the pathological substrate form the basis on which our studies should be developed: a starting point, to avoid useless and foolish eviscerations and also to validate, stimulate, and guide even complex, refined investigations, as well as the advance research works we are going to hear about in the next few days.

### Literature Cited

Aufderheide AC. 2003. The scientific study of mummies. Cambridge University Press, Cambridge.  
Cockburn A, Cockburn E. 1980. Mummies, disease and Ancient

- Cultures. Cambridge University Press, Cambridge.
- Baracchini P, Noll G, Gabrielli N, Venturini M, Benedettucci M, Fulcheri E. 1991. Immunohistochemical study of keratins in the skin of artificial and natural mummies. *Comunicazione. Atti IV International Meeting of Adriatic Society of Pathology, Ravenna, 24-25 giugno, 1989.* In *Pathologica* 83, 496.
- Baracchini P, Crestani C, Drusini A, Fulcheri E, Rippa Bonati M. 1991. Studio preliminare delle mummie naturali di Ferentillo: esame istologico ed immunoistochimico della cute. *Rivista Italiana di Medicina Legale*, 1, 171-183.
- Bini G. 1954. La storia patologica di Maria Luigia d’Austria Duchessa di Parma. Parma per l’arte. III: 123-128.
- Farella F. 1982. Cenni storici della chiesa e delle catacombe dei Cappuccini di Palermo. Fiamma Serafica. Palermo.
- Fornaciari G, Tornaboni D. 1990. La mummia dei musei di Varese. Comune di Varese.
- Franchini A. 1985. *Medicina legale*. CEDAM, Padova.
- Fulcheri E, Fulcheri Gualco M. 1993. Ricognizione sui resti di San Giovanni della Croce. In AA Vari: San Giovanni della Croce. Relazioni sul trattamento conservativo eseguito sul corpo. Carmelitani Scalzi, Edizioni Grafiche Manfredi, Roma.
- Fulcheri E. 1996. Mummies of saints: A particular category of Italian mummies. In Spindler K., Wilfing H., Rastbichler-Zissernig E., Zur Nedden D., Nothdurfter H. (eds). *The Man in the ice, Vol 3. Human Mummies*. Springer-Verlag.
- Fulcheri E, Boano R, Grilletto R, Savoia D, Leospo E and Rabino Massa E. 1999. The preservation status of ancient Egyptian mummified remains estimated by histological analysis. *Paleopathology Newsletter*: 108, 8-12.
- Fulcheri E. 2001. Su alcune ricerche di Giuseppe Bini: esempi di percorsi culturali tra anatomia patologica e storia. *Pathologica* Vol 93 n°3, pag. 244-247.
- Fulcheri E. 2001. Mummies of Spanish Saints Science And Tecnology For The Safeguard Of Cultural Heritage In The Mediterranean Basin Alcalà de Henares SPAIN 9-14 Luglio 2001. Atti in : Consiglio Nazionale delle Ricerche e Universidad de Alcalà. Science And Tecnology For The Safeguard Of Cultural Heritage In The Mediterranean Basin. Cofàs, Mostoles pag 212,
- Fulcheri E, Ventura L. 2001. Rileggendo tra antiche e nuove ricette per dare freschezza ai tessuti mummificati o disseccati. *Pathologica* Vol. 93 n° 6, 700 –706,
- Fulcheri E. 2001. Alcune osservazioni e considerazioni scientifiche sulle mummie naturali e sulle mummie dei Santi in particolare. *Alba Pompeja*, XXII, 2, 52-59.
- Grilletto R. 1987. La splendida vita delle mummie. Sugarco, Milano.
- Grilletto R, Fulcheri E, Boano R, Leospo E, Rabino Massa E. 2000. Un cas de méningocèle dans un nouveau-né égyptien de la XI Dynastie. VIII . Congresso Internazionale di Egiptologia, Cairo.
- Janssen W. 1977. *Forensic Histopathology*. Springer-Verlag, Heidelberg.
- Micozzi M.S. 1991. Postmortem change in human and animal remains. Charles Thomas Publisher, Springfield.
- Payne-James J, Busuttill A, Smock W. 2003. *Forensic Medicine. Clinical and pathological aspects*. GMM, San Francisco.
- Pende N. 1939. *Trattato di biotipologia umana individuale e sociale*. Vallardi, Milano.
- Ros C. 1980. *Dona Maria Coronel. Historia y legenda*. Masterio de Santa Ines. Sevilla,.
- Sandison A.T. *Human Mummification technique in ancient Egypt*. 1-5.
- Williams D.J, Ansford A.J, Priday D.S, Forrest A.S. 2003. *Forensic Pathology*. Churchill Livingstone, Philadelphia.