

Can Left ventricular outflow tract aortic velocity time integral guide fluid resuscitation in septic patients? - A case report

Livio Colombo,¹ Francesco Panizzardi,¹ Irene Rusconi,¹ Anna Roncoroni,¹ Marta Bergamaschi,² Alfredo Macheda¹

¹Pronto Soccorso - DEA Ospedale SantiPaoloCarlo, Presidio San Paolo, Milan; ²Pronto Soccorso - Medicina d'Urgenza Ospedale Niguarda, Milan, Italy

Abstract

Hemodynamic monitoring of unstable patients is an everyday issue for Emergency Physicians (EP). Considering the difficulty, in Emergency Department (ED) settings, to assess invasively Stroke Volume (SV), Cardiac Output (CO) and Peripheral Vascular Resistance (PVR), EP should be familiar with non-invasive, easy and reproducible methods that can estimate these parameters. The use of Left Ventricular Outflow Tract aortic Velocity Time Integral (LVOT-VTI) with echocardiography, as estimate of SV, integrated with inferior vena cava collapse index and clinical examination could give the opportunity to non-invasively understand at which point of an ideal cardiac output/central venous pressure relation (according to the Frank Starling law) the patient is situated. In this case report we describe a septic patient accessing the ED with both respiratory and cardiac failure, and we show that the use of aortic LVOT-VTI is an easy and reproducible approach to understand cardiac hemodynamic in scenarios involving multiple pathologic mechanisms.

Case Report

We describe the case of an 81 years old woman coming in the ED hypotensive, fever over 38° in the past 4 days with cough, yellowish sputum, progressive worsening shortness of breath and

increasing distal edema. She was affected by chronic cardiac failure with Ejection Fraction (EF) between 40 and 45% due to chronic cardiac ischemia with a previously NSTEMI treated conservatively in 2015, chronic hypertension, initial cognitive impairment; in 2016 she had acute pulmonary embolism caused by proximal femoral vein thrombosis, in 2017 she underwent abdominal aortic endoprosthesis replacement for aortic abdominal aneurism. She was in therapy with Direct Oral Anticoagulant (DOAC), diuretic, ACE-inhibitors and beta blockers. At the arrival in ED: arterial pressure was 85/65 mmHg, EKG showed atrial fibrillation with 110 beats per min with diffuse inferolateral nonspecific alterations; temperature was 38.6°, sO₂ in oxygen mask at FiO₂ 50% was 90%; she was dyspneic with a respiratory rate of 32 breaths per min, the skin was pale and wet; vesicular murmur was absent at both lung bases and there were crackles at the both middle lung fields; finally, there were moderate bilateral distal edema.

The anteroposterior Chest X-Ray (CXR) showed bilateral pleural effusion at the inferior side and blood tests (Table 1) revealed WBC 19500/mmc, CRP 70 mg/dL (n.v. < 5 mg/dL), normal renal function, CPK 800 IU/L (n.v. < 135 U/L), sodium 145 mEq/L, potassium 3.8 mEq/L and troponin 8 ng μL /L (n.v. < 0.012 ng/L). Blood gas analysis in ambient air showed hypoxemia at 58 mmHg, pH 7.35, pCO₂ 35 mmHg, HCO₃ 22 mEq/L and lactate was 3.2 mmol/L.

We stopped ACE-inhibitors and beta blockers and started giving her oxygen at 50% FiO₂ with facial mask, 1000 mL crystalloids in about 60 minutes and paracetamol 500 mg, without any change in blood pressure and heart rate. In the mean time we performed a lung ultrasound (LUS) showing bilateral pleural effusion of three spaces and B lines in both medial fields with subpleural consolidation with dynamic air bronchogram compatible with pneumonia on the right side (not visible in CXR because of concomitant pleural effusion). We performed a cardiac ultrasound, that showed a dilated left ventricle with an inspective moderate low EF; inferior vena cava of 22 mm, with distension of hepatic veins and collapse index of less than 30% with an estimated central venous pressure (CVP) of about 18 mmHg. To quantify the SV, we used the LVOT-VTI (Figure 1). In this way, according to echocardiography guidelines (1) first we calculated aortic LVOT diameter as 19 mm, then cardiac output (CO) as 2.8 L/min (4-6 L/min) (using the formula CO = heart rate x (LVOT-VTI x aortic area), as showed in Figure 1, and then we derived the peripheral vascular resistance (PVR) as about 2100 dynes.sec/cm⁵ (normal range 800-1400 dynes.sec/cm⁵), using the formula $PVR = [(MAP - CVP)/CO] \times 80$, (where MAP = mean arterial pressure and CVP = central venous pressure). The SOFA score, calculated because of the pneumonia seen with LUS, was 4 point, resulting in a diagnosis of sepsis. Unfortunately, we didn't perform ultrasound evaluation before fluid expansion and so we could not compare the data, but because we had no modifications in arterial pressure, and relying on all echo data previously showed, we could suppose that this

Correspondence: Livio Colombo, Via Eugenio Pellini 4, 20125, Milan, Italy
E-mail: liviocolombo@me.com
Tel.: +39.3497853013

Key words: Aortic velocity time integral; unstable patients; hemodynamic monitoring.

Ethics approval and consent to participate: The manuscript does not contain any elements that would allow the recognition of the patient.
Conflict of interest: the authors declare no potential conflict of interests.

Received for publication: 12 January 2020.
Accepted for publication: 6 June 2020.

This work is licensed under a Creative Commons Attribution 4.0 License (by-nc 4.0).

©Copyright: the Author(s), 2020
Licensee PAGEPress, Italy
Emergency Care Journal 2020; 16:8817
doi:10.4081/ecj.2020.8817

patient was more full than empty, because of acute heart failure due to septic myocardial depression for pneumonia and quite high ventricular rate atrial fibrillation: for this reason we need to keep monitoring CO. To ameliorate lung failure we started using CPAP with helmet with a PEEP of 10 cmH₂O and FiO₂ 50%; to improve cardiac function, relying on the reduced LVOT-VTI and clinical evaluation, we stopped infusions and gave diuretic (furosemide 40 mg ev twice a day) because we have supposed that she was in the flat part of the Starling curve. We administered antibiotic therapy for community-acquired pneumonia as well. Arterial pressure stabilized at 95/55 mmHg, and we did not start norepinephrine considering the high value of PVR we found and fearing a further increase of it with probably decrease of CO.

During the first 24 hours she appeared to get slightly better: arterial pressure progressively rose up and stabilized to 95/60 mmHg, urine output was 1800 mL/day, heart rate was reduced at 90 beats per min (permanently in atrial fibrillation) and oxygen saturation was improved to 95% in CPAP helmet. We repeated cardiac ultrasound and found that LVOT-VTI had improved from 9 to 12 cm, CVP was estimated at about 15 mmHg (18 mm and collapse index at < 30%) CO was estimated as 3.1 L/min and PVR as 1500 dynes.sec/cm⁵, so we kept going on with the same therapy.

Between day 2 and 5 we stopped CPAP, rhythm returned spontaneously sinus at 75 beats per min with minimal T alterations and troponin level decrease; Arterial pressure was stable at 105/50 mmHg, LVOT-VTI rose up to 15 cm, with an estimated CO of 3.3 L/min inferior vena cava of 15 mm, without distension of hepatic veins, collapse index of 50% with an estimated CVP of about 10 mmHg and PVR decreased to 1300 dynes.sec/cm⁵. After a constant improvement during the following week, we discharged the patients at day 9.

In Figure 2 we show the patient's hemodynamic trend (from A to C) we have presumed during the hospitalization using CO assessment from LVOT-VTI and CVP estimated from inferior vena cava collapsibility.

Discussion

Fluid administration is a cornerstone of sepsis and septic shock therapy: anyway, it should be considered that an excessive amount of fluid, especially in a condition of capillary leak like sepsis, can lead to water extravasation, interstitial oedema and then organ dysfunction, with potential harmful consequences.¹ Quite often, physiopathological mechanisms in peri-shock and shock states are more complex than they appear and they can involve more than one of the three major hemodynamic mainstays: volemia, myocar-

Table 1. Blood test.

	Day 1	Day 2	Day 3-5	Day 9
Hb g/dL	11.2	10.6	10.2	10
WBC cell/uL	19.500	18.500	14.000	9.000
CRP (< 5 mg/dL)	70		45	20
Creatinine (mg/dL)	1.1	1.4	1	0.9
CPK (< 180 UI)	800	450		225
ALT/AST (IU/L)	55/75	60/80	35/40	28/30
Troponin (< 0.012 ng/mL)	8	8	3	0.5

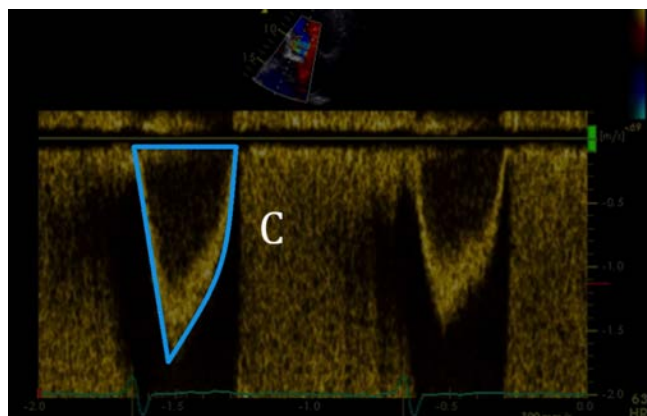
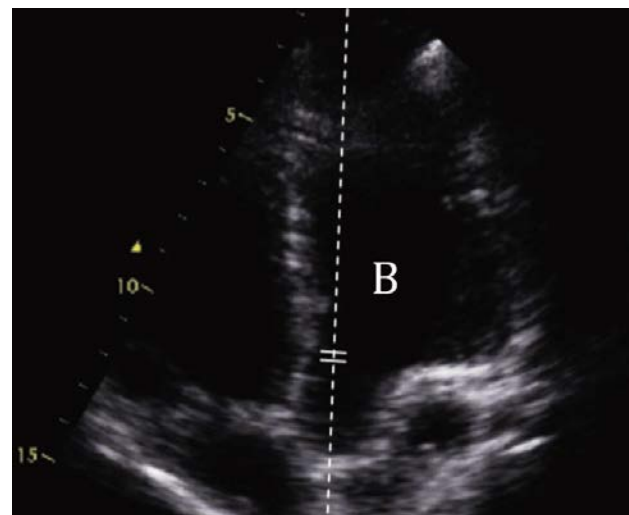
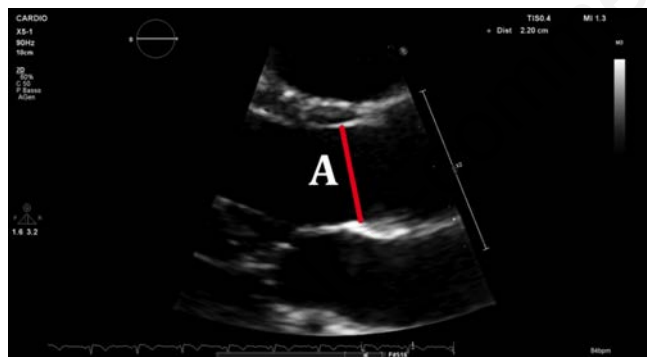

Figure 1. How to calculate cardiac output using aortic VTI. To calculate the stroke volume and then the cardiac output, the first step is measuring the diameter of the LVOT (A): this can be performed in the parasternal long axis view, proximal to the aortic valve, in mid-sistole. Once obtained the diameter, we can calculate the cross-sectional area (CSA). VTI is recorded with pulsed Doppler from an apical five-chamber view (B). Then the pulsed Doppler sample volume has to be positioned proximal to the aortic valve and in line with the blood flow through the LVOT. When the sample volume is correctly positioned, the recording shows a velocity curve with a well-defined peak; the VTI is then measured (C in blu line). Assuming the stroke volume as a cylinder, it can be calculated according to the formula $SV = CSA \text{ (base)} \times VTI \text{ (height)}$.

dial function and vascular tone. In our case we had to face the need for a very conservative fluid resuscitation, considering that, beyond the comments about water extravasation above mentioned (“volemia”), the patient had an acute-on-chronic heart failure and probably a septic myocardial depression (“contractility”): in other words, do we have to administer crystalloids or not in a patient that is on the flat part of the Frank-Starling curve? In order to answer to this question properly, it is mandatory to assess accurately the exact degree of each of these components.

We need also to remember that CO is the main determinant of oxygen delivery and the result of ventricular Stroke Volume (SV) and Heart Rate (HR). Thus, the assessment and optimization of CO are recommended in critical care ill patients with altered tissue perfusion.²

Arterial pressure, although is the single most common parameter used worldwide in ED to guide cardiovascular assessment, is not the only answer to guide fluid resuscitation in difficult scenarios, because of the complex physiology behind its value involving CO, vascular tone and elastance of the arteries;³ we also know it could be misleading in acute settings: for example, a normal arterial pressure is possible in a patient who has high vascular tone and low CO or, at the opposite side, very low vascular tone and high CO, as it happens in the early phase of septic shock.⁴

Clinical echocardiography in ED settings has a well definite role.^{5,6} What is interesting is that in emergency scenarios it is not necessary to reach the expert cardiology physician level, because it is generally enough to watch for general cardiac function, heart chambers dimension and valves integrity using basic view. However, we need also something that could give us a “numeric value” of the cardiac function, in an easy way. EF is the most common single echocardiographic parameter used worldwide, but it has several limitations: it could overestimate the actual cardiac function in case of mitral regurgitation and sometime could have problems in manual delineations of the endocardium with boundary continuity in critical patients,⁷ therefore the correct interpreta-

tion of EF requires adequate experience. LVOT-VTI needs less ultrasound skill, is easily reproducible and could quickly and non-invasively estimate CO and its variations after fluid challenge vasoactive therapy.^{2,8} It should be considered, anyway, that LVOT-VTI measure has to be very accurate, since even a few millimeters of error in the measurement of the outflow tract of the left ventricle, having to raise the radius to the second power, can cause considerable errors: this suggest us that we could rely only on VTI variations. With CO data and the inferior vena cava collapsibility with echo as an indirect value of CVP, we could also obtain a rough general value of the systemic vascular resistances as mentioned above. Finally, in ED settings is not easily possible to estimate in which part of the CO/CVP relation the patient is, according to the Frank-Starling law: in this patient we relied on LVOT-VTI value together with clinical and others ultrasound parameters, to better understand and follow patient’s hemodynamic profile and each day response to therapy. If we had based our hemodynamic evaluation only on clinical exam and clinical parameters, we could have taken a different way to treat this patient, probably using more fluids and therefore worsening the condition of heart failure: this is a critical issue especially in septic patients, considering that up to 60% of them suffer from myocardial depression⁹ although its clinical meaning is still subject of debating.¹⁰

Conclusions

In selected cases in ED, in which there could be different causes of instability induced by a modification of two or more between vascular tone, cardiac function and volemia, we think that the use of LVOT-VTI as we showed in this case report, could be an useful tool for ED physician, partly thanks to its reproducibility and simple use, but mostly because it could guide the clinician to better understand the pathophysiology behind the single case and monitor adequately patients’ response to therapy.

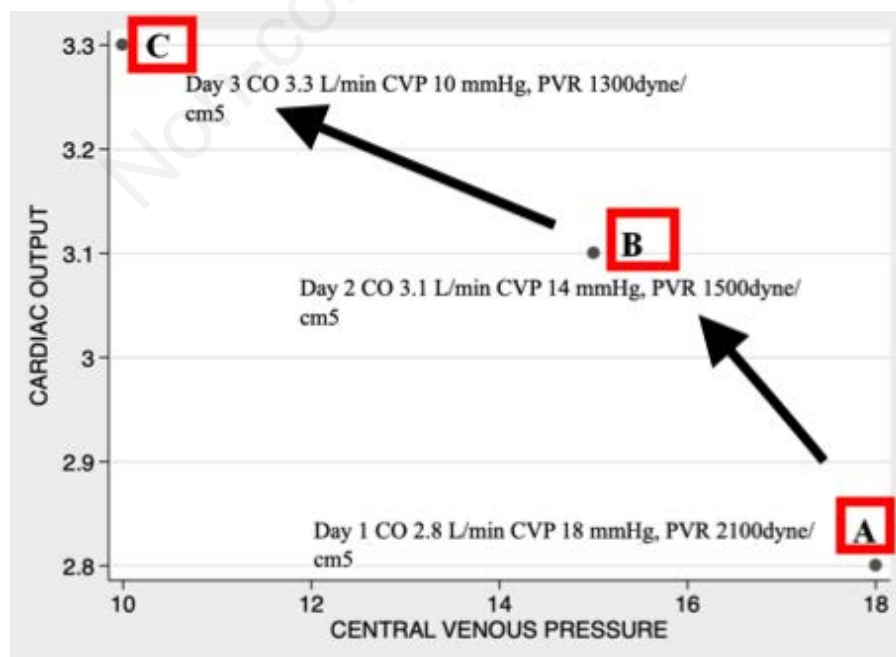


Figure 2. Patient’s hemodynamic trend during the first three days derived from LVOT-VTI and clinical data.

References

1. De Backer D, Cholley P, Slama M, Vieillard-Baron A, Vignon P. Hemodynamic monitoring using echocardiography in the critically ill. Springer; 2011.
2. Malbrain M, Van Regenmortel N, Saugel B, et al. Principles of fluid management and stewardship in septic shock: it is time to consider the four D's and the four phases of fluid therapy. *Ann Intensive Care* 2018;8:66 .
3. Magder S. The meaning of blood pressure. *Crit Care* 2018;22:257 .
4. Pinsky MR, Teboul JL, Vincent JL. Hemodynamic Monitoring. Springer; 2019.
5. Vieillard-Baron A, Millington SJ, Sanfilippo F, Chew FM, et al. A decade of progress in critical care echocardiography: a narrative review. *Intensive Care Med* 2019;45:770-88.
6. Pinsky MR, Payen D. Functional hemodynamic monitoring. *Crit Care* 2005;9:566-72.
7. Cikes M, Solomon SD. Beyond ejection fraction: an integrative approach for assessment of cardiac structure and function in heart failure. *Eur Heart J* 2015;37:1642-50.
8. Cholley B. Echocardiography in the intensive care unit: beyond "eyeballing". A plea for the broader use of the aortic velocity-time integral measurement. *Intensive Care Med* 2019;45:898-901
9. Vieillard-Baron A, Caille V, Charron C, Belliard G, et al. Actual incidence of global left ven-tricular hypokinesia in adult septic shock. *Crit Care Med* 2008;36:1701-06
10. McLean SA. Down but not out: myocardial depression in sepsis. *Crit Care* 2012;16:132.

Non-commercial use only