

## Oral sores: a rare presentation of *Herpes zoster*

Sunder Nagakeerthana,

Murugaiyan Rangaraj

Department of Dermatology, Sri Manakula Vinayagar Medical College and Hospital, Puducherry, India

### Abstract

*Herpes zoster* is one of the common dermatological diseases in elderly. It is clinically diagnosed by the presence of vesicles in a zosteriform pattern, appearing along one or two dermatomes. We report a rare presentation of herpes zoster occurring over hard palate. Early recognition of such rare presentations of *Herpes zoster* and treatment with antivirals at the appropriate time is the most essential step required to decrease the morbidity.

### Introduction

*Herpes zoster* is one of the common dermatological diseases that we come across. It is clinically diagnosed by the presence of vesicles in a zosteriform pattern, appearing along one or two dermatomes. We report a rare presentation of *H. zoster* occurring over hard palate. Diagnostic dilemma can occur especially with such atypical presentation, where only oral lesions are present.

### Case Report

A 65-year-old male, presented with severe burning sensation over his mouth for past 2 days and subsequently developed multiple white lesions over roof of the mouth. Patient revealed that he had low-grade fever for past two days. He gave history of chickenpox during his childhood and denied history of recurrent fluid filled skin or oral lesions. There was no history of consumption of hot drink, intake of drug prior to onset of symptoms and no history of immunosuppression. Pain was measured using visual analogue scale (VAS), the patient had moderate pain in the last 24 h. On examination, multiple erosions of size 0.3×0.3 cm each, coalescing at few areas, with overlying slough seen over right side of the hard palate with mild erythema beneath the erosions (Figure 1). Tzanck smear revealed multinucleated giant cells.

Diagnosis of herpes zoster was made in

view of the burning sensation, erosions confined to the right side of the hard palate and presence of multinucleated giant cells in Tzanck smear. Patient was treated with tablet acyclovir 800 mg five times daily for seven days, topical benzocaine 20% gel and was advised to consume liquid to semi solid, bland diet. The erosions resolved completely within a period of 10 days, although pain was persisting for which tablet pregabalin 75 mg was prescribed once daily for 2 weeks (Figure 2).

### Discussion

*H. zoster* is caused by varicella zoster virus (VZV). This localized viral disease has a long recorded history; it has been recognized as a distinct entity since ancient times. It manifests as a result of reactivation of the dormant virus in the sensory ganglion following a clinical or sub clinical varicella infection early in life or occasionally in utero. The reactivation of the virus may occur spontaneously or due to immunosuppression.<sup>1</sup> *H. zoster* typically presents with painful vesicular rash which affects a single dermatome, and lasts for three to five days before the lesions become pustular and forms scab. The rash may be preceded by a prodromal phase lasting 48-72 h or longer, consisting of throbbing pain and paraesthesia in the region of the affected sensory nerve.

In immunocompetent patients, the most common site of reactivation is the thoracic nerves followed by the ophthalmic division of the trigeminal nerve (herpes zoster ophthalmicus), which can progress to involve all structures of the eye. If the mucocutaneous division of the VII cranial nerve, which innervates the ear and side of the tongue, or the VIII cranial nerve is involved, the development of lesions in the ear, facial paralysis, and associated hearing and vestibular symptoms are known as Ramsay Hunt syndrome.<sup>2</sup> In patients

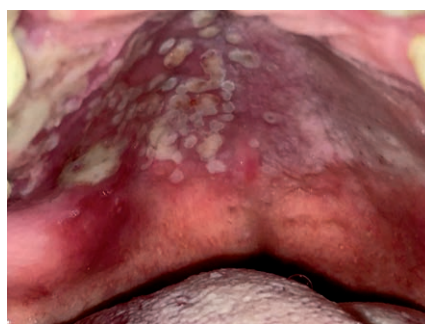


Figure 1. Zosteriform lesions confined to right side of hard palate.

Correspondence: Murugaiyan Rangaraj, Department of Dermatology, Sri Manakula Vinayagar Medical College and Hospital, Kalitheerthalkuppam, Madagadipet, Puducherry - 605 107, India.

Tel.: +91.9940672927.

E-mail: rangaraj06@gmail.com

Key words: *Herpes zoster*; oral sores; ulcers; Tzanck smear.

Conflict of interest: the authors declare no potential conflict of interest.

Contributions: SN, concepts, design, definition of intellectual content, literature search, manuscript preparation, editing and review; MR, concepts, design, literature search, manuscript editing and review.

Received for publication: 29 April 2016.

Revision received: 5 June 2016.

Accepted for publication: 6 June 2016.

This work is licensed under a Creative Commons Attribution-NonCommercial 4.0 International License (CC BY-NC 4.0).

©Copyright S. Nagakeerthana and M. Rangaraj 2016

Licensee PAGEPress, Italy  
Geriatric Care 2016; 2:5964  
doi:10.4081/gc.2016.5964

with HIV it can present in various forms, there can be multidermatomal involvement, crusted, nodular, vesiculopustular and ulcerative lesions can occur that may be widely disseminated or localized.<sup>1</sup>

*H. zoster* occurring intraorally without any lesions over skin is rare. In our patient lesions are confined to right side of the hard palate in the trigeminal nerve V2 distribution.

Recurrent aphthous stomatitis and *Herpes simplex* (HSV) infection can appear as grouped oral ulcerations and resemble *H. zoster*. However in case of recurrent aphthous

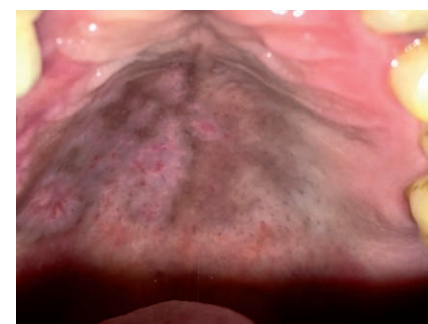


Figure 2. On follow-up erosions have resolved.

stomatitis, it appears as a single ulcer or a small number of ulcers and usually occurs on loose, non-keratinized mucosal surfaces such as buccal or labial mucosa, the floor of the mouth, and over the ventral aspect of the tongue.<sup>3</sup> On the other hand, herpetic ulcers are usually multiple and affect immovable, keratinized mucosa, including the hard palate, attached gingivae, and dorsal tongue.<sup>4</sup>

Tzanck smear does not differentiate between *H. zoster* and HSV infection. Diagnosis can be confirmed by estimating specific antibodies in the serum against VZV and HSV. A polymerase chain reaction (PCR) assay is the most sensitive test for identifying HSV and varicella zoster virus.<sup>5</sup> In our setup serology and PCR are not routinely done, in such situations clinically Herpes zoster can be differentiated from HSV infection by the zosteriform pattern which does not cross the midline, and severe pain. Recurrence of lesions is common in case of HSV infection.

Keratinized mucosa is an integral part of the masticatory apparatus, which is routinely subject to trauma by burns from hot food. Ulcers from thermal injuries are unlikely to cause multiple, discrete ulcerations as in our patient.<sup>3</sup>

*H. zoster* is usually treated with orally administered acyclovir. Other options include other antiviral medications such as famciclovir and valacyclovir. These antiviral medications

are most effective when started within 72 h after the onset of the rash.<sup>6</sup> If standard treatment failed, recent drugs such as brivudine represents an alternative therapy. Brivudine is given as a single dosage which is more comfortable for patients to use, complete remission and preservation of a satisfactory function can also be achieved, however it is not available in most of the developing countries.<sup>7</sup> Such cases addition of an orally administered corticosteroid can provide modest benefits in reducing the pain of herpes zoster and the incidence of postherpetic neuralgia. The pain associated with *H. zoster* can range from mild to unbearable. Therefore analgesics should be given, and for patients with more severe pain additional narcotic medication can be given. Topical analgesics or topical acyclovir can be given for local application depending on patient's complaints.<sup>6</sup>

## Conclusions

*H. zoster* and postherpetic neuralgia are quite common conditions, primarily in elderly and immunocompromised patients. Early recognition of such rare presentations of *H. zoster* and treatment with antivirals at the appropriate time is the most essential step required to decrease the morbidity.

## References

1. Latheef EA, Pavithran K. Herpes zoster. A clinical study in 205 patients. *Indian J Dermatol* 2011;56:529-32.
2. Wareham DW, Breuer J. Herpes zoster. *BMJ* 2007;334:1211-5.
3. Grimard BH, Larson JM, Mcbrayer RH. Scalded mouth with headache. Herpes zoster (shingles). *Am Fam Physician* 2008; 7:1307-9.
4. Bruce AJ, Rogers 3<sup>rd</sup> RS. Acute oral ulcers. *Dermatol Clin* 2003;21:1-15.
5. Yaeen A, Ahmad QM, Farhana A, et al. Diagnostic value of Tzanck smear in various erosive, vesicular, and bullous skin lesions. *Indian Dermatol Online J* 2015;6: 381-6
6. Stankus SJ, Dlugopolski MI, Packer DE. Management of herpes zoster (shingles) and postherpetic neuralgia. *Am Fam Physician* 2000;61:2437-44.
7. Vij O, Bornfeld N, Roggendorf M, et al. [Brivudine as an alternative systemic therapy to aciclovir and ganciclovir in acute retinal necrosis syndrome due to varicella-zoster virus]. *Klin Monbl Augenheilkd* 2003;220:710-5. [Article in German].