

A case report of extranodal diffuse large B-cell lymphoma involving upper limb soft tissue in a patient with rheumatoid arthritis on immunosuppressive therapy

Saverio Antonio Ciampi, Cosimo Petrelli

Department of Internal Medicine, "San Giuseppe da Copertino" Hospital, Copertino (LE), Italy

Correspondence: Saverio Antonio Ciampi, Department of Internal Medicine, "San Giuseppe da Copertino" Hospital, via Carmiano, 73043, Copertino (LE), Italy.
Tel.: +39 0832936481.
E-mail. saverioantonio.ciampi@asl.lecce.it

Key words: lymphoma, soft tissue, upper limbs, rheumatoid arthritis, immunosuppressive drugs.

Contributions: SAC, material preparation, data collection, and analysis, writing of the first draft of the manuscript. Both authors contributed to the study's conception and design and commented on previous versions of the manuscript. Both authors read and approved the final manuscript.

Conflict of interest: the authors have no relevant financial or non-financial interests to disclose.

Ethics approval and consent to participate: not applicable.

Informed consent: informed consent was obtained from all individual participants included in the study.

Patient consent for publication: the authors affirm that human research participants provided informed consent for publication of the images.

Funding: none.

Availability of data and materials: data are available from the corresponding author upon request.

Additional information: an initial form of the manuscript was posted in preprint form on Research Square site (DOI: 10.21203/rs.3.rs-2647935/v1). It will be the responsibility of the authors to inform the Editors of Research Square to update the information in case of publication of the manuscript.

Received: 25 June 2023.
Accepted: 13 February 2024.

Publisher's note: all claims expressed in this article are solely those of the authors and do not necessarily represent those of their affiliated organizations, or those of the publisher, the editors and the reviewers. Any product that may be evaluated in this article or claim that may be made by its manufacturer is not guaranteed or endorsed by the publisher.

©Copyright: the Author(s), 2024
Licensee PAGEPress, Italy
Geriatric Care 2024; 10:11541
doi:10.4081/gc.2024.11541

This work is licensed under a Creative Commons Attribution-NonCommercial 4.0 International License (CC BY-NC 4.0).

Abstract

An 80-year-old woman affected by rheumatoid arthritis on immunosuppressive therapy was evaluated for an 11-month history of swelling of her left upper limb. The patient did not report systemic symptoms. Ultrasonographic examination showed hypoechoic masses in the upper limb soft tissue, brachial vein thrombosis, and suspected malignant axillary lymphadenopathy. The patient underwent an excisional biopsy of the lymphadenopathy for histologic examination; a diagnosis of diffuse large B-cell lymphoma was made. The patient started anticoagulation therapy and chemotherapy, with a follow-up at a hematology clinic. At a 3-month follow-up visit in our clinic, the swelling of her left upper limb decreased, and an ultrasonographic control demonstrated a reduction in the size and number of the soft tissue masses and resolution of vein thrombosis.

Introduction

Non-Hodgkin lymphoma (NHL) is a group of malignant neoplasms originating from the lymphoid tissues, mainly the lymph nodes. It can be divided into two groups, "indolent" and "aggressive", based on the disease's prognosis: indolent lymphomas present with lymphadenopathy for many years, whereas aggressive lymphomas have symptoms such as weight loss, night sweats, and fever.¹ NHL may be associated with various risk factors, including infections, environmental factors, immunodeficiency states, and autoimmune disorders such as rheumatoid arthritis.² It is common in ages 65 to 74, with the median age being 67 years.³ Nearly 25% of NHL cases arise in extranodal locations, and most of them involve both nodal and extranodal sites.⁴ Involvement of the soft tissue (defined as tissue that connects, supports, or surrounds other structures such as adipose tissue, connective tissue, and skeletal muscle) as a primary event is very rare, being estimated to occur in 0.1% of all lymphomas. Most of the time, the soft tissue is involved in direct spreading from affected lymph nodes and/or metastatic hematogenous dissemination.⁵ Diffuse large B-cell lymphoma (DLBCL) is one of the most common lymphoid neoplasms, representing 30-58% of NHL and with a crude incidence in Europe of 3.8/100,000/year.⁶ Despite a common morphology characterized by the diffuse proliferation of mature large B cells, these tumors are clinically and biologically very heterogeneous, and only ≤40% initially present in extranodal sites.⁶ Here we report the case of a patient with a history of rheumatoid arthritis who was referred to our hospital for swelling of her left upper limb, which was finally diagnosed as an extranodal location of an NHL with involvement of upper limb soft tissue, a location that is considered rare and difficult to recognize.

Case Report

An 80-year-old woman was evaluated in the internal medicine-ultrasonography clinic associated with the department of internal medicine at our hospital for swelling of her left upper limb. The patient had a clinical history of arterial hypertension, obesity, and rheumatoid arthritis, for which she was taking oral corticosteroids and subcutaneous methotrexate. 11 months before the current evaluation, she had noted swelling in her left elbow, but she did not perform further exams or visits because she referred her problem to her rheumatologic disease. During the next months, the patient observed that the swelling had been increasing in size, involving progressively the whole upper limb, and some days before the current evaluation, she had decided to ask for a visit to her rheumatologist, who indicated an ultrasonographic exam of her left arm for suspected vein thrombosis. At our evaluation, she was otherwise asymptomatic, and on clinical examination, erythema and edema of the left arm (Figure 1) were associated with the presence of a tender mass in the homolateral axilla. The ultrasonographic examination of the left upper limb, performed with a multi-frequency linear transducer, demonstrated the presence of multiple inhomogeneous hypoechoic nodular masses in the soft tissue of the upper arm (Figures 2 and 3) and brachial vein thrombosis. The ultrasound study of the left axilla showed lymphadenopathy with ultrasonographic characteristics suspected of malignancy (inhomogeneous ecostructure, loss of clear hogenic hilum, abnormal vascularization, irregular borders, increased size). No pathological findings were noted at the clinical and ultrasonographic examination of the right upper limb. The patient was instructed to discontinue immunosuppressive therapy and to start anticoagulation therapy with subcutaneous low-molecular-weight heparin at the dose for deep vein thrombosis. Blood tests were indicated, and the main results were: normal white cell count (6200 cells/ μ L), without anemia or thrombocytopenia; normal serum protein electrophoresis; and C-reactive protein of 8.4 mg/dL (normal value <0.5). Considering the presence of axillary lymphadenopathy, serological tests for viral infection and tumor markers were performed to exclude other possible diagnoses, like infectious diseases or solid tumors. The results were all negative, except for a slight increase in Ca 15.3 (35.4 U/mL) and β 2-microglobulin (3.42 mg/L) (Table 1). A whole-body computed tomography with contrast

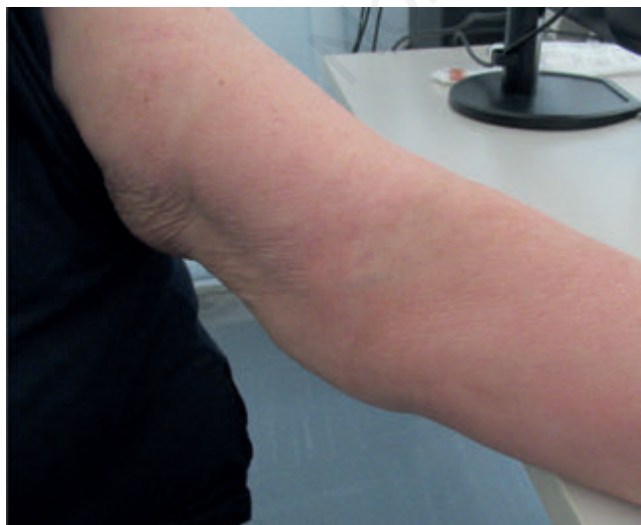

Figure 1. Photograph of patient's left upper limb: erythema and swelling of the whole arm are present.

injection showed multiple lymphadenopathy in the left axillary area and ruled out pathological involvement of other organs. An excisional biopsy of the axillary lymphadenopathy was performed for histo-

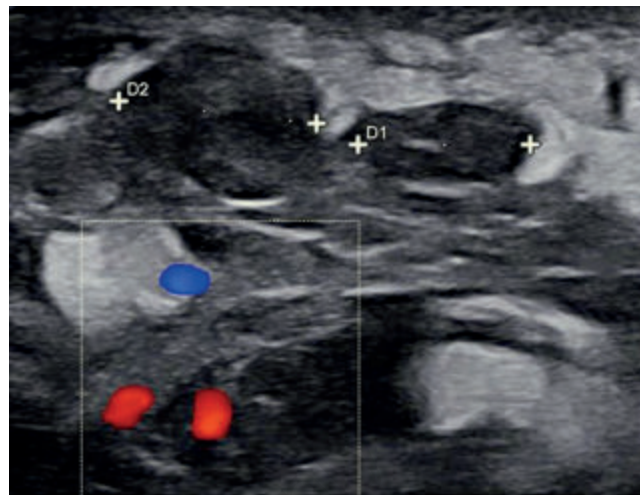


Figure 2. Image of the ultrasonographic exam of the left upper limb demonstrating the presence of nodular hypoechoic masses in the soft tissue. D1 and D2 are referred to as lesions' diameter.

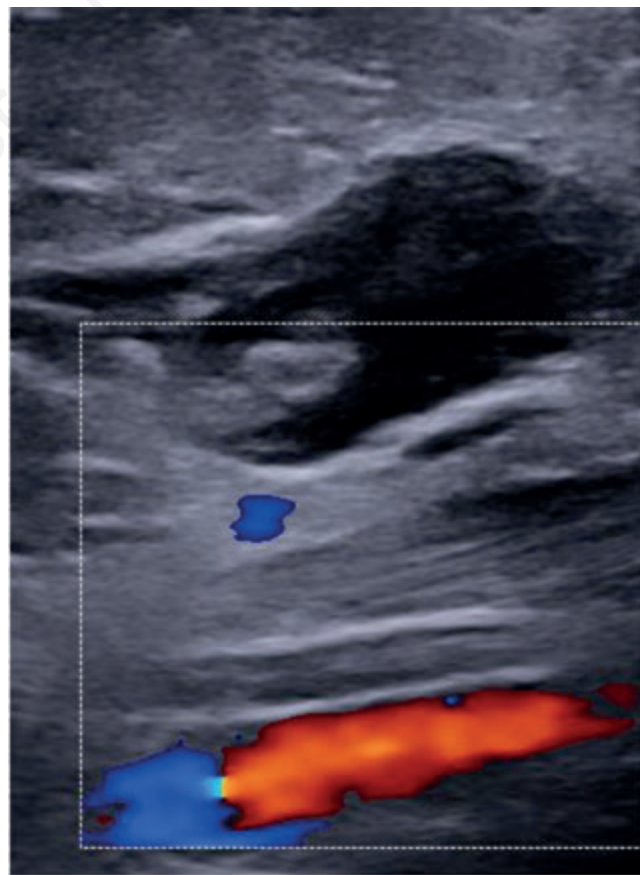


Figure 3. Image of the ultrasonographic exam of left upper limb demonstrating the presence of a nodular hypoechoic mass with irregular borders in the soft tissue, near the brachial vessels (red and blue signal in the color box).

logic examination, which showed the presence of fibrosis, necrosis, the proliferation of medium-large lymphoid cells from the B lineage (CD20+, CD79a+, CD19+), the absence of follicular dendritic cells, a growth fraction (ki67) of 40-45% and involvement of perilymph-nodal adipose tissue. A diagnosis of DLBCL was made, and the patient was referred to the hematology clinic for a specialist consultation and indications for the specific therapy. After undergoing a whole-body positron emission tomography/computed tomography that showed radiomarker captation in the left axillary area with a maximum standardized uptake value of 17.8, referred to as lymphadenopathy, and in the left breast and soft tissue of the left arm, referred to as edema, a chemotherapy regimen with R-COMP was started with periodical hematologist visits. At a 3-month follow-up visit at our clinic, after the start of chemotherapy, the patient reported well-being with a reduction in the swelling of her left upper limb; the ultrasonographic control showed brachial vein recanalization and a reduction in the number and size of the soft tissue masses.

Discussion

DLBCL is the most common type of aggressive NHL originating from the germinal center, and it represents a heterogeneous group of diseases with variable outcomes. It is ideally diagnosed from an excisional biopsy of a suspicious lymph node.⁷ DLBCL is extremely uncommon in the soft tissue of the arm, and a few cases have been reported in the literature, where they were sometimes mistaken to be other tumors, like sarcomas.^{8,9} Considering the rheumatologic history of the patient, our first suspected diagnosis was an acute manifestation of her chronic arthritis, but the rheumatological visit excluded this cause.

Finally, our ultrasonographic examination, which can be considered the best method to evaluate lymph nodes and soft tissue,^{10,11}

showed the presence of soft tissue masses, a finding that requires further exams to rule out neoplastic diseases. Furthermore, the ultrasound exam demonstrated the presence of vein thrombosis, a complication that can be associated with lymphoproliferative diseases.¹²

A histological examination of the lymph nodes with malignant characteristics was performed to make the definitive diagnosis of DLBCL originating in the left axillary lymph nodes, and then we associated the soft tissue masses with a secondary involvement of the soft tissue of the homolateral upper limb (Table 2).

Another consideration is that the patient was taking immunosuppressive therapy with methotrexate for rheumatoid arthritis. Other articles have just described the association between methotrexate and the onset of lymphoproliferative disorders like DLBCL, also in extranodal sites,¹³ so it could be possible to consider this drug as a potential cause of lymphoma in our case, although we do not have information about the exact time when the patient started this therapy.

A limitation of our study could be the fact that we did not perform a direct histological evaluation of soft tissue masses, but the results of the microscopic exam of axillary lymphadenopathy and the demonstrated clinical and imaging response to chemotherapy allowed us to conclude that the soft tissue masses were related to DLBCL as an extranodal localization of the disease.

As a final consideration, according to our advice, this clinical case is interesting not only for the rare localization of NHL in the soft tissue but also for the indolent presentation (defined as lymphadenopathy without systemic symptoms) of a lymphoproliferative disease like DLBCL, which is considered an aggressive lymphoma.¹⁴

Furthermore, to understand the pathobiologic characteristics of every singular case of DLBCL, the presence of nodal or extranodal sites and the characteristics of the tumor-associated microenvironment could be crucial for the prognosis of the patient and the response to therapy.¹⁵ In this case, the role of our clinic is important

Table 1. Blood tests and results performed for the differential diagnosis of lymphadenopathy.

Blood tests(unit of measurement)	Reference range	Results
White cells (cells/ μ L)	4300-10000	6200
Neutrophils (cells/ μ L)	1500-8000	3400
Platelets (cells/ μ L)	150000-400000	293000
Hemoglobin (g/dL)	12-16	12.7
Seric proteins (g/dL)	6-8	6.1
Albumin (g/dL)	3.5-5	3.6
IgG (mg/dL)	800-1800	877
IgA (mg/dL)	90-450	182
IgM (mg/dL)	60-270	215
LDH (U/L)	<250	268
C-reactive protein (mg/dL)	<0.5	8.4
β 2-microglobulin (mg/L)	0.80-2.34	3.42
CEA (ng/mL)	<3	Absent
GICA (U/mL)	<37	Absent
Ca 125	<35	Absent
Ca 15.3	0-30	35.4
HCV Ab and RNA	Absent	Absent
HBV Ab and DNA	Absent	Absent
HIV Ab	Absent	Absent
CMV DNA	Absent	Absent
EBV DNA	Absent	Absent

Ig, immunoglobulin; LDH, lactate dehydrogenase; CEA, carcinoembryonic antigen; GICA, gastrointestinal antigen; Ab, antibody; HCV, hepatitis C virus; HBV, hepatitis B virus; HIV, human immunodeficiency virus; CMV, cytomegalovirus; EBV, Epstein-Barr virus.

Table 2. Summary of clinical problems of the patient described in the clinical case and related medical actions, with correlation from the time of our clinical evaluation.

Time	Clinical situation	Actions
Eleven months before our evaluation	Swelling of patient's left elbow	None (waiting).
Between 11-month before and the day of our evaluation	Increasing of the swelling involving the whole left upper limb	Rheumatologist visit: prescription of an ultrasonographic exam of left upper limb.
At our evaluation	Erythema and swelling of patient's left upper with impaired mobility of the arm	Ultrasonographic exam of left upper limb: finding of axillary lymphadenopathy, soft tissue masses, brachial vein thrombosis. Our indications: to stop immunosuppressive drugs and to start anticoagulation treatment
Into 1-month after our evaluation	Staging and histopathological diagnosis	Whole-body CT: confirmation of lymphadenopathy in the left axillary space without involvement of other nodal stations. Excisional biopsy of lymphadenopathy and microscopic exam: diagnosis of diffuse large B-cell lymphoma. Patient was referred to hematologist for chemotherapy and follow-up
One month after our evaluation	Staging of the clinical problem	Whole-body PET/CT: pathological captation of radiomarker in the left axillary space (lymphadenopathy). The patient started chemotherapy
After 3-month from the start of chemotherapy	Clinical visit of the patient and ultrasonographic control of her left upper limb	Reduction of left arm's swelling; reduction of soft tissue lesions and recanalization of brachial vein

CT, computed tomography; PET/CT, positron emission tomography/computed tomography.

in the clinical and imaging follow-up of the patient because, as the first observer of the patient before the chemotherapy, we have a referral to establish if the soft tissue lesions are stable or changed and if they are residual of disease or new lymphadenopathy. In this context, the collaboration of various specialists (hematologists and internists) is fundamental for the best care of patients with lymphoproliferative disorders.

Conclusions

Despite the infrequent location, it is necessary to consider the soft tissue of the extremities as a potential site of lymphoproliferative disorders (primitive or secondary), and this diagnosis should be considered in the course of the clinical evaluation of a patient admitted for a swollen limb, especially if risk factors such as old age, autoimmune diseases, and immunosuppressive therapy are present in the clinical history. Furthermore, a complete ultrasonographic study of soft tissue, lymph nodes, and vascularization of the extremities should be part of the clinical approach for these cases, considering its help as a guide in the differential diagnosis. Further studies are probably needed to evaluate the biology of these disorders and their clinical presentation in older patients, especially those with rheumatologic diseases taking immunosuppressive therapy.

References

- Armitage JO, Weisenburger DD. New approach to classifying non-Hodgkin's lymphomas: clinical features of the major histologic subtypes. Non-Hodgkin's lymphoma classification project. *J Clin Oncol* 1998;16:2780-95.
- Fallah M, Liu X, Ji J, et al. Autoimmune diseases associated with non-Hodgkin lymphoma: a nationwide cohort study. *Ann Oncol* 2014;25:2025-30.
- Sapkota S, Shaikh H. Non-Hodgkin lymphoma. Treasure Island, FL: StatPearls; 2023.
- Singh R, Shaik S, Negi BS, et al. Non-Hodgkin's lymphoma: a review. *J Family Med Prim Care* 2020;9:1834-40.
- Derenzini E, Casadei B, Pellegrini C, et al. Non-Hodgkin lymphomas presenting as soft tissue masses: a single center experience and meta-analysis of the published series. *Clin Lymphoma Myeloma Leuk* 2013;13:258-65.
- Vitolo U, Seymour JF, Martelli M, et al. Extranodal diffuse large B-cell lymphoma (DLBCL) and primary mediastinal B-cell lymphoma: ESMO clinical practice guidelines for diagnosis, treatment and follow-up. *Ann Oncol* 2016;27:v91-v102.
- Liu Y, Barta SK. Diffuse large B-cell lymphoma: 2019 update on diagnosis, risk stratification, and treatment. *Am J Hematol* 2019;94:604-16.
- Siddiqui RS, Ferman D, Tuli S, et al. Diffuse large B-cell lymphoma of the left upper extremity mimicking a sarcoma. *Cureus* 2021;13:e15588.
- Hung LK, Cheng JC, McGuire LJ, Tsao SY. Primary malignant lymphoma of the deep tissues of the hand. *J Hand Surg Am* 1988;13:683-6.
- Toprak H, Kiliç E, Serter A, et al. Ultrasound and Doppler ultrasound in evaluation of superficial soft-tissue lesions. *J Clin Imaging Sci* 2014;4:12.
- Jacobson JA, Middleton WD, Allison SJ, et al. Ultrasonography of superficial soft-tissue masses: society of radiologists in ultrasound consensus conference statement. *Radiology* 2022;304:18-30.
- Schmidt RA, Lee AYY. How I treat and prevent venous thrombotic complications in patients with lymphoma. *Blood* 2022;139:1489-500.
- Niitsu N, Okamoto M, Nakamine H, et al. Clinicopathologic correlations of diffuse large B-cell lymphoma in rheumatoid arthritis patients treated with methotrexate. *Cancer Sci* 2010;101:1309-13.
- Lang R, Gill MJ. Diffuse large B-cell lymphoma. *N Engl J Med* 2021;384:2261-2.
- Solimando AG, Annese T, Tamma R, et al. New insights into diffuse large B-cell lymphoma pathobiology. *Cancers (Basel)* 2020;12:1869.