

# Prolonged liver transplantation survival and aging successfully

Francesco Pollicino,<sup>1</sup> Ligia J. Dominguez,<sup>1,2</sup> Mario Barbagallo<sup>1</sup>

<sup>1</sup>Geriatric Unit, Department of Internal Medicine and Geriatrics, University of Palermo; <sup>2</sup>Faculty of Medicine and Surgery, Kore University, Enna, Italy

## Abstract

The traditional definition of successful aging as the absence of disease, disability, and cognitive impairment is not always applicable to patients with long survival despite complex multimorbidity. This case report details the situation of an 87-year-old man,

currently partially self-sufficient and partially autonomous, without cognitive impairment, who has been affected with recurrent right knee osteomyelitis since the age of 6. A diagnosis of hepatitis C virus (HCV)-related liver cirrhosis at 41 led to liver transplantation at 56. The immunosuppressive anti-rejection therapy caused a relapse of chronic osteomyelitis and HCV infection, a major cause of graft loss and shortened survival in HCV liver transplant recipients. Other pathologies were also diagnosed during his lifetime. This patient is an example of aging successfully despite complex multimorbidity and disproves the traditional concept of successful aging formerly described in the literature.

Correspondence: Ligia J. Dominguez, Geriatric Unit, Department of Internal Medicine and Geriatrics, University of Palermo, Viale F. Scaduto 6/c, 90144 Palermo, Italy.  
Tel. +39 0916554828.  
Fax: +39 0916552952.  
E-mail: ligia.dominguez@unipa.it

Key words: aging; liver transplantation; chronic disease; multimorbidity; successful aging.

Contributions: FP, LJD, MB, participated in the writing of the paper. All authors contributed equally.

Conflict of interest: the authors declare no potential conflict of interest.

Ethics approval and consent to participate: no ethics committee approval was required for this case report by the Department.

Patient consent for publication: the patient signed an informed consent for the publication of this case report.

Availability of data and materials: data and materials are available by the authors.

Acknowledgments: the authors would like to thank the patient and his family for their generous collaboration to undergo the present evaluation and for providing comprehensive information for the case presentation.

Received: 5 December 2022.  
Accepted: 3 March 2023.

Publisher's note: all claims expressed in this article are solely those of the authors and do not necessarily represent those of their affiliated organizations, or those of the publisher, the editors and the reviewers. Any product that may be evaluated in this article or claim that may be made by its manufacturer is not guaranteed or endorsed by the publisher.

©Copyright: the Author(s), 2023  
Licensee PAGEPress, Italy  
Geriatric Care 2023; 9:11066  
doi:10.4081/gc.2023.11066

This work is licensed under a Creative Commons Attribution-NonCommercial 4.0 International License (CC BY-NC 4.0).

## Introduction

We present the case of an older adult with a long history of chronic disease and long survival from liver transplantation. Starting from childhood up until today, his life has been characterized by the onset of several pathologies. Chronic osteomyelitis, probably post-traumatic, since the age of 6, and orthotopic liver transplantation at 56 are the two main events of his complex clinical history, in addition to various other pathologies. Despite the presence of multimorbidity, he maintains good levels of autonomy, self-sufficiency, and cognitive functions at 87 years old—81 of which were spent with chronic osteomyelitis—and 31 years post-transplantation. Despite multimorbidity, which refers to the simultaneous presence of two or more chronic diseases, this is a case of successful aging,<sup>1,2</sup> and prolonged survival after transplantation, which represents a high-risk factor for developing frailty and disability in old age.<sup>3</sup> Frailty is a condition of high risk for adverse health outcomes, including mortality, institutionalization, falls, and hospitalization. Fried *et al.* showed that over two-thirds of older adults with frailty have multimorbidity, while less than one-fifth of those with multimorbidity is also frail.<sup>4</sup>

## Case report

Initially, an accurate personal and pathological medical history of the patient was collected based on his unconditional collaboration and the available health documentation. A first-level comprehensive geriatric assessment was performed, with an estimation of activities of daily living (ADL), instrumental ADL (IADL), and mini-mental state examination (MMSE). In addition, a review of the literature on the topics of aging and successful aging was conducted.

The patient is an 87-year-old man, born in 1934, currently partially self-sufficient (ADL 4/6) and partially autonomous (IADL 6/8) (Table 1), without cognitive impairment (MMSE 25/30) (Table 2). Considering that two of the instrumental activities are not usually performed by men of his generation (gender bias), he

may be considered fully autonomous. He lives at home with his wife, smoked one cigarette a day for 30 years in the past, and now, he drinks a glass of wine with the main meals, as part of a traditional Mediterranean dietary pattern. At age 6, he underwent an accidental fall causing trauma to the right knee. After five months, he presented fever and pain at the trauma site; thus, an orthopedic surgeon, suspecting osteomyelitis, performed surgical bone curettage with partial removal of a tibial segment. The surgery determined a difference in the length of the lower limbs, which predictably led to limping. The surgery was transiently successful as the infection became chronic. Despite the persistence of the disease, he actively participated in university politics and concluded his studies with a degree in Literature and Philosophy in 1958. He underwent multiple surgical bone curettages and a right knee arthrodesis in the same year.

In 1974, he suffered a fracture in the same knee and underwent

a new surgery. Two years later, at the age of 41, he was diagnosed with hepatitis C virus (HCV)-related liver cirrhosis, for which he started follow-up at a gastroenterology department. It was suggested that HCV-infection was contracted as a result of repeated blood transfusions during previous hospitalizations and surgeries. It is worth remembering that, at that time, the search for the presence of hepatotropic viruses was not regularly practiced. In 1985, he was diagnosed with type 2 diabetes mellitus, later complicated by diabetic neuropathy.

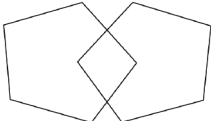
In 1991, liver transplantation from a deceased donor was performed in Lyon (France), with subsequent recurrence of the HCV infection. Up until now, the patient has continuously received immunosuppressive therapy with cyclosporine. During the transplantation period, the patient remained hospitalized for five months in Lyon and then had a period of ambulatory convalescence assisted by medical staff. In 1992, he actively participated in

**Table 1.** Results of the current estimation of the ability to perform instrumental activities of daily living and basic activities of daily living of our patient.

IADL	Patient's score	Maximum score	ADL	Patient's score	Maximum score
Using the telephone	1	1	Dressing	1	1
Moving within the community	1	1	Toilet hygiene	1	1
Shopping	1	1	Transferring <sup>b</sup>	1	1
Preparing meals	1	1	Continence	0	1
Housekeeping <sup>a</sup>	0	1	Self-feeding	1	1
Laundry <sup>a</sup>	0	1	Bathing and showering	0	1
Autonomy for taking prescribed medications	1	1			
Managing money	1	1			
Total	6	8	Total	4	6

<sup>a</sup>These activities are not performed usually by men of his generation (gender bias). Therefore, he may be considered fully autonomous. <sup>b</sup>As measured by the ability to walk, get in and out of bed, and get on and up from a chair. IADL, instrumental activities of daily living; ADL, activities of daily living.

**Table 2.** Results of the current estimation of cognitive performance with mini-mental state examination of our patient.

Maximumscore	Patient's score	Questions
5	5	What is the year? Season? Date? Day of the week? Month?
5	5	Where are we now: state? Country? Town/city? Hospital? Floor?
3	3	The examiner names three unrelated objects clearly and slowly, then asks the patient to name all three of them. The patient's response is used for scoring. The examiner repeats them until the patient learns all of them, if possible.
5	3	I would like you to count backward from 100 by sevens. (93, 86, 79, 72, 65, ...) Stop after five answers Alternative: spell WORLD backward. (D_L_R_O_W)
3	0	Earlier I told you the name of three things. Can you tell me what those were?
2	2	Show the patient two simple objects, such as a wristwatch and a pencil, and ask the patient to name them.
1	1	Repeat the phrase: ¢No ifs, ands, or buts¢.
3	3	Take the paper in your right hand, fold it in half, and put it on the floor. (The examiner gives the patient a piece of blank paper).
1	1	Please read this and do what it says. (Written instruction is 'close your eyes').
1	1	Make up and write a sentence about anything. (This sentence must contain a noun and a verb).
1	1	Please copy this picture. (The examiner gives the patient a blank piece of paper and asks him/her to draw the picture below. All 10 angles must be present and two must intersect).
		
30	25	Total

the foundation of the Sicilian Association for Liver Transplantation (ASTRAFE), with the participation of physicians, transplanted patients, and patients with cirrhosis on list for the procedure. The association aims to provide a guide for liver transplantation candidates or those who already have undergone transplantation. A remarkable success of this association was the support given to the foundation of the Mediterranean Institute for Transplantation and Highly Specialized Therapies in the city of Palermo, the first transplantation hospital founded in southern Italy.

After the transplantation and subsequently, at the start of the immunosuppressive therapy, chronic osteomyelitis resumed with the formation of a skin fistula secreting purulent material, from which *Escherichia Coli* has been repeatedly isolated (last isolation in 2020), with consequently repeated antibiotic therapies. In 2002, he was diagnosed with prostate adenocarcinoma with signs of perineural invasion (Gleason score 4+4), for which he underwent several therapeutic cycles with bicalutamide. During this period, arterial hypertension was diagnosed. In 2012, he had an acute myocardial infarction treated with percutaneous coronary intervention on the anterior interventricular artery. The coronary angiography was suggestive of three-vessel disease. In March 2013, he underwent another surgery for his chronic osteomyelitis and fistulization in the right knee arthrodesis with signs of chronic venous insufficiency of both lower limbs. In the same period, he was diagnosed with chronic renal failure of multifactorial etiology (in 2020 kidney disease improving global outcomes G3B). In 2014, atrial fibrillation was diagnosed, and it was initially treated with warfarin, with some management difficulties, and metoprolol, then replaced by rivaroxaban and sotalol, respectively. Rivaroxaban caused repeated bleeding from the fistula. In 2016, the patient underwent surgery to perform percutaneous closure of the left auricula (left atrial appendage occlusion). In the same year, due to the recurrence of HCV, twelve therapeutic cycles with sofosbuvir and ledipasvir were prescribed. Hyperuricemia was treated with allopurinol.

In 2018, during a cardiology visit, an echocardiogram evidenced severe tricuspid insufficiency and heart failure with a mildly reduced ejection fraction (40-45%). He also had episodes of urinary tract infections (isolation of *Proteus mirabilis* in 2020) that were responsive to antibiotic therapy.

## Discussion and Conclusions

Aging is characterized by progressive and broadly predictable changes that are associated with increased susceptibility to numerous diseases. Aging is not a homogenous process; on the contrary, it is very heterogeneous from person to person, and even organs in the same person age at different rates because they are influenced by multiple factors, including genetic make-up, lifestyle choices, and environmental exposures.<sup>5</sup> Rowe and Kahn proposed a distinction between *usual aging* (normal decline in physical, social, and cognitive functioning with age, heightened by extrinsic factors) and *successful aging*, in which functional loss is minimized (little or no age-related decrement in physiological and cognitive functioning, with extrinsic factors playing a neutral or positive role). Traditionally, successful aging is considered multidimensional, encompassing the avoidance of disease and disability, the maintenance of high physical and cognitive function, and sustained engagement in social and productive activities.<sup>1</sup> Predictors of high functional status in both physical and cognitive domains were evaluated in 1677 participants from the longitudinal cardiovascular health study followed for 14 years (median age 85 at endpoint). High baseline function and low vascular disease risk characterized by functional aging.<sup>6</sup> Another study showed that the strongest pre-

dictor of successful aging was the socioeconomic position at midlife. After adjustment of socioeconomic factors, not smoking, a healthy diet, exercise, moderate alcohol intake (in women), and work support (in men), healthy aging was predicted.<sup>7</sup> Indeed, longevity is mainly conditioned by genetic, epigenetic, and environmental factors.<sup>8</sup> Kim and Park conducted a meta-analysis of the correlations of successful aging and identified four domains describing it: i) avoiding disease and disability; ii) having high cognitive, mental, and physical function; iii) being actively engaged in life; iv) being psychologically well adapted in later life.<sup>2</sup> Successful aging is undermined by disorders such as depression. The causes of depression include detachment from family members, relatives, and friends; pathologies; female sex; physical and cognitive impairment; insomnia; and multimorbidity.<sup>9</sup> In another study, successful aging was also associated with an MMSE score of at least 24/30 and a geriatric depression scale scoring in the normal range.<sup>10</sup>

The patient presented here is an example of successful aging, or maybe it would be better to say *aging successfully*. He maintains good levels of self-sufficiency, autonomy, and cognitive functions despite 31 years of liver transplantation and multimorbidity, including recurrence of the HCV infection, a major cause of graft loss and shortened survival in HCV liver transplant recipients.<sup>11</sup> The peculiarity of this case is the fact that these results are achieved in the presence of various pathologies; therefore, in the absence of one of the cornerstones of the traditional concept of successful aging formerly described by Rowe and Kahn,<sup>1</sup> and Kim and Park.<sup>2</sup> Young *et al.* argued that chronic illnesses and diseases can coexist with successful aging,<sup>12</sup> as confirmed by the present case.

Multiple pathologies have characterized the course of our patient's life since childhood. Osteomyelitis persists throughout life. It can be classified based on the mechanism of infection (hematogenous vs non-hematogenous) and the duration of illness (acute vs chronic).<sup>13</sup> Osteomyelitis established a relevant physical impairment for the patient, first as a consequence of the right lower limb shortening from the age of 6, and then due to the arthrodesis of the right knee from the age of 24. These conditions did not affect his university career and the possibility of raising his family. In failure to achieve a maximum ADL, only 2 points are lost, but an important role is played by the joint deficit given by the right knee arthrodesis, which certainly hinders his movements and slightly reduces self-sufficiency. Therefore, in the absence of bone problems, these indices would be even better. As explained above, he can be considered autonomous in IADL.

An important pathology is HCV-related cirrhosis, treated with liver transplantation, which is the only curative intervention for terminal liver disease with evidence of improving long-term quality of life when compared to the pre-transplantation phase.<sup>14</sup> Our patient is an extraordinary example of long survival after liver transplantation with high quality of life and good autonomy, self-sufficiency, and cognitive performance, despite the comorbidities and sequelae of the transplant. Post-transplant immunosuppressive therapy with cyclosporine may have resulted in the reactivation of osteomyelitis and may have contributed to the onset of renal failure. Chronic renal failure is a recognized complication of post-transplantation immunosuppressive therapy.<sup>15</sup> Prolonged immunosuppression causes the reactivation of prior infections, newly acquired infections, metabolic disorders (hypertension, diabetes, dyslipidemia, obesity), and *de novo* hepatic or extrahepatic malignancies, including post-transplant lymphoproliferative diseases. Cardiovascular and renal failure are the leading non-hepatic causes of morbidity and mortality in the long term after liver transplantation.<sup>16</sup>

Calcineurin-inhibitor therapy (*i.e.*, cyclosporine and tacrolimus)

has been implicated as a principal cause of post-transplantation renal dysfunction, which may lead to severe tubular atrophy, interstitial fibrosis, and focal hyalinosis of small renal arteries and arterioles. In addition, renal disease before transplantation, perioperative hemodynamic insults to the kidneys, nephrotoxic effects of other drugs, dyslipidemia, hypertension, and diabetes can contribute to chronic renal failure in recipients of non-renal organs.<sup>17</sup> Cyclosporine, hypertension, and diabetes mellitus are three relevant risk factors of chronic renal failure in our patient. Moreover, diabetes has been associated with a higher risk of liver graft rejection.<sup>18</sup>

Social and cognitive functions are cornerstones of successful aging and are found preserved in our patient. During his university studies, he participated in politics and, as mentioned above, after the transplant, he had an active role in the foundation of ASTRAFE. Good social functioning is often indicated as an important factor in successful aging,<sup>19</sup> while some studies have shown that life satisfaction, purpose in life, perception of the aging process, and adaptation in later life may also contribute.<sup>20</sup> The expression *aging successfully* should be used to distinguish those older people who have overcome/manage disease and disability resulting in an active and high-quality third age.<sup>19</sup> Slight alterations of cognitive faculties may not significantly worsen the quality of life in old age, as evidenced by the MMSE of our case, obtaining a score of 25/30 (in the normal range for his age).

## References

- Rowe JW, Kahn RL. Successful aging. *Gerontologist* 1997;37:433-40.
- Kim SH, Park S. A meta-analysis of the correlates of successful aging in older adults. *Res Aging* 2017;39:657-77.
- Vetrano DL, Palmer K, Marengoni A, et al. Frailty and multimorbidity: a systematic review and meta-analysis. *J Gerontol A Biol Sci Med Sci* 2019;74:659-66.
- Fried LP, Tangen CM, Walston J, et al. Frailty in older adults: evidence for a phenotype. *J Gerontol A Biol Sci Med Sci* 2001;56:M146-56.
- Blokzijl F, de Ligt J, Jager M, et al. Tissue-specific mutation accumulation in human adult stem cells during life. *Nature* 2016;538:260-4.
- Newman AB, Arnold AM, Sachs MC, et al. Long-term function in an older cohort—the cardiovascular health study all stars study. *J Am Geriatr Soc* 2009;57:432-40.
- Britton A, Shipley M, Singh-Manoux A, et al. Successful aging: the contribution of early-life and midlife risk factors. *J Am Geriatr Soc* 2008;56:1098-105.
- Costa D, Scognamiglio M, Fiorito C, et al. Genetic background, epigenetic factors and dietary interventions which influence human longevity. *Biogerontology* 2019;20:605-26.
- Cole MG, Dendukuri N. Risk factors for depression among elderly community subjects: a systematic review and meta-analysis. *Am J Psychiatry* 2003;160:1147-56.
- Almeida OP, Norman P, Hankey G, et al. Successful mental health aging: results from a longitudinal study of older Australian men. *Am J Geriatr Psychiatry* 2006;14:27-35.
- Fayek SA, Quintini C, Chavin KD, Marsh CL. The current state of liver transplantation in the United States: a perspective from american society of transplant surgeons (ASTS) scientific studies committee and endorsed by ASTS council. *Am J Transplant* 2016;16:3093-104.
- Young Y, Frick KD, Phelan EA. Can successful aging and chronic illness coexist in the same individual? A multidimensional concept of successful aging. *J Am Med Dir Assoc* 2009;10:87-92.
- Schmitt SK. Osteomyelitis. *Infect Dis Clin North Am* 2017;31:325-38.
- Yang LS, Shan LL, Saxena A, Morris DL. Liver transplantation: a systematic review of long-term quality of life. *Liver Int* 2014;34:1298-313.
- Barrera Pulido L, Alamo Martínez JM, Pareja Ciuró F, et al. Efficacy and safety of mycophenolate mofetil monotherapy in liver transplant patients with renal failure induced by calcineurin inhibitors. *Transplant Proc* 2008;40:2985-7.
- Lucey MR, Terrault N, Ojo L, et al. Long-term management of the successful adult liver transplant: 2012 practice guideline by the american association for the study of liver diseases and the american society of transplantation. *Liver Transpl* 2013;19:3-26.
- Ojo AO, Held PJ, Port FK, et al. Chronic renal failure after transplantation of a nonrenal organ. *N Engl J Med* 2003;349:931-40.
- Ramos-Pro A, Hervás-Marín D, García-Castell A, Merino-Torres JF. Outcomes in patients with diabetes 10 years after liver transplantation. *J Diabetes* 2017;9:1033-9.
- Morley JE. Aging successfully: the key to aging in place. *J Am Med Dir Assoc* 2015;16:1005-7.
- Kivimäki M, Ferrie JE. Epidemiology of healthy aging and the idea of more refined outcome measures. *Int J Epidemiol* 2011;40:845-7.