

Acute pancreatitis associated with massive paraesophageal hernia involving the presence of the pancreatic body and tail

Bahjat Barakat,¹ Lucia Calculli,² Raffaele Pezzilli³

¹Emergency Department; ²Department of Radiology; ³Department of Gastroenterology, Sant'Orsola-Malpighi Hospital, Bologna, Italy

Abstract

Acute pancreatitis is an acute inflammation of the pancreas and, according to the 2013 Revised Atlanta Classification, the majority of cases have only a mild clinical course without organ dysfunction. The primary objectives in the treatment of acute pancreatitis are essentially relief of pain, electrolyte and fluid support and energy intake other than removal of the causal agent. Even if in Italy gallstones especially are the predominant etiological factor, there are also less frequent causes associated with acute pancreatitis and we believe that the case of acute pancreatitis associated with massive incarcerated paraesophageal hernia involving the presence of the body and tail of the pancreas in the thorax is worth reporting.

Introduction

Acute pancreatitis is an acute inflammation of the pancreas and, according to the Revised Atlanta Classification released in 2013 it is classified as mild (no presence of organ dysfunction), moderate (with transient less than <48 hours organ dysfunction) or severe (with persistent organ dysfunction).¹ The primary objectives in the treatment of acute pancreatitis are essentially: pain control, electrolyte and fluids support, energy intake, and removal of the causal agent, attenuation of inflammation, and prevention and eventual treatment of local and systemic complications in necrotiz-

ing forms.² Gallstones are the predominant etiological factor especially in Italy followed by alcohol abuse.³ However, there are also less frequent causes associated with acute pancreatitis and we believe that the case we describe is worth reporting.

Case Report

A 27-year-old male was admitted to our Emergency Room (ER) suffering from extensive abdominal pain which was dull and crampy in nature and associated with nausea and episodes of vomiting without blood. On the four days prior to admission, the pain with the same characteristics had been spasmodic but, after physical exertion in the swimming pool became continuous and intense with a value of eight on the visual analogue scale from 0-10.⁴ His past medical history was unremarkable. In ER, blood pressure was normal (120-80 mm/Hg), temperature was 36°C, heart rate 78 bpm, respiratory rate 18, O₂ saturation 90% in ambient air. On physical examination the abdomen was soft with mild epigastric tenderness and normal bowel sounds. Both cardiovascular and pulmonary examinations were normal. Blood tests revealed an increase of WCC (23,340 mmc), amylase 677 U/L (upper reference limit 100 U/L), lipase 1,602 U/L (upper reference limit 67 U/L); liver and kidney functions were normal as were serum electrolytes and C-reactive protein level. Chest and abdominal x-rays revealed the presence of a large hiatal hernia containing some intestinal loops in the thorax (Figure 1A); marked gastric dilation was also present (Figure 1B). Thorax and abdominal contrast enhanced computed tomography was performed confirming the hiatal hernia, the presence of the stomach with air fluid level, the first part of the duodenum, spleen, body and tail of the pancreas in the thorax (Figure 2); a peripancreatic fluid collection was also present. Laboratory and imaging examinations were highly compatible with acute pancreatitis. The APACHE II score was less than 8 and the pancreatitis was classified as clinically mild.⁵ The patient underwent medical treatment with fluids and analgesics for the first 48 hours and the pain progressively subsided; subsequently a surgical approach was carried out consisting of the reduction of viscera in the abdomen and the reconstruction of the diaphragm by direct plastic surgery. The patient's clinical course was uneventful (Figure 3) and one year after, he had no further attacks of pancreatitis.

Correspondence: Raffaele Pezzilli, Department of Gastroenterology, Sant'Orsola-Malpighi Hospital, Via Massarenti 9, 40138 Bologna, Italy. E-mail: raffaele.pezzilli@aosp.bo.it

Key words: Acute pancreatitis; Type IV paraesophageal hernia; Computed tomography.

Contributions: the authors contributed equally.

Conflict of interest: the authors declare no potential conflict of interest.

Funding: none.

Received for publication: 12 June 2018.

Revision received: 30 October 2018.

Accepted for publication: 2 November 2018.

This work is licensed under a Creative Commons Attribution 4.0 License (by-nc 4.0).

©Copyright B. Barakat et al., 2018
Licensee PAGEPress, Italy
Emergency Care Journal 2018; 14:7617
doi:10.4081/ecj.2018.7617

Discussion

We have reported a rare case of a massive incarcerated paraesophageal hernia involving the presence of the stomach, the first part of the duodenum, the spleen and the body and tail of the pancreas in the thorax causing acute pancreatitis. The past medical history of the patient was unremarkable, thus it is impossible to say whether he had a congenital Bockdaleck or a hiatal hernia.

Anyway, the pathogenesis resulted from the obstruction of the distal pancreatic duct after displacement of the pancreatic head and body into the thorax as part of a type IV paraesophageal hernia.⁶ The traction on the pancreas, due to acute distension and volvulus of the stomach, might have had also a role in the genesis of pancreatitis.⁷ Hiatal hernias are usually classified into the following types depending on the extent of herniation and the position of the gastroesophageal junction: type I, sliding hernias; type II, paraesophageal hernias; type III, mixed sliding and paraesophageal hernia (with elements of both types I and II) and type IV, herniation of

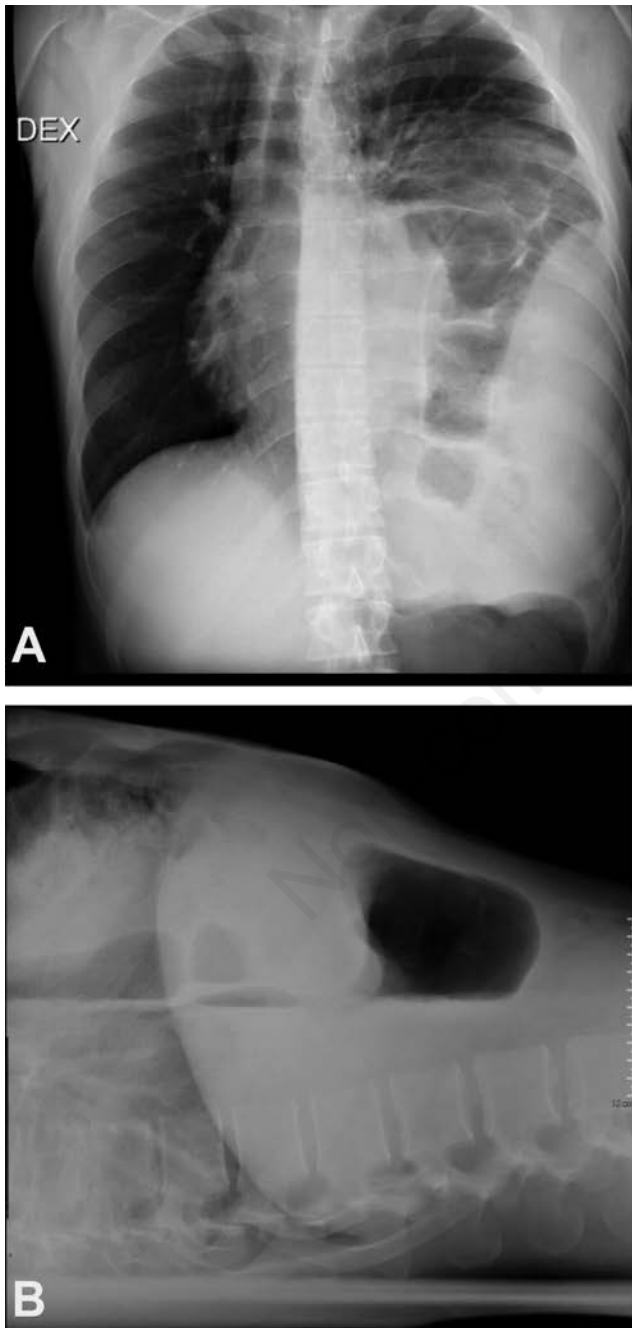


Figure 1. (A) Chest x-ray showing the presence of the bowel in the mediastinum; (B) Chest x-ray presence of gastric air bubble in the thorax.

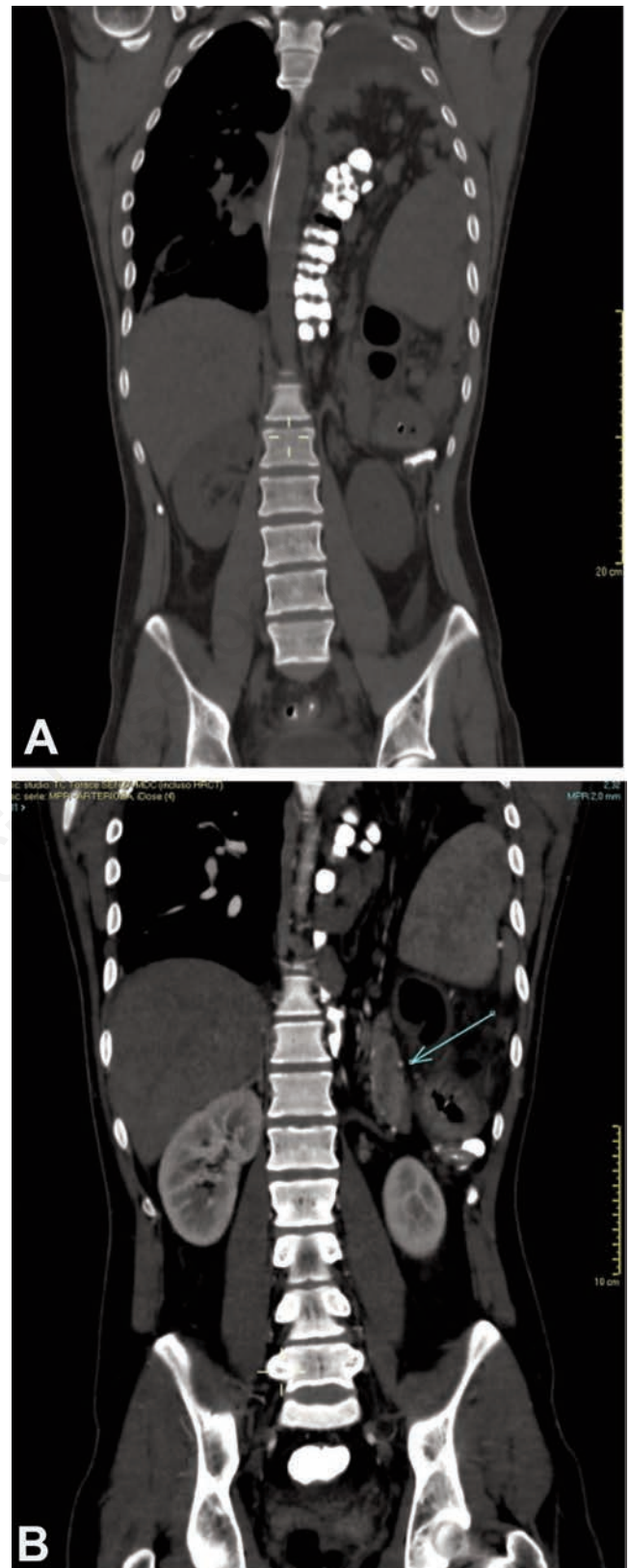


Figure 2. Contrast-enhanced computed tomography, coronal plane. (A) Hiatal hernia; (B) herniation of the stomach, the body and tail of the pancreas (arrow), and the first part of the duodenum.

additional organs (such as colon, spleen, pancreas and small intestine, which enter the hernia sac).^{8,9} Type IV paraesophageal hernias account for 0.1% of all types of hiatal hernias¹⁰ and it is also known as giant hiatal hernia. Our patient initially underwent medical treatment according to the guidelines on acute pancreatitis.² Subsequently, to remove the cause of further pancreatitis attacks we decided to operate in order to repair the hernia according to the guidelines which suggest that all symptomatic paraesophageal hiatal hernias should be repaired and this constitutes a strong evidence.⁶ Post-surgery imaging showed how successful the operation had been. Complications such as volvulus, occlusion, ischemia, or even perforation can, however, occur.^{8,11} Some cases of this rare cause of acute pancreatitis have been reported in literature in the past.¹²⁻²⁴ Migration of pancreas in the thorax has been also reported not associated with acute pancreatitis²⁵⁻²⁹ or with symptoms of mechanical cholestasis such as mild jaundice, pruritus, diarrhea and fatigue.³⁰ In the majority of cases a herniated pancreas may be the body and the tail and in fewer cases the tail alone. Standard pre-operative investigations include a CT scan of the chest/abdomen,^{12,18,20,22,23} magnetic resonance of the abdomen,²⁴ an upper gastrointestinal contrast study and upper gastrointestinal endoscopy.^{31,32} Magnetic resonance may offer the opportunity to investigate the pancreatic and bile ducts in these rare cases.²⁴ The

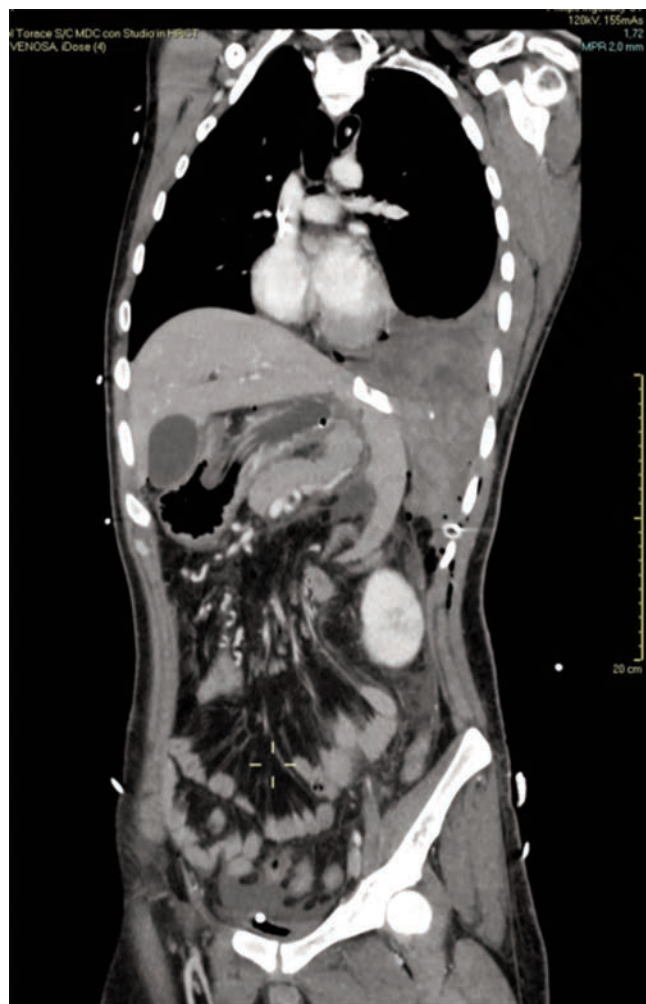

Figure 3. Contrast-enhanced computed tomography, coronal plane: imaging after surgical repair of the hernia.

Table 1. Clinical characteristics of the reported cases of acute pancreatitis associated with hiatal hernia.

Year of publication	Author	Reference	Year of publication	Gender	Age	Type of herniation	Type of pancreatitis*	Treatment	Outcome at discharge	Recurrence of pancreatitis in the follow up
1981	Cuschieri and Wilson ¹²	12	1981	Male	19	Bochdalek hernia	Severe	Surgical	Alive	NR
1990	Oliver <i>et al.</i> ¹³	13	1990	Male	5	Bochdalek hernia	Mild	Surgical	Alive	NR
1994	Kafka <i>et al.</i> ¹⁴	14	1994	Female	71	Paraesophageal hernia	Severe	Surgical	Alive	NR
2007	Tagaya <i>et al.</i> ¹⁷	17	2007	Female	68	Paraesophageal hernia	Mild	Surgical	Alive	No after 29 months
2010	Maksoud <i>et al.</i> ¹⁶	16	2010	Male	68	Paraesophageal hernia	Severe	Surgical	Alive	No (unspecified period of time)
2010	Rozas and González ¹⁹	19	2010	Female	78	Hiatal hernia	Severe	Medical	Alive	No at 6 months
2014	Boyce <i>et al.</i> ²⁰	20	2014	Female	61	Paraesophageal hernia	Mild	Surgical	Alive	NR
2015	Lu <i>et al.</i> ²¹	21	2015	Male	88	Paraesophageal hernia	Mild	Medical	Alive	Yes after one month
2016	Patel <i>et al.</i> ²²	22	2016	Male	65	Hiatal hernia	Mild	Medical	Alive	NR
2017	Shafiq <i>et al.</i> ²³	23	2017	Female	90	Hiatal hernia	Mild	Medical	Alive	NR
2017	Wang <i>et al.</i> ¹⁷	24	2017	Female	102	Hiatal hernia Type IV	Mild	Medical	Alive	NR
2018	Do <i>et al.</i> ⁷	7	2018	Male	65	Paraesophageal hernia	Mild	Medical	Alive	NR
2018	Present case		2018	Male	27	Paraesophageal hernia	Mild	Surgical	Alive	No after 1 year

*According to the revised Atlanta criteria.¹

causes postulated for acute pancreatitis are repetitive trauma associated with pancreatic movement across the hernia, ischemic compromise of the vascular pedicle, and intermittent folding of the main pancreatic duct.^{12,13,18} The majority of patients have undergone surgery to repair their hernia and only a small number of patients have undergone conservative treatment as they have refused surgery.^{19,22-24}

Conclusions

In conclusion, this is rare case of acute pancreatitis may be due to an incarcerated paraesophageal hernia involving the presence of the pancreas. As reported in Table 1, the association of acute pancreatitis and hiatal hernia is very rare; to our best knowledge only 13 cases have been reported in literature and their number increases over the years; there were mainly patients of advanced age and the clinical course of pancreatitis was usually mild, according to the revised Atlanta criteria.¹ However, the causes of acute pancreatitis are not well-defined and may be due to repetitive trauma associated with pancreatic movement across the hernia, ischemic pancreatitis secondary to the vascular pedicle and intermittent folding of the main pancreatic duct. A conservative treatment is the preferred therapeutic approach in acute pancreatitis, but when the condition has a mechanical cause the possibility of emergency surgery should also be considered, in order to prevent both the consequences of a prolonged pulmonary collapse and further pancreatitis attacks.

References

1. Banks PA, Bollen TL, Dervenis C, et al. Acute pancreatitis classification working group. classification of acute pancreatitis-2012: revision of the Atlanta classification and definitions by international consensus. *Gut* 2013;62:102-11.
2. Pezzilli R, Zerbi A, Di Carlo V, Working Group of the Italian Association for the Study of the Pancreas on Acute Pancreatitis. Practical guidelines for acute pancreatitis. *Pancreatol* 2010;10:523-535.
3. Pezzilli R, Uomo G, Gabbriellini A, ProInf-AISP Study Group. A prospective multicenter survey on the treatment of acute pancreatitis in Italy. *Dig Liver Dis* 2007;39:838-46.
4. Scott J, Huskisson EC. Graphic representation of pain. *Pain* 1976;2:175-84.
5. Pezzilli R, Zerbi A, Campra D, et al. Consensus guidelines on severe acute pancreatitis. *Dig Liver Dis* 2015;47:532-43.
6. Kohn GP, Price RR, Demeester S, SAGES Guidelines Committee. The Society of American Gastrointestinal and Endoscopic Surgeons (SAGES). Guidelines for the Management of Hiatal Hernias. Available from: <http://www.sages.org/publications/guidelines/guidelines-for-the-management-of-hiatal-hernia/>. Accessed: June 2, 2018.
7. Do D, Mudroch S, Chen P, et al. A rare case of pancreatitis from pancreatic herniation. *J Med Cases* 2018;9:154-6.
8. Mitiek MO, Andrade RS. Giant hiatal hernia. *Ann Thorac Surg* 2010;89:S2168-73.
9. Awais O, Luketich JD. Management of giant paraesophageal hernia. *Minerva Chir* 2009;64:159-68.
10. Maish MS, DeMeester SR. Paraesophageal hernia. In: Cameron JL, ed. *Current surgical therapy*. 8th ed. Philadelphia: Saunders; 2004. p 38.
11. Rade F, Lefevre JH. Giant hiatal hernia with biliopancreatic duct dilatation. *Am Surg* 2012;78:E534-5.
12. Cuschieri RJ, Wilson WA. Incarcerated Bochdalek hernia presenting as acute pancreatitis. *Br J Surg* 1981;68:668-9.
13. Oliver MJ, Wilson AR, Kapila L. Acute pancreatitis and gastric volvulus occurring in a congenital diaphragmatic hernia. *J Paediatr Surg* 1990;25:1240-1.
14. Kafka NJ, Leitman IM, Tromba J. Acute pancreatitis secondary to incarcerated paraesophageal hernia. *Surgery* 1994;115:653-5.
15. Saxena P, Konstantinov IE, Koniuszko MD, et al. Hiatal herniation of the pancreas: diagnosis and surgical management. *J Thorac Cardiovasc Surg* 2006;131:1204-5.
16. Maksoud C, Shah AM, DePasquale J, et al. Transient pancreatic hiatal herniation causing acute pancreatitis. A literature review. *Hepatogastroenterology* 2010;57:165-6.
17. Tagaya N, Tachibana M, Kijima H, et al. Laparoscopic treatment of paraesophageal hiatal hernia with incarceration of the pancreas and jejunum. *Surg Laparosc Endosc Percutan Tech* 2007;17:313-6.
18. Chevallier P, Peten E, Pellegrino C, et al. Hiatal hernia with pancreatic volvulus: a rare cause of acute pancreatitis. *AJR Am J Roentgenol* 2001;177:373-4.
19. Rozas MG, González MM. A rare complication of hiatal hernia. *Gastroenterology* 2010;139:e1-e2.
20. Boyce K, Campbell W, Taylor M. Acute pancreatitis secondary to an incarcerated paraesophageal hernia: a rare cause for a common problem. *Clin Med Insights Case Rep* 2014;11:25-7.
21. Lu LX, Payne M, Theobald CN. Education and imaging. *Gastroenterology: Diaphragmatic herniation and pancreatitis*. *J Gastroenterol Hepatol* 2015;30:653.
22. Patel S, Shahzad G, Jawairia M, et al. Hiatus hernia: a rare cause of acute pancreatitis. *Case Rep Med* 2016;2016:2531925.
23. Shafiq M, Badshah MB, Badshah MB, et al. Pancreas herniation into the mediastinum: a case report. *BMC Res Notes* 2017;10:450.
24. Wang J, Thaker AM, Noor El-Nachef W, Watson RR. Transhiatal herniation of the pancreas: a rare cause of acute pancreatitis. *ACG Case Rep J* 2017;4:e66.
25. Coral A, Jones SN, Lees WR. Dorsal pancreas presenting as a mass in the chest. *AJR Am J Roentgenol* 1987;149:718-20.
26. Skinner DB, Belsey RH. Surgical management of esophageal reflux and hiatus hernia. Long-term results with 1,030 patients. *J Thorac Cardiovasc Surg* 1967;53:33-54.
27. Coughlin M, Fanous M, Velanovich V. Herniated pancreatic body within a paraesophageal hernia. *World J Gastrointest Surg* 2011;3:29-30.
28. Yildiz I. Asymptomatic pancreatic body herniation complicated with periauricular squamous cell carcinoma. *Eur J Radiol Open* 2018;5:64-6.
29. Banimostafavi ES, Tayebi M. Large hiatal hernia with pancreatic body herniation: Case-report. *Ann Med Surg (Lond)* 2018;28:20-2.
30. Jäger T, Neureiter D, Nawara C, et al. Intrathoracic major duodenal papilla with transhiatal herniation of the pancreas and duodenum: A case report and review of the literature. *World J Gastrointest Surg* 2013;5:202-6.
31. Bawahab M, Mitchell P, Church N, Debru E. Management of acute paraesophageal hernia. *Surg Endosc* 2009;23:255-9.
32. Khanna A, Finch G. Paraesophageal herniation: a review. *Surgeon* 2011;9:104-11.