

Emergency Care Journal

Official Journal of the [Academy of Emergency Medicine and Care](#) (AcEMC)



eISSN 2282-2054

<https://www.pagepressjournals.org/index.php/ecj/index>

**Publisher's Disclaimer.** E-publishing ahead of print is increasingly important for the rapid dissemination of science. The **Early Access** service lets users access peer-reviewed articles well before print / regular issue publication, significantly reducing the time it takes for critical findings to reach the research community. These articles are searchable and citable by their DOI (Digital Object Identifier).

The **Emergency Care Journal** is, therefore, e-publishing PDF files of an early version of manuscripts that undergone a regular peer review and have been accepted for publication, but have not been through the typesetting, pagination and proofreading processes, which may lead to differences between this version and the final one. The final version of the manuscript will then appear on a regular issue of the journal.

E-publishing of this PDF file has been approved by the authors.

Emerg Care J 2024 [Online ahead of print]

*To cite this Article:*

Piazzai F, Morelli G, Barone L, et al. **Efficacy of EFAST-PS in pelvic trauma for the assessment of the pubic symphysis in emergency settings: a mini review.** *Emerg Care J* doi: 10.4081/ecj.2024.12696

 ©The Author(s), 2024  
Licensee [PAGEPress](#), Italy

Note: The publisher is not responsible for the content or functionality of any supporting information supplied by the authors. Any queries should be directed to the corresponding author for the article.

All claims expressed in this article are solely those of the authors and do not necessarily represent those of their affiliated organizations, or those of the publisher, the editors and the reviewers. Any product that may be evaluated in this article or claim that may be made by its manufacturer is not guaranteed or endorsed by the publisher.



## **Efficacy of EFAST-PS in pelvic trauma for the assessment of the pubic symphysis in emergency settings: a mini review**

Federica Piazzai,<sup>1</sup> Gilda Morelli,<sup>2</sup> Lorenzo Barone,<sup>3</sup> Manuel Carli,<sup>4</sup> Chiara Borchini,<sup>5</sup> Moris Rosati,<sup>6</sup> Lorenzo Righi,<sup>1</sup> Sara Montemerani<sup>7</sup>

<sup>1</sup>Emergency Department, Azienda USL Toscana Sud Est; <sup>2</sup>Rehabilitation Facility, Istituto Anna Torrigiani; <sup>3</sup>Intensive Care Unit, Azienda USL Toscana Centro, Ospedale Santa Maria Annunziata; <sup>4</sup>Emergency Department, IRCCS Ospedale Sacro Cuore Don Calabria Negrar di Valpolicella; <sup>5</sup>IRCCS Don Carlo Gnocchi, Firenze; <sup>6</sup>Cardiology and Cardiac Intensive Care Unit, Azienda Ospedaliero Universitaria Senese, Siena; <sup>7</sup>Acceptance and Emergency Medicine and Surgery Unit, San Donato Hospital in Arezzo - Pegaso 2 Helicopter Service, Emergency Department, Azienda USL Toscana Sud Est, Italy

**Correspondence:** Moris Rosati Cardiology and Cardiac Intensive Care Unit, Azienda Ospedaliero Universitaria Senese, Siena, Italy.

Tel.: +393474972040

E-mail: moris.rosati@unisi.it

**Key words:** EFAST, FAST, EFAST-PS, trauma, pubic symphysis, pelvis, ultrasound, pelvic injuries, intra-abdominal bleeding, pelvic binder.

**Contributions:** FP, editing the manuscript; GM, editing the manuscript; LB, editing the manuscript; MC, editing the manuscript; CB, editing the manuscript; LR, writing of the manuscript; MR, reviewing of the manuscript; SM, reviewing of the manuscript.

**Conflict of interest:** the authors declare no potential conflict of interest, and all authors confirm accuracy.

**Ethics approval and consent to participate:** no ethical committee approval was required for this case report. Informed consent was obtained from the patient included in this study.

**Patient consent for publication:** the patient gave her written consent to use her personal data for the publication of this case report and any accompanying images.

**Availability of data and materials:** all data underlying the findings are fully available.

### **Highlights**

- The most widely used classification for pelvic fractures is the Young-Burgess classification, which categorizes pelvic injury based on the direction of impact in anteroposterior compression (APC), lateral compression (LC), vertical shear (VS), and combined mechanisms.
- Pelvic fractures are frequently associated with high-energy traumatic mechanisms. The mortality rate for pelvic injuries is consistently high because of the potential rupture of major blood vessels in the pelvic region, resulting in hemorrhagic shock.
- Pelvic circumferential compression device (PCCD) placement is indicated in two modalities: the compressive mode and the containment mode respectively in presence or absence of hemodynamic instability associated with anatomical and/or dynamic signs of pelvic injury.
- Extended Focused Assessment Sonography for Trauma E-FAST can reduce the time required for surgical treatment, improve understanding of trauma severity, and optimize patient management at the scene and during transport to the receiving hospital.
- Implementing the E-FAST protocol with pubic symphysis scans (EFAST-PS) can significantly improve the prognosis of trauma patients by reducing therapeutic times, improving the placement of the PCCD and optimizing their care pathway.
- The EFAST-PS exam is considered positive for an open book pelvic fracture if it detects a diastasis of more than 2.5 cm in transverse diameter between the two pubic tubercles.

## **Abstract**

The EFAST technique is a rapid ultrasound method introduced into ATLS guidelines since 2006 for the evaluation of trauma patients. It allows for the detection of free fluid in the abdomen, pericardial tamponade, and pneumothorax within 2 to 3 minutes without impacting management times in pre-hospital settings. Recently, the EFAST-PS protocol has been introduced, which includes an additional scan of the pubic symphysis to identify “open book” pelvic fractures. This mini review examines the efficacy of the EFAST-PS protocol in pre-hospital environments through a literature review and analysis of a clinical case. It is demonstrated that EFAST has high specificity and sensitivity in detecting free fluid in abdominal and thoracic recesses, improving the management of trauma patients and reducing time to definitive intervention. The addition of the pubic symphysis scan did not cause any issues but increased safety in managing patients with suspected fractures and hemodynamic instability. Emergency ultrasound assessment, including the EFAST-PS protocol, should be integrated into the overall clinical picture to provide useful data for the decision-making process.

## **Case Report**

A 40-year-old man was involved in a road accident following a fall from his motorcycle. The patient was found thrown against the guardrail. Upon the arrival of the emergency medical team, he was conscious but confused and agitated. The vital signs recorded by the first responders indicated a Blood Pressure (BP) of 70/40 mmHg, a Heart Rate (HR) of 42 bpm, and a peripheral oxygen saturation (SpO<sub>2</sub>) of 94% on room air.

After removing the helmet, the medical personnel proceeded with cervical spine immobilization and clinical evaluation of the patient. The patient exhibited a suspected spinal cord injury, indicated by paraplegia and loss of sensation in the trunk and both lower limbs from the nipple line downward. During the assessment of neurological sensitivity, the medical team detected the presence of a scrotal hematoma. Given the context and dynamics of the incident, a pelvic trauma was also suspected in addition to the spinal injury. This prompted the team to perform an extended Focused Assessment with Sonography for Trauma (EFAST) that included an ultrasound evaluation of the pubic symphysis, referred to as the EFAST-PS protocol. While the abdominal and thoracic scans were negative for free fluid and signs of pneumothorax (PNX), the scan of the pubic symphysis revealed diastasis of the tubercles (Figure 1), suggesting a probable open book pelvic fracture. This

made the placement of a pelvic circumferential compression device a priority, in addition to complete spinal immobilization on a backboard.

The patient received treatment with 1 g of tranexamic acid, fluid resuscitation with 250 ml boluses of saline solution, and an infusion of norepinephrine at 1 mcg/min to maintain a systolic blood pressure of at least 100 mmHg, considering the combination of spinal trauma and blunt trauma. The patient was then transferred to the designated trauma center. The whole-body CT scan performed upon arrival at the emergency department confirmed the presence of fractures involving the posterior wall of the thoracic vertebrae T3-T4 and an anteroposterior pelvic fracture with diastasis of the pubic symphysis, fracture of the right sacral wing, and diastasis of the anterior sacroiliac joints (Figure 2).

## **Discussion**

A significant portion of trauma-related mortality is avoidable and often results from errors in the initial diagnosis and delays in emergency interventions.<sup>1</sup> Approximately 30-40% of trauma mortality is caused by hemorrhages, with 33-56% occurring in the pre-hospital phase. In this clinical case, we went beyond the simple algorithmic execution of the EFAST and included the evaluation of the pubic symphysis in addition to the standard scans. The goal was to identify the possible presence of an Anteroposterior Compression (APC) type pelvic fracture within seconds. This technique, developed in the early 2000s, involves using a high-frequency linear probe to scan the pubic symphysis. Cases reported in the literature<sup>2-4</sup> define a maximum normal distance of 2.5 cm between the pubic tubercles. A diastasis of more than 2.5 cm in transverse diameter between the two pubic tubercles is considered positive for an open book pelvic fracture from anteroposterior compression (often associated with the rupture of the sacrospinous and sacroiliac ligaments and rupture of the pelvic vessels).

The use of this new scan likely prevented a potential hemodynamic deterioration of the patient during mobilization in the absence of a Pelvic Circumferential Compression Device (PCCD). The ability to perform diagnostic screening for an APC fracture directly in the pre-hospital setting improved patient management, providing healthcare professionals with greater confidence in their assessment. Pelvic screening allowed recalibration of the reference blood pressure target and reconsideration of the patient's clinical status, who, in addition to a spinal trauma with spinal shock, also had a probable hemorrhagic focus associated with the open book pelvic fracture.

## ***Pelvic fractures***

Pelvic fractures account for approximately 2%-8% of skeletal injuries,<sup>5</sup> frequently associated with high-energy traumatic mechanisms. The primary risk factors include motor vehicle accidents and falls from significant heights. The mortality rate for pelvic injuries can reach up to 50% due to the potential rupture of major blood vessels in the pelvic region, resulting in hemorrhagic shock.<sup>6,7</sup> Indeed, the anatomical proximity of major vascular structures to the pelvis, the concomitant visceral damage, and the high forces required to disrupt pelvic integrity predispose pelvic injuries to hemodynamic instability. The most widely used classification for pelvic fractures is the Young-Burgess classification, which categorizes pelvic injury based on the direction of impact during the trauma and the degree of bone displacement, distinguishing among APC, Lateral Compression (LC), Vertical Shear (VS), and combined mechanisms.

Type I-II-III APC fractures are associated with shock in 30-67% of cases, with a mortality incidence of 15-37%; hence, timely recognition is essential.<sup>5,8</sup> In the pre-hospital setting, pelvic assessment primarily relies on clinical examination, trauma dynamics, and the presence of pain or evident anatomical alterations. According to the study by Coulombe *et al.*,<sup>9</sup> the "open book" type fracture benefits from the application of a Pelvic Circumferential Compression Device (PCCD). Indeed, in cases of significant pelvic ring injury, the PCCD can be used as a temporary measure to contain pelvic volume and thus reduce the anatomical space available for blood extravasation.

According to the recommendations of the Istituto Superiore di Sanità (ISS) for the management of major trauma, PCCD placement is indicated in two modalities: the compressive mode in patients who are unstable or showing signs of hypoperfusion, associated with anatomical and/or dynamic signs of pelvic injury, and the containment mode in the absence of hemodynamic instability but with the presence of anatomical/dynamic criteria of pelvic trauma.<sup>10</sup> The primary use of the PCCD is therefore in the temporary management of suspected pelvic fractures and should be considered a targeted provisional therapeutic measure rather than a routine immobilization device.<sup>11</sup>

### ***EFAST-PS***

The Focused Assessment Sonography for Trauma (FAST) and its subsequent extended version (EFAST) have been integral to clinical practice in emergency medicine for many years. The acronym FAST was first introduced in the literature in 1996 to identify intra-abdominal hemorrhage in unstable abdominal trauma. In 2003, the American College of Emergency Physicians published "The EFAST Exam," and approximately ten years after its inception, in 2006, the American College of Surgeons Committee on Trauma included it in the ATLS guidelines for managing thoraco-abdominal trauma.<sup>12,13</sup> The term EFAST (Extended-FAST) appeared in 2004 following a proposal to extend the standard examination to include thoracic scans aimed at detecting pneumothorax.

Today, EFAST is used in the "C" phase of the ABCDE assessment to identify causes of hemorrhagic shock, allowing for immediate resuscitative interventions. The exam should be completed in 2-3 minutes and addresses specific questions: detecting intra-abdominal fluid, pericardial tamponade, and pneumothorax.<sup>14</sup> EFAST can reduce the time required for surgical treatment, improve understanding of trauma severity, and optimize patient management at the scene and during transport to the receiving hospital.<sup>15,16</sup>

The proposal for further expansion of EFAST by adding ultrasound evaluation of the pubic symphysis emerged in 2009 with Bauman *et al.*, who first suggested the technique to early identify patients needing Pelvic Circumferential Compression Devices (PCCD).<sup>2</sup> Subsequently, scans of the pubic symphysis are noted in the FAST-PLUS (FAST-PL pleural -US ultrasound of symphysis) protocol proposed by Ianniello *et al.* in 2020<sup>17</sup> and in the cohort study proposed by Planquart *et al.* in 2022.<sup>4</sup> From the aforementioned studies, it is evident that implementing the EFAST protocol with pubic symphysis scans (EFAST-PS) can significantly improve the prognosis of trauma patients by reducing therapeutic times and optimizing their care pathway.

## Conclusions

As highlighted by the literature, current information on the EFAST-PS examination is scant and limited to three main studies. Therefore, despite recognizing the potential utility of applying this extended protocol in real-life scenarios, further studies are needed to validate its applicability and usefulness in the context of pre-hospital management of major trauma. It is also important to emphasize that emergency ultrasound assessment should always be integrated into the patient's clinical context. Only when properly integrated into a comprehensive evaluation that includes history, objective data, and dynamic assessments, can EFAST-PS provide valuable information to guide decision-making in polytrauma patients.

## References

1. Chaijareenont C, Krutsri C, Sumpritpradit P, et al. FAST accuracy in major pelvic fractures for decision-making of abdominal exploration: Systematic review and meta-analysis. *Ann Med Surg (Lond)* 2020;60:175-81.
2. Bauman M, Marinaro J, Tawil I, et al. Ultrasonographic determination of pubic symphyseal widening in trauma: the FAST-PS study. *J Emerg Med* 2011;40:528-33.
3. Ianniello S, Conte P, Di Serafino M, et al. Diagnostic accuracy of pubic symphysis ultrasound in the detection of unstable pelvis in polytrauma patients during e-FAST: the value of FAST-PLUS protocol. A preliminary experience. *J Ultrasound* 2021;24:423-8.

4. Planquart F, Marcaggi E, Blondonnet R, et al. Appropriateness of initial course of action in the management of blunt trauma based on a diagnostic workup including an extended ultrasonography scan. *JAMA Netw Open* 2022;5:e2245432.
5. Perumal R, S DCR, P SS, Jayaramaraju D, et al. Management of pelvic injuries in hemodynamically unstable polytrauma patients – Challenges and current updates. *J Clin Orthop Trauma* 2021;12:101-12. Erratum in: *J Clin Orthop Trauma* 2021;21:101558.
6. Mercer CB, Ball M, Cash RE, et al. Ultrasound use in the prehospital setting for trauma: a systematic review. *Prehosp Emerg Care* 2021;25:566-82.
7. Grotz MR, Allami MK, Harwood P, et al. Open pelvic fractures: epidemiology, current concepts of management and outcome. *Injury* 2005;36:1-13.
8. Melvin JS, Karunakar MA, Chapman JR. Pelvic fractures: epidemiology, injury patterns, and associated injuries. *Orthop Clin North Am* 2007;38:193-203.
9. Coulombe P, Malo C, Robitaille-Fortin M, et al. Identification and Management of Pelvic Fractures in Prehospital and Emergency Department Settings. *J Surg Res* 2024; doi:10.1016/j.jss.2024.05.006
10. Sistema Nazionale linee guida, ISS. Gestione integrata del Trauma Maggiore dalla scena dell'evento alla cura definitiva - ISS. Updated on 19/06/2024. Accessed July 2024. Available from: <https://www.iss.it/-/gestione-integrata-trauma-maggiore>
11. Cano JR, Bogallo JM, Ramirez A, Guerado E. Immediate management of a stable patient with unstable pelvis. *EFORT Open Rev* 2024;9:434-447.
12. American College of Surgeons. Committee on Trauma. ATLS, advanced trauma life support. Chicago, IL: American College of Surgeons; 1994.
13. Blackbourne LH, Soffer D, McKenney M, et al. Secondary ultrasound examination increases the sensitivity of the FAST exam in blunt trauma. *J Trauma* 2004;57:934-8.
14. Ketelaars R, Reijnders G, van Geffen GJ, et al. ABCDE of prehospital ultrasonography: a narrative review. *Crit Ultrasound J* 2018;10:17.
15. Magyar CTJ, Maeder F, Diepers M, et al. Detailed information gain and therapeutic impact of whole body computed tomography supplementary to conventional radiological diagnostics in blunt trauma emergency treatment: a consecutive trauma centre evaluation. *Eur J Trauma Emerg Surg* 2022;48:921-31.
16. Demetriades D, Karaiskakis M, Toutouzas K, et al. Pelvic fractures: epidemiology and predictors of associated abdominal injuries and outcomes. *J Am Coll Surg* 2002;195:1-10.



17. Ianniello S, Conte P, Di Serafino M, et al. Diagnostic accuracy of pubic symphysis ultrasound in the detection of unstable pelvis in polytrauma patients during e-FAST: the value of FAST-PLUS protocol. A preliminary experience. *J Ultrasound* 2021;24:423-8.

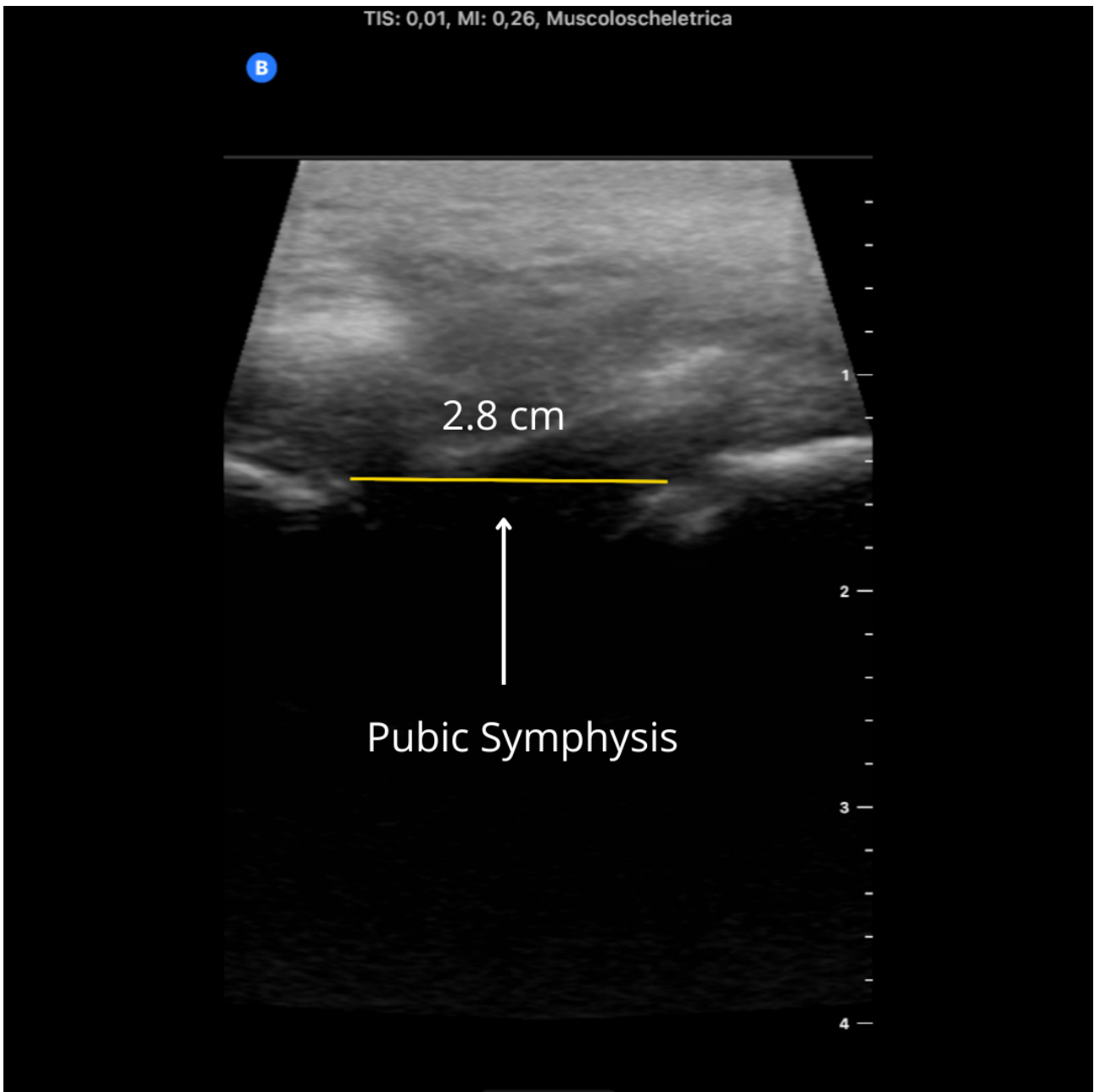


Figure 1. Pubic symphysis diastasis due to an open-book fracture.

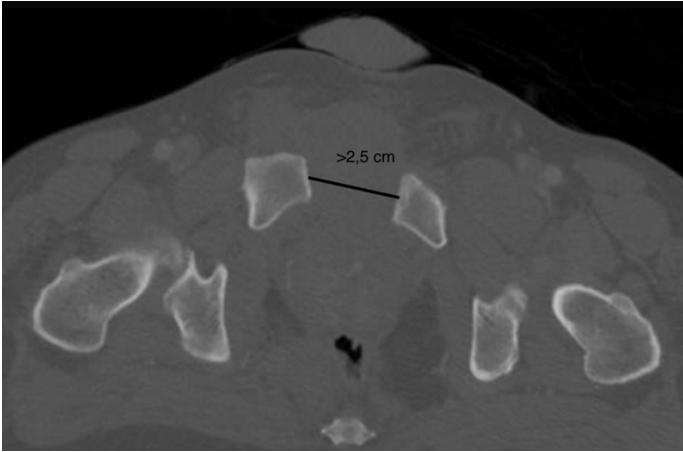


Figure 2. Axial CT images show a pubic diastasis  $>2.5$  cm.