

When infection strikes the heart: identifying and treating non-rheumatic streptococcal myocarditis in a young man with chest pain and concurrent streptococcal pharyngitis

Matic Mihevc

Emergency Department, Primary Healthcare Centre Trebnje, Trebnje; Primary Healthcare Research and Development Institute, Community Health Centre Ljubljana; Department of Family Medicine, Faculty of Medicine, University of Ljubljana, Slovenia

Abstract

Pharyngitis and tonsillitis are common reasons for seeking medical care. While mostly viral, *Streptococcus pyogenes* causes 5-20% of adult cases. Non-rheumatic streptococcal myocarditis is a distinct form of myocarditis associated with streptococcal infection and has clinical features resembling acute coronary syndrome.

Correspondence: Matic Mihevc, Department of Family Medicine, Faculty of Medicine, University of Ljubljana, Slovenia
E-mail: mihevc.matic@zd-tr.si

Key words: myocarditis; streptococcus; pharyngitis; treatment; acute coronary syndrome.

Conflict of interest: the authors declare no potential conflict of interest, and all authors confirm accuracy.

Availability of data and material: all data supporting the findings of this study are available upon request from the corresponding author.

Ethics approval and consent to participate: ethical approval was not required for this article as it does not involve any studies with human participants or animals. Informed consent was obtained from the patient involved in the case report.

Consent for publication: written consent was obtained from the patient, granting permission to use their personal data, including any accompanying images.

Acknowledgments: the author would like to acknowledge the valuable assistance provided by Marko Medved, MD, and the Cardiology Department of General Hospital Novo Mesto in the preparation of this case report.

Received: 23 July 2023.

Accepted: 1 September 2023.

Early view: 8 September 2023.

This work is licensed under a Creative Commons Attribution 4.0 License (by-nc 4.0).

© Copyright: the Author(s), 2023

Licensee PAGEPress, Italy

Emergency Care Journal 2023; 19:11606

doi:10.4081/ecj.2023.11606

Publisher's note: all claims expressed in this article are solely those of the authors and do not necessarily represent those of their affiliated organizations, or those of the publisher, the editors and the reviewers. Any product that may be evaluated in this article or claim that may be made by its manufacturer is not guaranteed or endorsed by the publisher.

It mainly affects young men and can lead to significant complications, including sudden cardiac death. We present a case of a young man with non-rheumatic streptococcal myocarditis that developed three days after streptococcal pharyngitis. This is the first documented case in which a treatment approach using a combination of benzathine phenoxymethylpenicillin, perindopril, and bisoprolol, followed by extended therapy with extencillin, resulted in a rapid improvement in the patient's cardiac function and general health. The insights gained from this case offer valuable guidance for managing similar conditions in the future.

Introduction

Pharyngitis and tonsillitis are common reasons for seeking care from a general practitioner or at an emergency department. While mostly viral, *Streptococcus pyogenes* causes 5-20% of adult cases.¹

Myocarditis is characterized by inflammation of the heart muscle and primarily occurs due to microbial-mediated or autoimmune damage to the heart. It predominantly affects young men and can lead to significant short-term and long-term complications, including sudden cardiac death or dilated cardiomyopathy.^{2,3} Other potential causes of this condition include bacteria, parasites, certain medications, systemic diseases, and other factors.¹⁻³

Non-rheumatic streptococcal myocarditis is a unique type of myocarditis associated with streptococcal tonsillitis/pharyngitis or joint abscess/arthritis. It follows a more rapid course and does not occur 2-4 weeks after a streptococcal infection, as seen in acute rheumatic fever.^{1,4-16} The exact underlying process by which non-rheumatic myocarditis develops after infection with *Streptococcus pyogenes* is still unclear. Potential factors contributing to its development include streptococcal toxins and cross-reactivity.^{1,7}

In July 2023, a thorough search of the PubMed/MEDLINE and EMBASE databases using specific search terms (*Streptococcus pyogenes*, infection, myocarditis, clinical case) found 10 relevant clinical cases from the last five years.^{7,15} Table 1 gives an overview of these recent cases, all involving young males. Eight cases were linked to tonsillitis/pharyngitis,^{7-9,12-15} and two with joint abscess/arthritis.^{10,11} Three of them had severe fulminant myocarditis,^{7,10,11} while the remaining had milder severity. Two cases experienced recurrent episodes.^{7,8} Most patients showed a favorable clinical response to treatment with antibiotics from the group of penicillin or third-generation cephalosporins, although combinations with clindamycin,¹⁰ azithromycin,¹⁵ and amoxicillin with clavulanic acid⁹ were also used. One patient with fulminant myocarditis succumbed to the disease,⁷ while the others had a favorable long-term outcome (Table 1).

In this context, we present a case of non-rheumatic streptococcal myocarditis in a young man, which emerged three days after the onset of streptococcal pharyngitis. This is the first documented

case in which a treatment approach with a combination of benzathine phenoxymethylpenicillin, perindopril, and bisoprolol, followed by one year of therapy with extencillin, resulted in a rapid improvement in the patient's cardiac function and general health.

Case Report

A 33-year-old man sought medical attention at the primary health care center due to a two-day history of a sore throat and fever. He had a history of spondylarthritis but was not under current treatment. The *Streptococcus pyogenes* infection was confirmed with the ALLTEST Strep-A rapid test. The patient was prescribed peroral benzathine phenoxymethylpenicillin at a dose of 1,500,000 I.U. every 8 hours for 10 days.

During the night, the patient experienced chest tightness, which worsened with deep breaths or lying on the stomach. Fearing a possible penicillin allergy, he returned to the primary health care center. Clinical examination revealed signs of pharyngitis with no other clinical abnormalities. An electrocardiogram (ECG) showed a sinus rhythm along with non-specific ECG changes, namely elevated ST-segment in lead aVL, T-wave inversion in leads III and V1, and a flattened T-wave in lead aVF (Figure 1A). A point-of-care Troponin I test (Stratus® CS Acute Care™ cardiac Tnl) showed an elevated value of 12.05 ng/mL (reference value <0.06 ng/mL). Based on these findings, the patient was referred to a regional hospital for suspected myocarditis (Figure 1).

After his referral to the regional hospital, comprehensive assessments were conducted. These revealed an elevated white blood cell count ($14.2 \times 10^9/L$) and increased C-reactive protein lev-

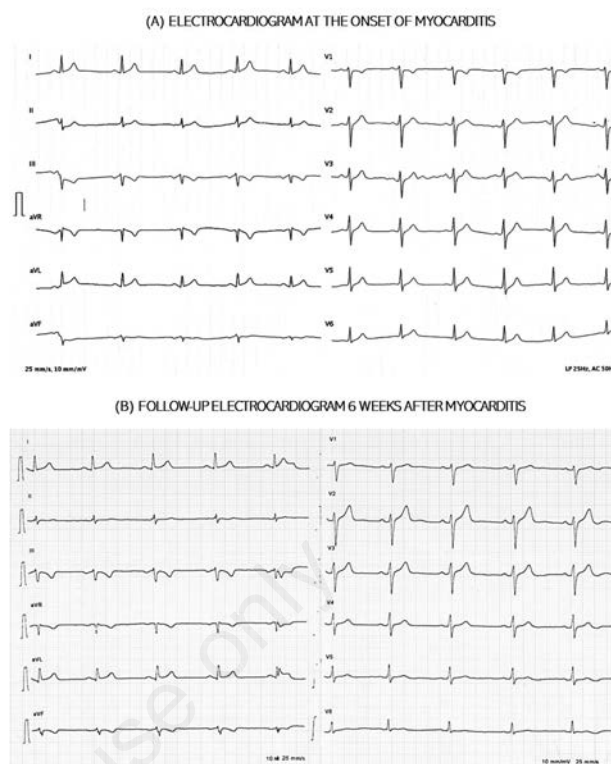


Figure 1. Electrocardiogram at the onset of myocarditis (A) and after 6 weeks (B).

Table 1. Overview of the most recent non-rheumatic streptococcal myocarditis case reports in adults.

Author, year (reference)	Gender, age	Tonsillitis/pharyngitis	Clinical presentation	ECG signs	Heart impairment	Treatment
Hiraiwa <i>et al.</i> , 2022 ⁷	Male, 42	Yes	Sore throat, cardiogenic shock	Precordial STE	Fulminant myocarditis (LVEF <10%)	ECMO
Allen <i>et al.</i> , 2022 ⁸	Male, 23	Yes	Fever, sore throat, chest pain	First ECG normal, subsequent diffuse STE	Myocarditis (LVEF 45%)	ASA, ceftriaxone, vancomycin, benzathine penicillin, prednisone
Kalpakos <i>et al.</i> , 2021 ⁹	Male, 27	Yes	Sore throat, fever, hypotension, tachypnoea	Inferior, posterior, and lateral STE	Inferior-lateral myocarditis (LVEF 30%)	Amoxicillin/ clavulanic acid, ACEi, NSAID
Kalpakos <i>et al.</i> , 2021 ⁹	Male, 33	Yes	Chest pain, nausea, epigastric pain	Inferior and posterior STE	Inferior-lateral myocarditis	Amoxicillin
Fox-Levis <i>et al.</i> , 2020 ¹⁰	Male, 21	No	Fever, knee abscess, chest pain	Inferior STE	Fulminant myocarditis (LVEF 10-15%)	Benzylpenicillin, clindamycin, ECMO
Ferrero <i>et al.</i> , 2020 ¹¹	Male, 35	No	Fever, knee swelling, chest pain	Inferior and lateral STE	Fulminant myocarditis (LVEF 10-15%)	Ampicillin/ sulbactam, adrenaline, ACEi
Derbas <i>et al.</i> , 2019 ¹²	Male, 25	Yes	Chest pain, dyspnoea, sore throat, fever	Anterior STE	Anterior myocarditis (LVEF 53%)	NR
Müller, 2019 ¹³	Male, 31	Yes	Fever, chest pain, sore throat	NR	Inferior-posterior myocarditis (LVEF 50%), mitral regurgitation	NR
O'Brien <i>et al.</i> , 2018 ¹⁴	Male, 17	Yes	Chest pain, sore throat, fever, dyspnoea	Inferior and lateral STE	Septal and apical myocarditis (LVEF 49%)	Amoxicillin, NSAID, lisinopril
Silva <i>et al.</i> , 2018 ¹⁵	Male, 18	Yes	Chest pain, relapse in 2 weeks	Lateral STE	Inferolateral myopericarditis	ASA, colchicine, azithromycin, amoxicillin.

STE, ST-segment elevation; ECMO, extracorporeal membrane oxygenation; ECG, electrocardiogram; NR, not reported; LVEF, left ventricular ejection fraction; NSAID, non-steroidal anti-inflammatory drugs; ASA, acetylsalicylic acid; ACEi, angiotensin converting enzyme inhibitor.

els of 145.1 mg/L (reference value <5 mg/L). Notably, initial measurements of high-sensitive cardiac Troponin T (hs-cTnT) showed a remarkable increase of 982 ng/L (reference value <14 ng/L), while baseline measurement of N-terminal pro-brain natriuretic peptide (NT-proBNP) showed a slight increase of 495.1 ng/L (reference value <450 ng/L). A point-of-care ultrasound examination revealed a normal-sized left ventricle with normal systolic and diastolic function. There was a 0.6 cm right pericardial gap and local pericardial effusion.

The next day, ECG changes were recorded. There were ST-segment elevation in lateral ventricular leads and ST-segment depression in leads III and aVF. Coronary angiography was performed and showed normal coronary arteries. The patient was treated with bisoprolol 1.25 mg/12h and perindopril 2 mg per day and therapy with benzathine phenoxymethylpenicillin was continued. The markers hs-cTnT and NT-proBNP continued to rise to 1988 ng/L (reference value <14 ng/L) and 711.1 ng/L (reference value <450 ng/L), respectively.

On the third day, the patient underwent cardiac magnetic resonance imaging (MRI), which showed extensive myocarditis affecting the lateral and inferior walls, with preserved left ventricular ejection fraction (LVEF) of 57% and right ventricular ejection fraction (RVEF) of 51% (Figure 2).

On day five, both haemocultures and serological tests were negative for cardiotropic viruses, while the patient tested positive for anti-DNAase B antibodies. Remarkably, the patient was no longer experiencing chest pain and had resolved respiratory issues. The levels of hs-cTnT and NT-proBNP decreased to 193 ng/L (reference value <14 ng/L) and 192.1 ng/L (reference value <450 ng/L), respectively. As a result, the patient was discharged home.

During the first month of recovery at home, episodes of sinus tachycardia occurred occasionally and eventually subsided. To prevent a recurrence, the patient received monthly injections of extencilin at a dosage of 2,400,00 I.U. for one year. In addition, the patient continued oral therapy to prevent cardiac remodeling, taking bisoprolol 1.25 mg in the morning and perindopril 2 mg in the evening. Given the severity of the myocarditis, the patient was advised to rest and avoid significant stress for the next six months.

Six weeks after myocarditis onset, a follow-up ECG revealed persistent ECG changes. There was ST-segment elevation in lead aVL and ST-segment depression along with biphasic T-waves in leads III and aVF (Figure 1B). After five months, a follow-up cardiac MRI was performed, revealing normalization of cardiac function (RVEF 54%, LVEF 60%) and moderate postmyocardial changes in the lateral wall. After six months, the patient was able to resume work, indicating a successful recovery.

Discussion

This case report outlines the successful management of a young man with non-rheumatic streptococcal myocarditis and concurrent streptococcal pharyngitis, which improved rapidly following a therapeutic regimen involving benzathine phenoxymethylpenicillin, bisoprolol, and perindopril.

Prior case reports have underscored the heterogeneous clinical presentations of non-rheumatic streptococcal myocarditis, encompassing symptoms such as chest pain, fever, dyspnoea, dizziness, syncope, nausea, and even signs indicative of cardiac shock. Additionally, signs of the primary infection source, such as sore throat or joint pain, may also be present.⁷⁻¹⁵ In this context, the patient had the classic triad of symptoms, including fever, sore

throat, and chest pain, which is consistent with recent case reports in which the primary source of infection was tonsillitis or pharyngitis.^{7-9,12-15} While male gender, family history of heart disease, and preceding episodes of non-rheumatic streptococcal myocarditis have emerged as risk factors,⁷⁻¹⁵ it is noteworthy that instances involving female patients have also been documented.¹⁷ In the present case, the patient had underlying spondylarthritis, which is known to increase the risk of cardiovascular comorbidity (18). This suggests that chronic autoimmune diseases may serve as additional risk factors due to their involvement in the immune response and tissue cross-reactivity.^{7,18}

In terms of clinical and diagnostic findings, most patients exhibited ECG changes such as ST-segment elevations, T-wave inversions, and biphasic T-waves along with elevated cardiac markers, especially Troponin I and Creatine Kinase-MB, whereas no hs-cTnT has been reported so far.⁷⁻¹⁵ However, there were also cases where the initial ECG appeared non-specific, but subsequent ECGs showed changes.⁸ This pattern was also observed in our patient, underscoring the risk that the disease may be missed if only the initial ECG is considered. Furthermore, we identified persistent ECG changes even in the post-myocarditis phase, thus emphasizing the enduring impact of myocarditis on cardiac electrical activity, possibly attributable to structural changes or irregularities in cardiac motion.^{2,3}

Transthoracic echocardiography showed regional wall motion abnormalities in about 25% of patients, pericardial effusion in <10%, and mitral regurgitation with an accessory mass in one case.^{1,7-15} The LVEF varied, with some patients having preserved LVEF,^{12,13} mildly reduced LVEF,^{8,14} or reduced LVEF.^{7,9-11} In our case, we found minor pericardial effusion with preserved LVEF.

The therapeutic approach to myocarditis hinges upon several factors, encompassing the acuteness, severity, clinical manifestation, and underlying causative factors.^{2,3} Supportive care remains a cornerstone, while guidelines for heart failure management are applicable when dealing with cases featuring reduced LVEF.² The utilization of β -blockers or angiotensin-converting enzyme inhibitors to mitigate inflammation, counteract adverse remodel-

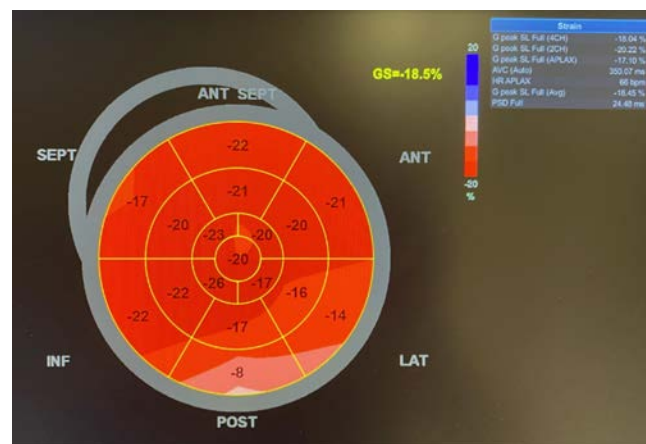

Figure 2. Cardiac magnetic resonance imaging on the third day showing extensive myocarditis involving the lateral and inferior walls.

ing, and potentially limit scar formation remains an area of ongoing debate, particularly in scenarios where LVEF is preserved.² Notably, both these classes of drugs have demonstrated efficacy in animal models of myocarditis, addressing both necrotic and fibrotic aspects.¹⁹ While some authors have reported the utilization of non-steroidal anti-inflammatory drugs,^{8,9,14,15} their application in myocarditis is discouraged due to their potential interference with the production of anti-inflammatory prostaglandins, which could hinder the cardiac healing process. In instances of severe myocarditis, interventions such as inotropic support, mechanical circulatory support, or cardiac transplantation might be needed.^{2,3}

The specific therapeutic strategies for myocarditis are tailored to the underlying etiology. For non-rheumatic streptococcal myocarditis, antibiotics from the penicillin group, such as benzathine penicillin,⁸ benzylpenicillin,¹⁰ ampicillin,¹¹ and amoxicillin,^{9,14,15} have exhibited favorable outcomes in various clinical cases. These treatment approaches align with the guidelines set for managing streptococcal pharyngitis established by CDC/AAFP/ACP-ASIM.²⁰ However, the optimal duration of antibiotic therapy remains a subject of discourse, driven by the potential risk of myocarditis recurrence, necessitating further comprehensive investigation. In contrast, current guidelines for patients with rheumatic fever with carditis but no residual heart disease recommend 10-year prophylaxis with benzylpenicillin after the last attack.¹⁶ In the present case, a prolonged one-year course with extencillin was selected, and no recurrence transpired within the one-year follow-up period.

Conclusions

Non-rheumatic streptococcal myocarditis is a serious complication arising from streptococcal infection, displaying clinical and diagnostic features like acute coronary syndrome. The condition manifests with various symptoms, including instances of sudden and severe heart failure. The long-term forecast is favorable, with complete restoration of heart function and overall well-being. To avoid cardiac remodeling, it is advised that individuals refrain from participating in competitive sports or engaging in strenuous exercise for a period of 3-6 months following diagnosis. Additionally, a minimum of 12-month regimen with extencillin may be considered to prevent the recurrence of the disease.

References

- Schmutzler L, Mirna M, Hoppe UC, Lichtenauer M. From streptococcal pharyngitis/tonsillitis to myocarditis: a systematic review. *J Cardiovasc Dev Dis* 2022;9:170.
- Tschöpe C, Ammirati E, Bozkurt B, et al. Myocarditis and inflammatory cardiomyopathy: current evidence and future directions. *Nat Rev Cardiol* 2021;18:169-93.
- Lampejo T, Durkin SM, Bhatt N, Guttmann O. Acute myocarditis: aetiology, diagnosis and management. *Clin Med (Lond)* 2021;21:505-10.
- Zühlke LJ, Beaton A, Engel ME, et al. Group A streptococcus, acute rheumatic fever and rheumatic heart disease: epidemiology and clinical considerations. *Curr Treat Options Cardiovasc Med* 2017;19:15.
- Talmon Y, Gilbey P, Fridman N, et al. Acute myopericarditis complicating acute tonsillitis: beware the young male patient with tonsillitis complaining of chest pain. *Ann Otol Rhinol Laryngol* 2008;117:295-7.
- Aguirre JL, Jurado M, Porres-Aguilar M, et al. Acute non-rheumatic streptococcal myocarditis resembling ST-elevation acute myocardial infarction in a young patient. *Proc (Bayl Univ Med Cent)* 2015;28:188-90.
- Hiraiwa H, Morimoto R, Ando R, et al. Recurrent fulminant non-rheumatic streptococcal myocarditis proven by endomyocardial biopsy and autopsy. *J Cardiol Cases* 2022;26:62-5.
- Allen J, Munoz C, Byakova A, Pachulski R. Acute fulminant group A beta-hemolytic streptococcus-associated carditis: a case report and literature review. *Cureus* 2022;14:e27282.
- Kalpakos T, Wilgenhof A, Michiels V, et al. Streptococcal pharyngitis associated myocarditis (SPAM): the perfect ST-segment elevation myocardial infarction (STEMI) mimic in young individuals. A case series. *Acta Cardiol* 2021;76:449-54.
- Fox-Lewis A, Merz TM, Hennessy I. Severe non-rheumatic streptococcal myocarditis requiring extracorporeal membrane oxygenation support. *Lancet Infect Dis* 2020;20:1481.
- Ferrero P, Piazza I, Lorini LF, Senni M. Epidemiologic and clinical profiles of bacterial myocarditis. Report of two cases and data from a pooled analysis. *Indian Heart J* 2020;72:82-92.
- Derbas LA, Samanta A, Potla S, et al. Separating acute rheumatic fever from nonrheumatic streptococcal myocarditis. *Case Rep Med* 2019;4674875.
- Müller C. 31-year old male with fever, chest pain and tonsillitis. *Dtsch Med Wochenschr* 2019;144:201-2.
- O'Brien CE, Coulson JD, Sekar P, et al. Non-rheumatic streptococcal myocarditis mimicking acute myocardial infarction in an adolescent male. *Cardiol Young* 2018;28:454-7.
- Silva R, Puga L, Teixeira R, et al. Acute non-rheumatic myopericarditis: a rare complication of pharyngitis. *Eur J Case Rep Intern Med* 2018;5:000987.
- Al-Jazairi A, Al-Jaser R, Al-Halees Z, et al. Guidelines for the secondary prevention of rheumatic heart disease: endorsed by Saudi Pediatric Infectious Diseases Society (SPIDS). *Int J Pediatr Adolesc Med* 2017;4:47-50.
- Talmon Y, Ishai R, Samet A, et al. Acute myopericarditis complicating acute tonsillitis: a prospective study. *Ann Otol Rhinol Laryngol* 2009;118:556-8.
- Liew JW, Ramiro S, Gensler LS. Cardiovascular morbidity and mortality in ankylosing spondylitis and psoriatic arthritis. *Best Pract Res Clin Rheumatol* 2018;32:369-89.
- Silverblatt JA, Ziff OJ, Dancy L, et al. Therapies to limit myocardial injury in animal models of myocarditis: a systematic review and meta-analysis. *Basic Res Cardiol* 2019;114:48.
- Mustafa Z, Ghaffari M. Diagnostic methods, clinical guidelines, and antibiotic treatment for group A streptococcal pharyngitis: a narrative review. *Front Cell Infect Microbiol* 2020;10:563627.