

A case of retinal detachment resulting from air bag deployment

Fevzi Yılmaz, Bora Baltacıoğlu, Erdi Akça, Yavuz Fatih Yavuz

Department of Emergency Medicine, Health Sciences University, Antalya Training and Research Hospital, Antalya, Turkey

Abstract

A Motor Vehicle Accident (MVA) can result in death or serious injury to the driver and passengers in case the airbags are not deployed. However, airbags can themselves cause ocular injuries of a varying degree of severity. We report the case of a 41-year-old female patient who reported facial bone fractures and a retinal detachment after her air bag deflated during a car accident. On

admission to the Emergency Department (ED) the patient complained of facial pain, swelling and redness in the eye. Orbital CT imaging documented a fragmented fracture line displaced into the maxillary sinus at the floor of right orbit, post-traumatic changes in preorbital skin and in the right globe vitreous, an appearance thought to belong to hyperdense hemorrhage. The patient was taken to emergency operation due to retinal detachment in her right eye.

Case Report

Due to an eye injury brought on by the airbag's deployment during a MVA, a 41-year-old female patient was transported by ambulance to the Antalya Training and Research Hospital Emergency Department (ED). The hospital has a 3rd level Trauma Center, where trauma physicians from all branches are present and injured patients are evaluated quickly, resuscitation, surgery, intensive care and emergency operations are performed. According to the story she was driving and wearing a seatbelt, and the car was traveling 55 km/h at the time of the accident. The patient did not wear glasses at the time of the accident. On admission she complained of facial pain, swelling, redness and blurred vision in the right eye. On physical examination, the patient was in good general condition, conscious, cooperative, and oriented, with a Glasgow Coma Score (GCS) of 15. Vital signs showed a body temperature of 36.7 °C, a respiratory rate of 22/min, a heart rate of 92/min, a blood pressure of 112/76 mmHg, and an SPO₂ of 98%. On examination of the head and neck, the patient had a 1 cm laceration of the right upper eyelid, the conjunctiva was edematous and hemorrhagic (Figure 1), and she also had decreased vision in her right eye.

Orbital CT images was immediately performed showing a fragmented fracture displaced into the maxillary sinus at the right orbital floor (Figure 2). In the right frontal bone, a non-displaced fracture line is observed in the outer tabula anterior to the right frontal sinus. In the right globe vitreous, an appearance thought to belong to hyperdense hemorrhage is observed (Figure 3).

The patient was examined by an ophthalmologist, documenting a full-thickness incision approximately 7–8 mm long from the middle cornea to the upper part including the limbus, with a lamellar incision 1 mm lateral to this incision. The iris tissue protruded from the incision site, and the lens could not be selected. The patient was taken to emergency operation due to retinal detachment in the right eye. In the follow-up, the patient was re-operated one month later due to traumatic cataract, retinal detachment and intravitreal hemorrhage, and the treatment is still ongoing.

Discussion

In many countries, MVA are one of the leading causes of human injuries and deaths.¹ Car accident-related mortality and morbidity are significantly diminished by seat belts and airbags

Correspondence: Fevzi Yılmaz, University of Health Sciences, Antalya Training and Research Hospital, Emergency Department, Varlık Mh. Kazım Karabekir Cd. 07100 Antalya, Turkey.
Tel.: +905055907307; Fax: +902422494400
E-mail: fevzi_yilmaz2002@yahoo.com

Key words: motor vehicle accident; airbag-mediated injury; eye injury; head injury; retinal detachment.

Conflict of interest: the authors declare no conflict of interest.

Availability of data and materials: all data underlying the findings are fully available.

Ethics approval and consent to participate: no ethical committee approval was required for this case report by the Department, because this article does not contain any studies with human participants or animals. Informed consent was obtained from the patient included in this study.

Consent for publication: the patient gave her written consent to use her personal data for the publication of this case report and any accompanying images.

Contribution: all authors participated in the conception and design of the work, drafted the work, or critically reviewed it. All authors approved the final version for publication.

Received for publication: 28 November 2022.

Revision received: 16 February 2023.

Accepted for publication: 20 February 2023.

This work is licensed under a Creative Commons Attribution 4.0 License (by-nc 4.0).

©Copyright: the Author(s), 2023

Licensee PAGEPress, Italy

Emergency Care Journal 2023; 19: 11039

doi:10.4081/ecj.2023.11039

Publisher's note: all claims expressed in this article are solely those of the authors and do not necessarily represent those of their affiliated organizations, or those of the publisher, the editors and the reviewers. Any product that may be evaluated in this article or claim that may be made by its manufacturer is not guaranteed or endorsed by the publisher.

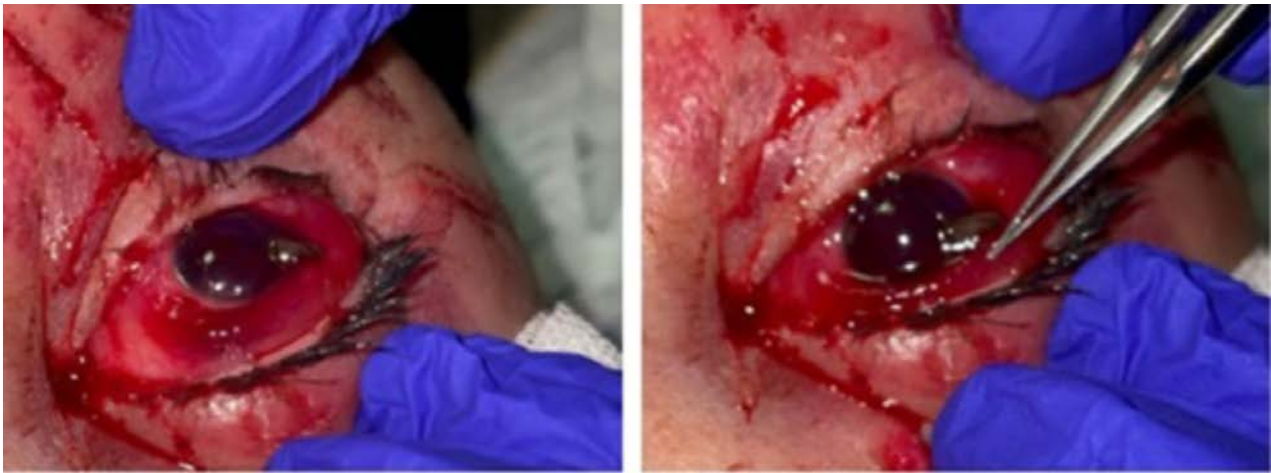

Figure 1. 1 cm long tear on the right upper eyelid, and the conjunctiva was edematous and hemorrhagic.

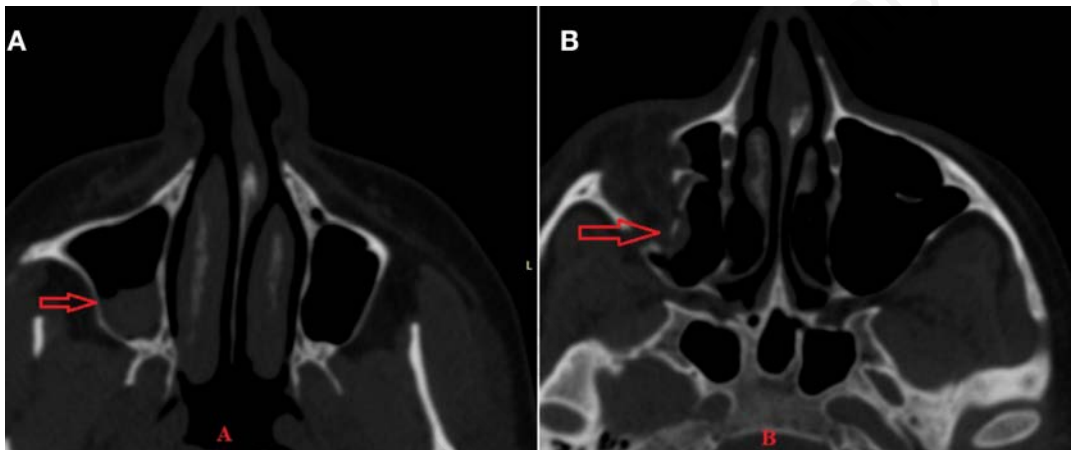


Figure 2. A) Orbital CT images showed hyperdense bleeding in the maxillary sinus; B) Orbital CT images showed a fragmented fracture displaced into the maxillary sinus

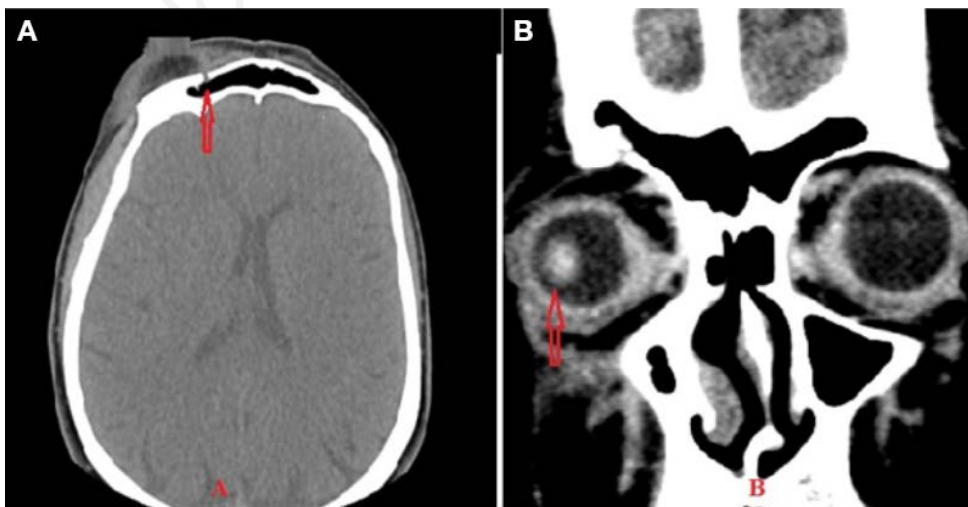


Figure 3. A) Non-displaced fracture line is observed in the outer table anterior to the right frontal sinus; B) In the right globe vitreous, hyperdense hemorrhage is observed.

used to protect both passengers and drivers.² In the 1960s, airbags were introduced as safety systems that significantly reduced traffic accident fatalities.³ Airbags are inflatable devices designed to act as a cushion between vehicle occupants and the steering wheel and car dashboard.⁴ The widespread use of airbags has significantly reduced the incidence of serious morbidity from MVA by up to 45% and has also reduced the number of serious ocular injuries.⁵

Although airbags have been shown to reduce the incidence of serious injury and death from motor vehicle accidents, current literature indicates that airbags can cause serious eye injuries, chemical skin burns, bone fractures and visceral injuries.^{3,6,7} Reported ocular injuries include eyelid lacerations, periorbital fractures, corneal abrasions, hyphemas, lens dislocations, angle recessions, corneoscleral lacerations, alkaline corneal burns, cyclodialysis, retinal and vitreous hemorrhages, and traumatic macular holes.^{2,7-9} Chemical injuries to the eye can cause severe and irreversible eye damage as well as skin burns.^{2,9} Alkaline burns in the eye caused by the influence of hazardous gases such as carbon monoxide, nitric oxide, ammonia, benzene, toluene, ethylbenzene, xylene, etc. present in the airbag can cause serious injuries, including life-long blindness.² However, there have been few research on retinal detachment caused by deployed airbags.^{5,10-16} To the best of our knowledge, this is the first case of retinal detachment after a MVA reported in Turkey.

Retinal detachment is an emergency where the retina is detached from its normal position.¹⁷ Symptoms of retinal detachment include flashes of light in the eyes, blurred vision, the appearance of floaters, small spots that seem to pass through the field of view, gradual decrease in peripheral vision, and a curtain-like shadow in the field of view. Patients with suspected retinal detachment immediately should be consulted to the ophthalmologist. Retinal detachment should be diagnosed with an enlarged eye examination to determine whether the detachment includes the central retina (macula) and in absence of involvement, the patient should undergo emergency surgery to prevent further progression that could affect central vision.¹⁸ Our patient also had redness of the eye and blurred vision in the right eye upon admission to the ED and we decided to refer immediately the patient to the ophthalmologist.

A review of the literature finds many studies investigating the risk vs benefit of air bag impact on ocular structures.⁴ Duma *et al.*¹⁹ studied 11 million front-seat occupants from over 22,000 cases between the years 1993 and 1999. In the study, only 3% of all patients exposed to a deployed airbag suffered ocular injury. The authors concluded that, although vehicle occupants exposed to a deployed air bag had a higher risk of sustaining minor eye injuries, serious injuries such as retinal detachment, corneal laceration, and hyphema have been reported. Interestingly 29% of patients who sustained an air bag induced injury were wearing eyeglasses, but also 25% of those who did not sustain an ocular injury were also wearing glasses. In our case, the patient had redness of the eye and the conjunctiva was edematous and hemorrhagic. However, the patient was diagnosed with retinal detachment as a result of further examinations and tests. In our case, the patient did not wear glasses at the time of the accident.

In determining whether the injuries to the person are caused by the explosion of the airbag, an in-depth physical examination, a crime scene investigation, accident detection reports, and all statements should be assessed together.²⁰ A person in the vehicle in the accident had an injury that was easily fixed by medical intervention, the accident happened at a low speed, and when the patient examination findings are combined, it is clear that there wasn't a crucial traffic accident, and the injury caused facial bone fractures

and retinal detachment in the patient. The mechanical effect of the airbag was found to have caused this injury, and in general, the use of airbags in conjunction with seat belts is associated with a significant reduction in facial fractures and lacerations.²¹ Based on the findings of some authors, seat belts are the best way to reduce the risk of eye injuries associated with motor vehicle accidents.²² Numerous U.S. studies failed to differentiate the data regarding seat belt use. These studies showed a connection between eye trauma and airbag deployment, but did not account for seat belt use, suggesting a more pessimistic assessment of the airbag's ability to prevent such injuries.¹⁹⁻²² Ocular trauma as a consequence of air bag inflation can occur with high or low impact injuries.²³ In our case, the patient developed a retinal detachment despite wearing a seat belt and being hit by a car at low speed.

Conclusions

This case shows that airbag deployment may sometimes cause severe ocular injury with retinal detachment leading to severe visual impairment. Emergency physician, regardless of vehicle speed, should be aware that serious eye injuries, including retinal detachment, can occur to patients who report injury from airbag deployment.

References

1. Ashabyamin M, Hamdamjo F. Severe facial fractures due to airbag deployment without utilization of a seat belt: A case report. *Marmara Med J* 2021;34:79-81.
2. Koisaari T, Leivo T, Sahraravand A, et al. Airbag deployment-related eye injuries. *Traffic Inj Prev* 2017;18:493-9
3. Yaremchuk K, Dobie RA. Otologic injuries from airbag deployment. *Otolaryngol Head Neck Surg* 2001;125:130-4.
4. Kenney KS, Fanciullo LM. Automobile air bags: friend or foe? A case of air bag-associated ocular trauma and a related literature review. *Optometry* 2005;76:382-6.
5. Salam T, Stavrakas P, Wickham L, Bainbridge J. Airbag injury and bilateral globe rupture. *Am J Emerg Med* 2010;28:982.e5-6.
6. Lee WB, O'Halloran HS, Pearson PA, et al. Airbags and bilateral eye injury: five case reports and a review of the literature. *J Emerg Med* 2001;20:129-34.
7. Sato Y, Ohshima T, Kondo T. Air bag injuries-a literature review in consideration of demands in forensic autopsies. *Forensic Sci Int* 2002;128:162-7.
8. Büyük Y, Üzüñ I, Erkol Z, et al. Air bag-mediated fatal cranio-cervical trauma: a case report. *Ulusal Travma ve Acil Cerrahi Dergisi* 2010;16:379-81.
9. Skibba KEH, Cleveland CN, Bell DE. Airbag burns: an unfortunate consequence of motor vehicle safety. *J Burn Care Res* 2021;42:71-3.
10. Whitacre MM, Pilchard WA. Air bag injury producing retinal dialysis and detachment. *Arch Ophthalmol* 1993;111:1320.
11. Han DP. Retinal detachment caused by air bag injury. *Arch Ophthalmol* 1993;111:1317-8.
12. Savastano A, Donati MC, Rizzo S. Retinal Tear Related to Air Bag Deployment. *JAMA Ophthalmol* 2016;134:e155021.
13. Elliott D, Hauch A, Kim RW, Fawzi A. Retinal dialysis and detachment in a child after airbag deployment. *J AAPOS* 2011;15:203-4.

14. Dubinsky I, McGowan H. Case report: retinal tear as a consequence of air bag inflation. *Can Fam Physician* 1997;43:1576-7.
15. Ruiz-Moreno JM. Air bag-associated retinal tear. *Eur J Ophthalmol* 1998;8:52-3.
16. Stein JD, Jaeger EA, Jeffers JB. Air bags and ocular injuries. *Trans Am Ophthalmol Soc* 1999;97:59-82; discussion 82-6.
17. Samanta R, Jayaraj S, Sood G, Agrawal A. Post-traumatic posterior giant retinal tear and macular hole associated retinal detachment. *Indian J Ophthalmol* 2022;70:1869.
18. Gadde SGK, Snehith R, Jayadev C, et al. Macular tractional retinal detachment: A rare complication of blunt trauma. *Indian J Ophthalmol* 2020;68:2602-2604.
19. Duma SM, Jernigan MV, Stitzel JD, et al. The effect of frontal air bags on eye injury patterns in automobile crashes. *Arch Ophthalmol* 2002;120:1517-22.
20. Walsh A, Lewis K. EMS Management of Eye Injuries. 2022 Aug 5. In: StatPearls [Internet]. Treasure Island (FL): StatPearls Publishing; 2022 Jan.
21. Stacey DH, Doyle JF, Gutowski KA. Safety device use affects the incidence patterns of facial trauma in motor vehicle collisions: an analysis of the National Trauma Database from 2000 to 2004. *Plast Reconstr Surg* 2008;121:2057-64.
22. McGwin G, Owsley C. Risk factors for motor vehicle collision-related eye injuries. *Arch Ophthalmol* 2005;123:89-95.
23. Adams SL, Petri RW. Injury with spontaneous deployment of an automobile air bag. *Acad Emerg Med* 1996;3:179-80.

Non-commercial use only