

CT imaging in idiopathic out-of-hospital cardiac arrest: An assessment of current practice and diagnostic utility

Isla Harper,¹ Kate Easterford,² Matthew J Reed^{2,3}

¹Edinburgh Medical School, College of Medical and Veterinary Medicine, Edinburgh; ²Emergency Medicine Research Group Edinburgh (EMERGE), Department of Emergency Medicine, Royal Infirmary of Edinburgh, Edinburgh; ³Acute Care Group, Usher Institute of Population Health Sciences and Informatics, College of Medicine and Veterinary Medicine, University of Edinburgh, Edinburgh, UK

Abstract

Idiopathic Out-Of-Hospital Cardiac Arrest (OHCA) requires urgent treatment. Early Computed Tomography (CT) imaging may be useful to aid diagnosis. We aimed to determine current CT imaging practice, safety, and diagnostic value in this patient population.

Correspondence: Isla Harper, Edinburgh Medical School, College of Medicine and Veterinary Medicine, 49 Little France Crescent, Edinburgh, EH16 4SB, UK.
E-mail: islaharper@gmail.com

Key words: Cardiac arrest; computed tomography; emergency department.

Contributions: All authors were involved in the conception of the study, study design, analysis and interpretation of data and drafting the article. IH collected the data.

Funding: MJR is supported by an NHS Research Scotland Career Researcher Clinician award.

Conflict of interest: The authors declare no conflict of interest.

Availability of data and materials: All data generated or analyzed during this study are included in this published article.

Ethics approval and consent to participate: The study was deemed by the University of Edinburgh Ethics Committee to be a service evaluation survey and did not therefore require formal ethical approval. All patient data were anonymised prior to release from the NHS.

Informed consent: Not applicable.

Received for publication: 12 June 2022.

Accepted for publication: 13 September 2022.

This work is licensed under a Creative Commons Attribution 4.0 License (by-nc 4.0).

©Copyright: the Author(s), 2022

Licensee PAGEPress, Italy

Emergency Care Journal 2022; 18:10669

doi:10.4081/ecj.2022.10669

Publisher's note: All claims expressed in this article are solely those of the authors and do not necessarily represent those of their affiliated organizations, or those of the publisher, the editors and the reviewers. Any product that may be evaluated in this article or claim that may be made by its manufacturer is not guaranteed or endorsed by the publisher.

This study was a single-centre, retrospective cohort study of patients presenting to the Emergency Department (ED) of the Royal Infirmary of Edinburgh with idiopathic non-traumatic OHCA and Return Of Spontaneous Circulation (ROSC). Between 1st January 2016 and 31st December 2019, 140 of 156 (90%) eligible patients underwent 195 CT scans identifying the cause of OHCA in 6 (4%). CT head diagnosed one ischaemic and three haemorrhagic strokes, and CT pulmonary angiogram diagnosed one acute coronary syndrome and one pulmonary embolism. CT head (134), CT pulmonary angiogram (25) and CT cervical spine (16) were the commonest scans. 68 of 195 (35%) CT scans showed important pathology, mostly secondary to OHCA. CT imaging was safe with no cases of contrast nephropathy, allergic reaction, or other complications. The diagnostic value of CT imaging in this patient population was limited. However, imaging was a valuable method of identifying other important secondary pathology.

Introduction

Out-Of-Hospital Cardiac Arrest (OHCA) is the third leading cause of death in Europe.¹ In Scotland the resuscitation of around 3000 patients with OHCA is attempted annually.² Survival is slowly increasing but remains low at around 10% of cases where resuscitation was attempted.³

For patients resuscitated without an obvious cause (idiopathic OHCA), it is often difficult to identify the underlying pathology due to variety of diagnoses, lack of medical history, and intubation preventing communication.⁴ Urgent treatment necessitates early diagnosis. Current European Resuscitation Council (ERC) and European Society of Intensive Care Medicine guidelines for post-resuscitation care recommend investigations including an electrocardiogram (ECG), chest radiograph, coronary angiography +/- percutaneous coronary intervention (PCI), and computed tomography (CT) brain scan or CT pulmonary angiogram (CTPA). Whole-body CT (WBCT) is currently reserved for OHCA with trauma or haemorrhage.⁵ Despite this, investigations fail to identify the cause in 13% of patients.⁶

CT imaging is becoming more common to determine the arrest cause and evaluate resuscitation complications.⁷⁻⁹ A recent retrospective study found early WBCT imaging to be feasible and capable of identifying acute pathology relevant to OHCA aetiology and resuscitation.¹⁰ Subsequently, a prospective study reported that early head-to-pelvis CT scanning identified time-critical diagnoses within 2 hours, directly identified 13% of OHCA causes and resulted in significant, appropriate changes in management.¹¹

This single-centre, retrospective cohort study was designed to determine current CT imaging practice in non-traumatic idiopathic

OHCA in the Emergency Department (ED) of the Royal Infirmary of Edinburgh (RIE) and evaluate safety and diagnostic utility of CT imaging in identifying the aetiology of OHCA.

Materials and Methods

Study design, setting, and objectives

This was a single-centre, retrospective cohort study. It was carried out at the Emergency Department (ED) of the Royal Infirmary of Edinburgh (RIE), UK.

Our primary objective was to determine the diagnostic utility of CT imaging in identifying the cause of non-traumatic OHCA in adults attending the ED of the RIE, while our secondary objectives were: i) To determine current CT imaging practice in non-traumatic OHCA in the ED of the RIE; ii) To investigate whether CT imaging leads to changes in patient management; iii) To determine characteristics of patients who benefited from CT imaging; iv) To develop a decision-making tool to assist clinicians in determining which non-traumatic OHCA patients should be considered for CT imaging; v) To investigate CT safety including the incidence of contrast nephropathy, allergic reactions or other CT scanning complications, and the incidence of inappropriate further investigation or treatments.

The project was deemed a service evaluation and registered with the Lothian eQuIPED Registry. It did not require formal ethical review.

Participants

Patients with a presenting diagnosis of OHCA with Return of Spontaneous Circulation (ROSC), who presented to the ED at the RIE between 1st January 2016 and 31st December 2019 were eligible. The number of these patients determined sample size.

Inclusion criteria were: i) Diagnosis of non-traumatic OHCA with ROSC, ii) Attended the ED of the RIE and transferred to the Intensive Care Unit, iii) >14 years of age, iv) GCS \leq 8, v) no objective ECG or point-of-care imaging OHCA cause and 6) clinically stable to undergo CT imaging.

Exclusion criteria were: i) acute ST-elevation myocardial infarction (STEMI) or new left bundle branch block (LBBB) on ECG, ii) further investigation declined in documented Anticipatory Care Plan and iii) traumatic cause of OHCA.

Data collection

The RIE ED TrakCare (InterSystems) Electronic Patient Record (EPR) system containing all patients attending the RIE ED was interrogated by a data analyst to retrieve patients attending with OHCA for the past 5 years who were subsequently transferred to the Intensive Care Unit (ICU).

Patients were identified by a unique study number and recorded in the database. The study database was interrogated by a single researcher and potentially eligible patients were cross-referenced with their EPR medical notes by CHI or UHPI number (held and linked through the separate RIE ED TrakCare database) and inclusion and exclusion criteria applied. Reason for exclusion was documented for excluded patients. Patients were not identifiable without access to the RIE ED TrakCare database with study number linkage.

Definitions were created and applied for past medical history diagnoses. Heart disease included previous myocardial infarction, atrial fibrillation, ischaemic heart disease, valve disease, congenital heart disease, cardiomyopathy, previous PCI or stenting.

Chronic respiratory disease included chronic obstructive pulmonary disease, emphysema, and asthma. Chronic kidney disease was recorded. Chronic liver disease included alcoholic liver disease, non-alcoholic fatty liver disease or chronic hepatitis B/C infection. Previous CerebroVascular Accident included previous stroke or transient ischaemic event. Diabetes mellitus included Type I and Type II diabetes mellitus, gestational diabetes, and maturity-onset diabetes of the young. Any previous or current malignancy was noted. Epilepsy or seizure history was recorded. Missing data was recorded as such.

OHCA event data included presence of bystander CPR, ambulance response time, initial arrest rhythm on arrival of emergency services, total downtime, rearrest, prehospital or ED intubation, and vital signs on ED presentation.

CT scans were included if they were ordered in the ED. Scans included CT head, CT cervical spine, CT thorax, CT abdomen, CT pelvis, CT chest/abdomen/pelvis, CT intracranial angiogram, CT pulmonary angiogram, CT thoracic aorta and whole-body CT. The time from admission to scan order time was recorded.

CT imaging results were recorded, including the potential OHCA cause and any other important diagnoses that were identified. The cause of OHCA was taken as documented by the ICU clinician or detailed on the death certificate.

Outcome data included whether the patient was discharged from hospital or died, the hospital and ICU length of stay and safety endpoints. CT scans were said to have changed management if they identified the OHCA cause or identified other important diagnoses such as complications of resuscitation or arrest.

Study outcomes

Our primary endpoint was to determine the diagnostic utility of CT imaging in identifying the OHCA aetiology. Our secondary

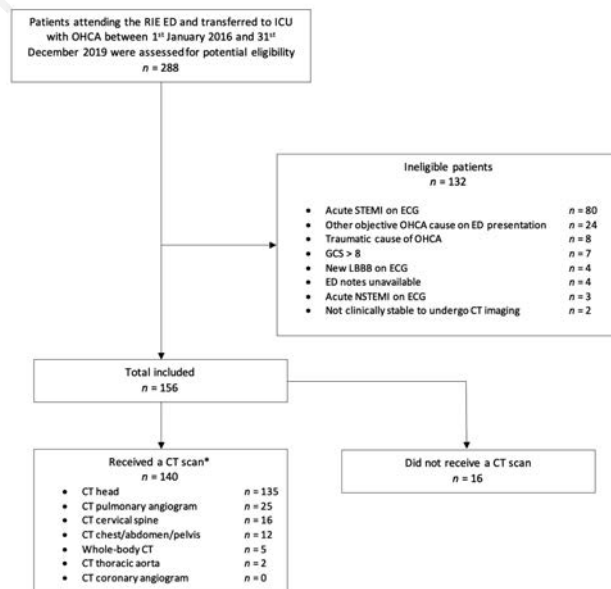


Figure 1. STROBE Diagram of patient recruitment. RIE, Royal Infirmary of Edinburgh; ED, Emergency Department; OHCA, out-of-hospital cardiac arrest; ICU, Intensive Care Unit; GCS, Glasgow Coma Score; STEMI, ST-elevation myocardial infarction; ECG, electrocardiogram; LBBB, left bundle branch block; NSTEMI, non-ST-elevation myocardial infarction; CT, computed tomography. *CT head' includes 134 CT head scans and 1 CT intracranial angiogram. 'CT chest/abdomen/pelvis' includes 7 CT chest/abdomen/pelvis scans, 1 CT chest scan, 2 CT abdomen scans and 2 CT pelvis scans.

endpoints were to determine: i) Incidence of CT imaging leading to changes in patient management; ii) Incidence of contrast nephropathy; iii) Incidence of allergic reactions or other complications of CT scanning; iv) Incidence of CT scanning resulting in inappropriate further investigation or treatment.

Data analysis

Data was entered into a database and analysed in Microsoft Excel. Unless otherwise stated, data are presented as median with Interquartile Range (IQR) (25th–75th percentile) for nonparametric continuous variables and as simple frequencies, proportions, and percentages for categorical variables. Parametric continuous variables are presented as mean with SD.

Statistical analysis

The characteristics of patients who benefited from CT imaging was compared to those that did not using either Chi-Squared test

with Yates correction for continuity, or Fisher Exact using two-tailed P-value, with significance set at the 5% level.

Results

Between 1st January 2016 and 31st December 2019, 288 patients presented to the RIE ED with ROSC after non-traumatic OHCA. 132 patients were excluded and 156 included. 140/156 (90%) received CT imaging and 16/156 (10%) did not (Figure 1). Mean age was 60 years, and 45/156 (29%) were female (Table 1).

42/156 (27%) patients experienced a documented prodrome before collapse (Table 2). The most common arrest rhythm was VF (76/156; 51%) with a median downtime of 23 (IQR 15-40) minutes. 50/156 (32%) patients rearrested. 120/156 (78%) had bystander CPR. Median ambulance response time was 5 (IQR 5-

Table 1. Demographics and Past Medical History of study patients.

Demographics and Past Medical History	All patients (n=156) n (%) or mean ± SD	Patients that received a CT scan (n=140) n (%) or mean ± SD	Patients with a positive CT scan* (n=58) n (%) or mean ± SD	Patients with a negative CT scan† (n=82) n (%) or mean ± SD	P value (2 decimal places)
Age (years)	60 ± 17	60 ± 16	58 ± 18	62 ± 15	0.14
Female sex	45 (29)	39 (28)	18 (31)	21 (26)	0.61
Medical history‡					
Heart disease	55 (37)	49 (37)	19 (35)	30 (38)	0.78
Hypertension	36 (24)	32 (24)	9 (17)	23 (29)	0.12
Chronic respiratory disease	19 (13)	18 (14)	7 (13)	11 (14)	1.00
Chronic kidney disease	11 (8)	8 (6)	2 (4)	6 (8)	0.47
Chronic liver disease	5 (3)	5 (4)	4 (7)	1 (1)	0.16
Cerebrovascular accident	14 (10)	12 (9)	3 (6)	9 (12)	0.36
Deep vein thrombosis	4 (3)	4 (3)	2 (4)	2 (3)	1.00
Diabetes	15 (10)	11 (8)	4 (7)	7 (9)	0.76
Malignancy	15 (10)	14 (11)	8 (15)	6 (8)	0.26
Seizures	9 (6)	9 (7)	3 (6)	6 (8)	0.74

* 'Positive' CT scan: identified OHCA cause or other important pathology. † 'Negative' CT scan: no pathology. ‡ 148 (95%) patients had complete past medical history information.

Table 2. Symptoms reported in study patients prior to collapse.

Prodrome Before Collapse	All patients (n=156) n (%)	Patients that received a CT scan (n=140) n (%)	Patients with a positive CT scan* (n=58) n (%)	Patients with a negative CT scan† (n=82) n (%)	P value (2 decimal places)
Prodrome	42 (27)	33 (24)	14 (24)	19 (23)	1.00
Chest pain‡	6 (14)	5 (15)	2 (14)	3 (16)	1.00
Palpitations	1 (2)	0	0	0	-
Dyspnoea	20 (48)	15 (45)	7 (50)	8 (42)	0.86
Abdominal pain	2 (5)	2 (6)	1 (7)	1 (5)	1.00
Back/flank pain	1 (2)	1 (3)	0	1 (5)	1.00
Jaw pain	1 (2)	0	0	0	-
Nausea/vomiting	5 (12)	5 (15)	3 (21)	2 (11)	0.65
Headache	1 (2)	1 (3)	1 (7)	0	0.41
Confusion	3 (7)	2 (6)	1 (7)	1 (5)	1.00
Dizziness	2 (5)	2 (6)	0	2 (11)	0.51
Drowsiness	3 (7)	2 (6)	1 (7)	1 (5)	1.00
Seizure	5 (12)	4 (12)	1 (7)	3 (16)	0.64
No prodrome	52 (33)	45 (32)	20 (34)	25 (30)	
Information not available	62 (40)	62 (44)	24 (41)	38 (46)	

* 'Positive' CT scan: identified OHCA cause or other important pathology. † 'Negative' CT scan: no pathology. ‡ Symptom percentages from patients with documented prodromes. Percentages total >100% as patients could have multiple symptoms.

11) minutes. 51/156 (33%) were intubated pre-hospital and 105/156 (67%) were intubated in the ED (Table 3). Of the 140 patients who received imaging, scans identified arrest cause in 6/140 (4%). CT head scans diagnosed 3 haemorrhagic strokes and one ischaemic stroke. One acute coronary syndrome and one pulmonary embolism were identified by CT pulmonary angiogram (Table 4).

The objective as to whether imaging changed management was assessed by the number of patients who received scans that identified the OHCA cause, or other important pathology ('positive' scan) compared to no CT findings ('negative' scan). 58/140 (41%) patients had a positive scan and 82/140 (59%) had no pathology on imaging. The most common other important diagnosis was hypoxic brain injury (30/140; 21%) (Table 4). Patients with asystole, patients not in VF, patients with a longer downtime, patients who rearrested and patients with unreactive pupils in the ED were all more likely to have positive findings on CT imaging (Table 3). The most common scan was CT head (135), followed by CTPA (25), CT cervical spine (16), and CT CAP (12). Overall, 6/195 (3%) of scans identified the arrest cause, 62/195 (32%) showed other

pathology and 127/195 (65%) were negative (Table 5).

The causes of OHCA as judged by the ICU clinician are shown in Table 6. 41/156 (26%) of patients had a cause potentially identifiable by CT, of which 7/41 (17%) received imaging. 57/156 (37%) patients had a cause that would not be identifiable by imaging. No diagnosis was made in 58/156 (37%) of patients.

48/156 (31%) patients survived to hospital discharge, with 13/58 (22%) of those with positive CT imaging surviving compared to 31/82 (38%) of those with no findings on CT ($p=0.08$). Median hospital length of stay was 30 (2–12) days and median ICU length of stay was 6 (2–6) days. No incidents of contrast nephropathy, allergic reactions to contrast or other imaging complications were identified. Scans did not result in inappropriate further investigations or treatments.

Discussion

This retrospective cohort study found that although the diagnostic utility of CT imaging in OHCA with ROSC was limited, CT

Table 3. Characteristics of the OHCA event in study patients.

OHCA Event*	All patients (n=156) n (%), mean \pm SD or median (IQR)	Patients that received a CT scan (n=140) n (%), mean \pm SD or median (IQR)	Patients with a positive CT scan†(n=58) n (%), mean \pm SD or median (IQR)	Patients with a negative CT scan‡ (n=82) n (%), mean \pm SD or median (IQR)	P value
Time of ED presentation					
12am – 6am	22 (14)	19 (14)	11 (19)	8 (10)	0.19
6am – 12pm	28 (18)	27 (19)	8 (14)	19 (23)	0.24
12pm – 6pm	56 (36)	50 (36)	24 (41)	26 (32)	0.32
6pm – 12am	50 (32)	44 (31)	15 (26)	29 (35)	0.31
Vital Signs on ED Presentation					
Pulse (bpm)	93 \pm 24	94 \pm 24	96 \pm 25	92 \pm 24	0.43
Systolic BP (mmHg)	119 \pm 38	119 \pm 38	117 \pm 43	121 \pm 36	0.64
Diastolic BP (mmHg)	75 \pm 26	75 \pm 26	77 \pm 30	74 \pm 24	0.72
Temperature ($^{\circ}$ C)	35.2 \pm 1.3	35.2 \pm 1.4	34.9 \pm 1.3	35.4 \pm 1.4	0.29
Left pupil size (mm) – median (IQR)	2 (2–4)	3 (2–4)	3 (2–4)	3 (2–4)	0.61
Right pupil size (mm) – median (IQR)	2 (2–4)	3 (2–4)	3 (3–4)	3 (2–4)	0.48
Left pupil reactivity					
Reactive	51 (53)	47 (53)	12 (35)	35 (64)	0.01§
Sluggish	14 (15)	13 (15)	3 (9)	10 (18)	0.26
Unreactive	31 (32)	29 (33)	19 (56)	10 (18)	0.006§
Right pupil reactivity					
Reactive	49 (52)	46 (52)	11 (32)	35 (64)	0.005§
Sluggish	14 (15)	13 (15)	3 (9)	10 (18)	0.26
Unreactive	32 (34)	30 (34)	20 (59)	10 (18)	0.003§
Arrest rhythm					
VF	76 (51)	67 (50)	22 (39)	46 (60)	0.05§
VT	3 (2)	2 (2)	0	2 (3)	1.00
PEA	32 (21)	31 (23)	14 (25)	17 (22)	0.79
Asystole	38 (26)	33 (25)	21 (37)	12 (16)	0.005§
Total downtime (minutes) – median (IQR)	23 (15–40)	30 (15–40)	36 (20–50)	22 (15–37)	0.02§
Patient rearrested	50 (32)	42 (30)	28 (48)	14 (17)	<0.0001§
Bystander CPR	120 (78)	106 (77)	44 (76)	62 (76)	0.86
Ambulance response time (minutes) – median (IQR)	5 (5–11)	7 (5–12)	7 (4–12)	6 (5–11)	0.99
Intubated pre-hospital	51 (33)	46 (33)	19 (33)	27 (33)	0.86
Intubated in ED	105 (67)	94 (67)	39 (67)	55 (67)	0.86

*Data was complete for intubation and rearrests. 154 (99%) of all patients had data for bystander CPR, 149 (96%) for arrest rhythm, 143 (92%) for downtime, 125 (80%) for pulse, 112 (72%) for systolic blood pressure, 100 (64%) for diastolic blood pressure, 96 (62%) for pupil reactivity, 67 (43%) for pupil diameter, 48 (31%) for temperature. †Positive CT scan: identified OHCA cause or other important pathology. ‡Negative CT scan: no pathology. §Significant at 5% level.

was a useful tool identifying other pathology mostly secondary to arrest or resuscitation. 140/156 (90%) patients underwent CT scanning ordered within an hour of ED arrival, most commonly CT head and CTPA. The arrest cause was identified by CT in only 6/140 (4%) patients, but 52/140 (37%) patients had other relevant pathology on imaging (4/140 (3%) had both the OHCA cause and other pathology on imaging). 82/140 (59%) had no findings. The most common other important diagnosis was hypoxic brain injury. Patients with asystole, patients not in VF, patients with a longer downtime, patients who rearrested and patients with unreactive pupils on ED admission were more likely to have positive imaging findings. CT imaging was safe with no instances of contrast

nephropathy, allergic reactions or other complications recorded.

Current guidelines for post-resuscitation care advise investigations such as ECG, chest radiograph and coronary angiography +/- PCI. CT head or CT chest imaging is recommended for early identification of neurological or respiratory causes, with whole body scanning reserved for OHCA with trauma or haemorrhage.⁵ Our study shows practice in the RIE ED conforms with this guidance.⁵

Our data support the use of head and chest CT imaging, with CT head and CTPA the only scan types to identify arrest causes. Cranial CT imaging identified all 4 patients with stroke as an arrest cause. CTPA scans diagnosed one patient with acute coronary syndrome and one with pulmonary embolism. CT imaging therefore

Table 4. Results of CT Imaging in study patients undergoing CT scan.

Results of CT Imaging (n=140)*	n (%)
OHCA cause diagnosed by CT	6 (4)
Haemorrhagic stroke	3 (2)
Ischaemic stroke	1 (1)
Acute coronary syndrome	1 (1)
Pulmonary embolism	1 (1)
Patients with other important diagnoses identified by CT**	56 (40)
Hypoxic brain injury	30 (21)
Rib fracture	20 (14)
Lobar collapse/consolidation	12 (9)
Cerebral oedema	10 (7)
Pneumonia	8 (6)
Pulmonary oedema	6 (4)
Pneumothorax	4 (3)
Cervical spine fracture	3 (2)
Flail segment	3 (2)
Raised ICP	2 (1)
Left ventricular systolic dysfunction	2 (1)
Intraabdominal haemorrhage	2 (1)
Mesenteric ischaemia due to CA	2 (1)
Traumatic brain injury	1 (1)
Ischaemic stroke due to CA	1 (1)
Pneumomediastinum	1 (1)
Surgical emphysema	1 (1)
Unruptured aortic aneurysm	1 (1)
Hydronephrosis	1 (1)
Patients with no findings on CT	82 (59)

*4 patients had both the OHCA cause and other pathology on imaging, 2 had OHCA cause but no other pathology, 52 had no cause but other important pathology. Percentages are of patients imaged (n=140). **Total diagnoses > total patients as patients could have multiple diagnoses.

Table 5. Type of CT scans performed in study patients undergoing CT scan.

CT Scans*	OHCA cause identified (n=6) n (%)	Other important diagnosis identified† (n=62) n (%)	Negative scans‡ (n=127) n (%)	Total number of scans	Time from presentation minutes (mean ± SD)
CT head	4 (3) [§]	31 (23)	100 (74)	135	35 ± 34
CT pulmonary angiogram	2 (8)	16 (64)	7 (28)	25	60 ± 124
CT cervical spine	0	2 (13)	14 (88)	16	22 ± 10
CT chest/abdomen/pelvis	0	8 (67)	4 (33)	12	69 ± 66
Whole-body CT	0	5 (100)	0	5	27 ± 28
CT thoracic aorta	0	0	2 (100)	2	72
CT coronary angiogram	-	-	-	0	-
All scans	6 (3)	62 (32)	127 (65)	195	39 ± 56

*CT head includes 134 CT head scans and 1 CT intracranial angiogram. †CT chest/abdomen/pelvis includes 7 CT chest/abdomen/pelvis scans, 1 CT chest scan, 2 CT abdomen scans and 2 CT pelvis scans. ‡These scans identified other important pathology but not the OHCA cause. §Negative CT scan: no pathology. ¶Percentages of total number of scan type. May total >100% due to rounding.

only diagnosed the cause of OHCA in 6/140 (4%) patients scanned (Table 4). This was surprising in context of previous research. The Parisian Region Out of Hospital Cardiac Arrest registry (PRO-CAT) reported 355 head and chest CT scans over ten years, diagnosing OHCA cause in 20%.¹² In 2021, Branch *et al.* diagnosed 39% of OHCA causes using early head-to-pelvis CT imaging of 100 patients in a prospective study.¹¹ The difference in diagnostic utility in this study may be because only 5 patients received a whole-body CT scan. When considering the recorded clinical cause of arrest, 41/156 (26%) of causes were potentially diagnosable by CT (Table 6).

52/140 (37%) patients had other relevant pathology on imaging, largely secondary to arrest or resuscitation. Hypoxic brain injury or cerebral oedema was present in 40/140 (29%), similar to rates of 35% in previous research.¹³ Such findings are relevant to intensive care management and prognostication.¹⁴ Chest findings likely secondary to arrest or resuscitation were common, with 20 rib fractures and 4 pneumothoraces. Plain chest radiography underestimates such CPR-related pathologies.¹⁵ Regurgitation and aspiration are known risks during arrest.^{16,17} We found 20 reports of lobar collapse/consolidation/pneumonia, clinically likely to represent aspiration.¹⁸ This is comparable to a previous retrospective study of 100 patients reporting CPR-related complications in 93%, and presumed aspiration-related pulmonary opacification in 77%.¹⁰

Overall, 58/140 (41%) of patients had 'positive' imaging (identified the arrest cause or other important pathology) that informed patient care, for example indications for antibiotic therapy (pneumonia), antithrombotics (pulmonary embolism) and their contraindications (haemorrhagic stroke, intraabdominal haemorrhage) and reasons for prompt surgical referral (flail segment, intraab-

dominal haemorrhage). Although it cannot be assessed in this study, imaging may have impacted care of patients without any pathological findings, for example by excluding catastrophic brain injury.

It was possible to identify the characteristics of patients with 'positive' CT imaging that were significantly different to those with only negative scans. Patients with asystole, patients not in VF, patients with a longer downtime, patients who rearrested and patients with unreactive pupils in the ED were all more likely to have positive findings. It is unsurprising that patients with clinical indicators of a more serious arrest showed pathology on imaging. In this scenario, positive findings on CT were more likely to be associated with devastating pathologies *i.e.*, PE and haemorrhagic stroke. Also, patients with VF cardiac arrest, which has a better prognosis, are more likely to have an underlying cardiac cause for their cardiac arrest, which is unlikely to be demonstrated on CT scan. The CASPRI scoring system is validated to predict neurological outcome after in-hospital cardiac arrest.¹⁹ Consistent with our results, asystole arrest and longer downtime indicate poor neurological outcome in the score.

A non-significant number of patients with positive scans died compared with those with negative scans [45/58 (86%) vs 51/82 (62%)]. Positive scans may be associated with worse survival due to the higher complication rate in this population.

The benefits of CT imaging must be weighed against the potential risks. Imaging was safe, with no incidents of acute kidney injury, allergic reaction or any other complications found, and no inappropriate treatments were instated because of imaging.

During this study the ERC published guidelines²⁰ that were adopted by our emergency and critical care departments,²¹ recommending CT head and CTPA in those with no evidence of myocar-

Table 6. The causes of OHCA as judged by the ICU clinician.

ICU/Clinical Cause of OHCA		
Cause potentially diagnosable by CT (n=41)	n (%)	Received CT imaging† (n=7) n (%)
Acute coronary syndrome*	33 (80)	2 (6)
Haemorrhagic stroke	3 (7)	3 (100)
Ischaemic stroke	1 (2)	1 (100)
Severe LVSD/Dilated cardiomyopathy	1 (2)	0
HOCM	1 (2)	0
Pulmonary embolism	1 (2)	1 (100)
Mesenteric ischaemia	1 (2)	0
Cause not diagnosable by CT (n=57)	n (%)	
Primary arrhythmia	32 (56)	
Substance use	8 (14)	
Respiratory arrest	5 (9)	
Influenza A	2 (4)	
Primary seizure	2 (4)	
Sepsis	2 (4)	
Electrolyte disorder	2 (4)	
COPD exacerbation	1 (2)	
Alcohol withdrawal	1 (2)	
Chemotherapy	1 (2)	
Graft vs host disease	1 (2)	
Unknown (n=58)		

*CT potentially able to detect coronary artery stenosis but not dynamic acute coronary syndrome. †Patients with a cause potentially identifiable by CT who received imaging. Percentage of patients with that diagnosis.

dial ischaemia to exclude neurological or respiratory causes of arrest. They describe four criteria indicating likely poor outcome, one of which is diffuse anoxic injury on brain CT or MRI. Our study lends further weight and evidence to these recommendations.

Limitations

There are several limitations to this study. It is single centre and retrospective and so has the associated drawbacks. For example, patient information was limited to what was recorded at the time, and decisions around whether a patient underwent CT scanning, and the focus of any imaging, was at the discretion of the treating clinician at the time. This is pertinent to the prodrome before arrest, where only 94/156 (60%) patients had information on symptoms recorded. If a record of symptoms prior to arrest had been more readily available, then it may have been possible to draw comparisons between symptoms and scan results. Secondly, as a single centre study, the participants may not be representative of the wider population.

One of the aims of this study was to develop a tool to aid decision making in the ED. Although we did find significant differences between those patients who showed pathology on imaging and those who did not, this was not a sufficient basis for a decision-making tool. In future greater sample sizes may allow the development of a decision-making tool based on vital signs and any prodromal symptoms. It may reveal a link between positive CT imaging and survival rates, informing prognostication for ongoing management decisions and communication with relatives.

Conclusions

9 in 10 patients presenting to the ED with idiopathic non-traumatic OHCA and ROSC underwent CT imaging. The diagnostic value of CT in this patient population was limited, with arrest cause identified in 4% of patients. Imaging was a valuable method of identifying other relevant pathology due to arrest or resuscitation in 37% of patients. Patients with asystole, patients not in VF, patients with a longer downtime, patients who rearrested and patients with unreactive pupils in the ED were more likely to have positive findings on CT imaging. CT head and CTPA were most performed. Imaging was safe with no recorded cases of contrast nephropathy, allergic reactions, complications, or inappropriate treatments.

References

- Gräsner J-T, Lefering R, Koster RW, et al. EuReCa ONE-27 Nations, ONE Europe, ONE Registry: A prospective one month analysis of out-of-hospital cardiac arrest outcomes in 27 countries in Europe. *Resuscitation* 2016;105:188-95.
- Scottish Out-of-Hospital Cardiac Arrest data linkage project: 2018/19 results. APS Group; 2020.
- Gräsner J-T, Wnent J, Herlitz J, et al. Survival after out-of-hospital cardiac arrest in Europe - Results of the EuReCa TWO study. *Resuscitation* 2020;148:218-26.
- Pokorna M, Necas E, Skripsky R, et al. How accurately can the aetiology of cardiac arrest be established in an out-of-hospital setting? Analysis by "Concordance in Diagnosis Crosscheck Tables". *Resuscitation* 2010;82:391-7.
- Nolan JP, Soar J, Cariou A, et al. European Resuscitation Council and European Society of Intensive Care Medicine 2015 guidelines for post-resuscitation care. *Int Care Med* 2015;41:2039-56.
- Hawkes C, Booth S, Ji C, et al. Epidemiology and outcomes from out-of-hospital cardiac arrests in England. *Resuscitation* 2017;110:133-40.
- Dunham GM, Perez-Girbes A, Bolster F, et al. Use of whole body CT to detect patterns of CPR-related injuries after sudden cardiac arrest. *Eur Radiol* 2018;28:4122-7.
- Choi SJ, Kim HS, Kim EY, et al. Thoraco-abdominal CT examinations for evaluating cause of cardiac arrest and complications of chest compression in resuscitated patients. *Emerg Radiol* 2014;21:485-90.
- Kashiwagi Y, Sasakawa T, Tampo A, et al. Computed tomography findings of complications resulting from cardiopulmonary resuscitation. *Resuscitation* 2015;88:86-91.
- Viniol S, Thomas RP, König AM, et al. Early whole-body CT for treatment guidance in patients with return of spontaneous circulation after cardiac arrest. *Emerg Radiol* 2020;27:23-9.
- Branch KRH, Strote J, Gunn M, et al. Early head-to-pelvis computed tomography in out-of-hospital circulatory arrest without obvious etiology. *Acad Emerg Med* 2021;28:394-403.
- Chelly J, Mongardon N, Dumas F, et al. Benefit of an early and systematic imaging procedure after cardiac arrest: Insights from the PROCAT (Parisian Region Out of Hospital Cardiac Arrest) registry. *Resuscitation* 2012;83:1444-50.
- Naples RMD, Ellison EMD, Brady WJMD. Cranial computed tomography in the resuscitated patient with cardiac arrest. *Am J Emerg Med* 2009;27:63-7.
- Metter RB, Rittenberger JC, Guyette FX, Callaway CW. Association between a quantitative CT scan measure of brain edema and outcome after cardiac arrest. *Resuscitation* 2011;82:1180-5.
- Lederer W, Mair D, Rabl W, Baubin M. Frequency of rib and sternum fractures associated with out-of-hospital cardiopulmonary resuscitation is underestimated by conventional chest X-ray. *Resuscitation* 2004;60:157-62.
- Oschatz E, Wunderbaldinger P, Sterz F, et al. Cardiopulmonary resuscitation performed by bystanders does not increase adverse effects as assessed by chest radiography. *Anesthesia Analgesia* 2001;93:128-33.
- Lawes EG, Baskett PJF. Pulmonary aspiration during unsuccessful cardiopulmonary resuscitation. *Intensive Care Med* 1987;13:379-82.
- Franquet T, Giménez A, Rosón N, et al. Aspiration diseases: findings, pitfalls, and differential diagnosis. *RadioGraphics* 2000;20:673-85.
- Girotra S, Nallamotheu BK, Chan PS. Using Risk Prediction Tools in Survivors of In-hospital Cardiac Arrest. *Current Cardiol Reports* 2014;16:1-8.
- Nolan JP, Sandroni C, Böttiger BW, et al. European Resuscitation Council and European Society of Intensive Care Medicine Guidelines 2021: Post-resuscitation care. *Resuscitation* 2021;161:220-69.
- Waterson F, Fleming G, Young N, et al. Out of Hospital Cardiac Arrest Guideline 2021 V5.0. 2022.