

Unusual diagnosis of urinothorax: a case report

Sanjith Saseedharan,¹ Edwin J. Pathrose,^{1,2} Vaibhav Kubal,³ Anand Pandhare¹

¹Intensive Care Unit, S.L. Raheja Hospital, Mumbai, Maharashtra, India; ²Smolensk State Medical Academy, Russia;

³Department of Pulmonology, S.L. Raheja Hospital, Mumbai, Maharashtra, India

Abstract

Urinothorax is a rare cause of pleural effusion characterized by the collection of urine in the pleural space. The index of suspicion should be higher when a pleural effusion is associated with cases of urinary tract obstruction or obstructive uropathy (renal calculi) and trauma. The characteristic feature in the diagnosis of urinothorax lies in the biochemistry, where the ratio of pleural fluid to serum creatinine is higher than 1. The present case is a unique instance of urinothorax with left urinoma and hydronephrosis where the ratio of pleural fluid to serum creatinine is below one.

Introduction

Urinothorax, as the term suggests, is the collection of urine in the pleural space. It is a rare case and a cause of pleural effusion. Its first case was reported in 1968 when the cause for the pleural effusion was found to be bilateral hydronephrosis.¹ This led to an awareness to include urinothorax as a differential diagnosis if no other etiology was to be found, which subsequently resulted in several reportings.^{2,3} On the basis of this, urinary tract obstruction or obstructive uropathy (renal calculi) and trauma⁴ (including iatrogenic injury post-percutaneous nephrolithotomy and extracorporeal shock wave lithotripsy)⁵ are considered to be the common causes of urinothorax, although malignancy⁶ and chronic alcoholic pancreatitis⁷ have also been mentioned in some reports. We present a unique case of urinothorax with left urinoma and hydronephrosis where the pleural fluid to serum creatinine ratio is less than 1.

Case Report

A 70-year-old hypertensive female presented in the Emergency Department of our Hospital

with complaints of abdominal distension with pain and anuria since 4 days. On examination, it was found that she had tachycardia and tachypnoea with a blood pressure of 180/90 mm Hg and her abdomen was distended with horseshoe dullness and no organomegaly suggestive of ascites. She was put on non-invasive ventilation as she was unable to maintain adequate saturation on an O₂ mask. Laboratory parameters showed a total leucocyte count (TLC) of 13,000/cu mm with a hemoglobin of 9 gm/dL; her serum creatinine was 10.48 mg/dL with blood urea nitrogen/creatinine ratio >20. She also had hyperkalemia (K⁺=6.5) with high anion gap metabolic acidosis (ABG pH-7.29, pCO₂-28, Po₂-86, HCO₃-11). In view of severe metabolic acidosis and hyperkalemia, she was first stabilized by doing hemodialysis (HD).

A computed tomography (CT) scan of the abdomen and pelvis was performed, which was indicative of a contracted right kidney with a bulky left kidney, along with evidence of moderate hydronephrosis of the left pelvicalyceal system and a long hyperdense soft plaque like lesion in the left renal pelvis and upper ureter. It was also indicative of bilateral pleural effusion, the left one showing around 400-500 cc, while the right one showing around 10 cc only (Figure 1) with ascites of approximately 1600 cc (Figure 2). After HD, the metabolic parameters started stabilizing and the patient was subjected to cystoscopy with retrograde pyelogram with left Double-J (DJ) stenting and drainage of left perinephric urinoma. During the procedure, it was observed that there was no intra-peritoneal dye extravasation (Figure 3). Ascitic fluid tapping with thoracentesis on the left side was done. Ascitic fluid analysis revealed a transudative, clear fluid alkaline in nature with a specific gravity of 1.010, protein 0.5 gm/dL, glucose 103 mg/dL, and TLC of 40/cu mm. A small sample of the pleural fluid sent for investigations revealed a pale yellow, transudative, clear fluid alkaline in nature with a specific gravity of 1.015, protein 0.23 gm/dL, glucose 150 mg/dL, and TLC of 104/cu mm. Both the aspirates had a pale yellow color with the odor of urine, which led us to investigate the creatinine levels of the fluids.

The creatinine level of the ascitic fluid was 12.26 mg/dL and the pleural fluid creatinine was 6.72 mg/dL with a pleural creatinine/serum creatinine ratio of 6.72/10.48 (=0.64), *i.e.* <1, which contradicts the biochemistry commonly acceptable for the diagnosis of urinothorax. Microbiological and cytopathological studies of the pleural and ascitic fluid were negative. However, she improved symptomatically post surgery, after tapping and correction of metabolic parameters. Subsequently, the patient did not require oxygen support and started having an adequate urine output. There was no recurrence of ascites or pleural effusion.

Correspondence: Edwin Joseph Pathrose, S.L. Raheja Hospital, Raheja Rugnalaya Marg, Mahim West, 400016 Mumbai, Maharashtra, India
E-mail: edwinjp7@gmail.com
Tel: +91.8452078924.

Key words: Urinothorax; Obstructive uropathy; Creatinine; Pleural effusion.

Contributions: SS, major role in diagnosis and internal review of manuscript; EP, collection of data and writing of manuscript; VK and AP, equal role in management of patient and necessary guidance in preparation of case report.

Conflicts of interest: the authors declare no potential conflict of interest.

Received for publication: 17 May 2016.
Revision received: 6 June 2016.
Accepted for publication: 10 June 2016.

This work is licensed under a Creative Commons Attribution NonCommercial 4.0 License (CC BY-NC 4.0).

©Copyright S. Saseedharan et al., 2016
Licensee PAGEPress, Italy
Chest Disease Reports 2016; 4:6001

Discussion

Urinothorax is a rare cause of pleural effusion. Its most common causes are obstructive uropathy or trauma, including iatrogenic trauma; however, other causes have also been reported, such as malignancy and chronic alcoholic pancreatitis.²⁻⁷ There are two routes via which urine can enter the pleural cavity: i) via lymphatic drainage;⁵ or ii) by seepage of abdominal fluid via diaphragmatic defects.⁸ Urinothorax most often are ipsilateral as in our case, but contralateral⁹ as well as bilateral effusions have also been observed.¹⁰

In urinothorax, the aspirated fluid has a pale yellow appearance with an odor of urine. There are few criteria to be fulfilled for a confirmed diagnosis, such as the fluid being transudative with an acidic pH and a pleural/serum creatinine ratio of >1, where the latter is considered as a typical characteristic of urinothorax.⁹ To support the biochemical analysis, imaging and surgical interventions can also be useful. From the radiological point of view, abdominal and thoracic CT scanning is indispensable in the detection of pleural effusions due to an abdominal cause with relation to the pelvicalyceal system.¹¹ Renal scintigraphy with the use of technetium-99m diethylene-triamine-pentaacetate, technetium-99m ethylene dicysteine, or technetium-99m-mercaptoacetyltriglycine-3 helps reveal the existence of an extravasation of urine from the kidney or

the ureter.¹²⁻¹⁴ Intravenous pyelography can also help detect any seepage of contrast from the retroperitoneal space into the pleural cavity, but sometimes this examination may not be useful.¹⁰ Correction of the urinary obstruction

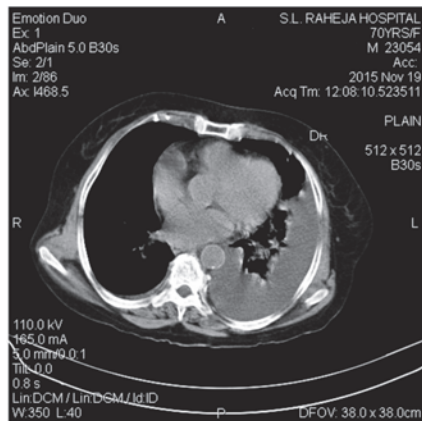


Figure 1. Chest computed tomography showing large left sided pleural effusion.

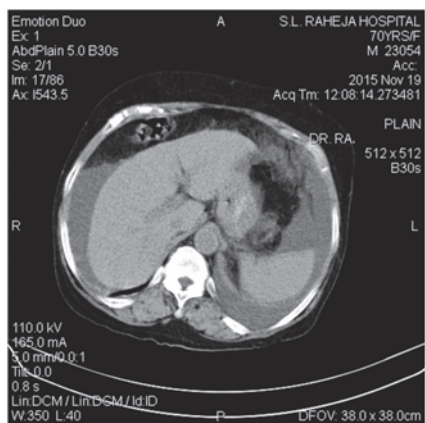


Figure 2. Abdomen computed tomography showing moderate-large ascites.

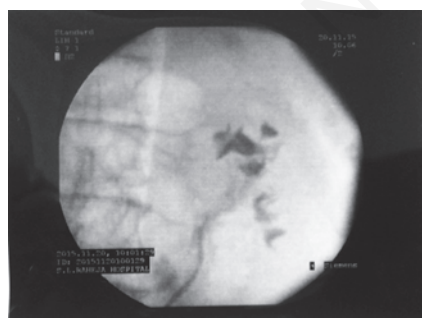

Figure 3. Retrograde pyelogram showing major and minor calyces with no dye extravasation.

generally leads to the resolution of the effusion with no recurrence; however, if the effusion still persists, then drainage of the urine through an intercostal thoracic tube is recommended.^{15,16} The reported cases of urinothorax are generally seen in adults; however, there are cases where it is diagnosed in children as well.¹⁷

In the present case, the pleural fluid biochemistry was altered due to HD, thus altering the pleural fluid/serum creatinine ratio¹⁸ and affecting the diagnosis. However, a history of obstructive uropathy combined with pleural effusion and radiological evidences of urine seepage as well as marked improvement in the patient's condition post-surgery, accompanied by a reduction without recurrence of pleural effusion post-DJ stenting was an indirect evidence confirming the diagnosis of urinothorax.

Conclusions

A proper history, clinical examination, biochemical analysis, and radiological findings of urinary seepage can be effective in making an early diagnosis of urinothorax. It should be considered as a differential diagnosis in patients with thoracic collection and urinary tract obstruction or in cases of unexplained pleural effusion. Hemodialysis alters the normal physiology of body fluids thereby rendering the pleural to serum creatinine level an unreliable marker to diagnose urinothorax in patients undergoing HD. The treatment of urinothorax is simple. The correction of the underlying cause is usually sufficient and results in a spontaneous resolution of the pleural effusion.

References

1. Corriere Jr JN, Miller WT, Murphy JJ. Hydronephrosis as a cause of pleural effusion I. *Radiology* 1968;90:79-84.
2. Javaloyas M, Picado MJ, Nonell F, et al. Massive pleural effusion secondary to hydronephrosis. *Rev Clin Esp* 1989;185:19-20.
3. Gurtner B. Urine in the wrong place: urothorax. *Schweiz Rundsch Med* 1994;83:30-5.
4. Hase T, Kodama M, Domasu S, et al. A case of urothorax that manifested as posttraumatic pleural effusion after a motorcycle

crash. *J Trauma* 1999;46:967-9.

5. Garcia-Pachon E, Romero S. Urinothorax: a new approach. *Curr Opin Pulm Med* 2006;12:259-63.
6. Karkoulias K, Sampsonas F, Kaparianos A, et al. Urinothorax: an unexpected cause of pleural effusion in a patient with non-Hodgkin lymphoma. *Eur Rev Med Pharmacol Sci* 2007;11:373-4.
7. Uchiyama T, Suzuki T, Adachi A, et al. Pancreatic pleural effusion: case report and review of 113 cases in Japan. *Am J Gastroenterol* 1992;87:387-91.
8. Huang PM, Chang YL, Yang CY, Lee YC. The morphology of diaphragmatic defects in hepatic hydrothorax: thoracoscopic finding. *J Thorac Cardiovasc Sur* 2005;130:141-5.
9. Stark DD, Shanes JG, Baron RL, Koch DD. Biochemical features of urinothorax. *Arch Intern Med* 1982;142:1509-11.
10. Laskaridis L, Kampantais S, Toutziaris C, et al. Urinothorax: an underdiagnosed cause of acute dyspnea: report of a bilateral and of an ipsilateral urinothorax case. *Case Rep Emerg Med* 2012;2012:395653.
11. Nusser RA, Culhane RH. Recurrent transudative effusion with an abdominal mass. *Chest* 1986;90:263-4.
12. Bhattacharya A, Venkataramarao SH, Kumar S, Mittal BR. Urinothorax demonstrated on 99mTc Ethylene dicysteine renal scintigraphy. *Nephrol Dial Transpl* 2007;22:1782-3.
13. Ralston MD, Wilkinson Jr RH. Bilateral urinothorax identified by technetium-99m DPTA renal imaging. *J Nucl Med* 1986;27:56-9.
14. Jelic S, Sampogna RV. Detection of unrecognized urinothorax with renal scintigraphy. *Kidney Int* 2009;76:353.
15. Roberts ME, Neville E, Berrisford RG, et al. Management of a malignant pleural effusion: British Thoracic Society pleural disease guideline 2010. *Thorax* 2010;65:32-40.
16. Pérez JM, Suárez PM, Gilart JF. Pleural empyema secondary to pyonephrosis. *Arch Bronconeumol* 2008;44:285.
17. Casallas A, Castaneda-Cardona C, Rosselli D. Urinothorax: case report and systematic review of the literature. *Urol Ann* 2016;8:91.
18. Corbett RW, Ashby DR. Complication of diagnostic pleural aspiration: is it of value in hemodialysis patients? *Hemodial Int* 2014;18:546-50.