



eISSN 2039-4772

<https://www.pagepressjournals.org/index.php/chest/index>

Publisher's disclaimer. E-publishing ahead of print is increasingly important for the rapid dissemination of science. The **Early Access** service lets users access peer-reviewed articles well before print / regular issue publication, significantly reducing the time it takes for critical findings to reach the research community.

These articles are searchable and citable by their DOI (Digital Object Identifier).

Chest Disease Reports is, therefore, e-publishing PDF files of an early version of manuscripts that have undergone a regular peer review and have been accepted for publication, but have not been through the typesetting, pagination and proofreading processes, which may lead to differences between this version and the final one. The final version of the manuscript will then appear in a regular issue of the journal.

E-publishing of this PDF file has been approved by the authors.

All legal disclaimers applicable to the journal apply to this production process as well.

Chest Disease Reports 2024 [online ahead of print]

To cite this article:

Saurabh Karmakar, Priya Sharma. Emerging immunological challenges in post-COVID individuals: insights from a case series and review. Chest Disease Reports. 2024;12:12659. doi:10.4081/cdr.12.12659



©The Author(s), 2024

Licensee **PAGEPress**, Italy

The publisher is not responsible for the content or functionality of any supporting information supplied by the authors. Any queries should be directed to the corresponding author for the article.

All claims expressed in this article are solely those of the authors and do not necessarily represent those of their affiliated organizations, or those of the publisher, the editors and the reviewers.

Any product that may be evaluated in this article or claim that may be made by its manufacturer is not guaranteed or endorsed by the publisher.

Emerging immunological challenges in post-COVID individuals: insights from a case series and review

Saurabh Karmakar,¹ Priya Sharma^{1,2}

¹Department of Pulmonary, Critical Care and Sleep Medicine, AIIMS Patna, Bihar;

²Junior Consultant, Indraprastha Apollo Hospitals, Delhi, India;

Corresponding author: Priya Sharma, Department of Pulmonary, Critical Care and Sleep Medicine, AIIMS Patna, Bihar, India.

E-mail: priyasharma25292@gmail.com

Key words: post-COVID sarcoidosis, post-COVID vasculitis, autoimmune complications, immunological complications, post-COVID.

Authors' contributions: all the authors made a substantive intellectual contribution. All the authors have read and approved the final version of the manuscript and agreed to be held accountable for all aspects of the work.

The publisher is not responsible for the content or functionality of any supporting information supplied by the authors. Any queries should be directed to the corresponding author for the article.

All claims expressed in this article are solely those of the authors and do not necessarily represent those of their affiliated organizations, or those of the publisher, the editors and the reviewers.

Any product that may be evaluated in this article or claim that may be made by its manufacturer is not guaranteed or endorsed by the publisher.

Conflict of interest: the authors declare no potential conflict of interest.

Funding: none.

Availability of data and materials: all data generated or analyzed during this study are included in this published article.

Informed consent: informed consent was obtained for all the cases reported.

The publisher is not responsible for the content or functionality of any supporting information supplied by the authors. Any queries should be directed to the corresponding author for the article.

All claims expressed in this article are solely those of the authors and do not necessarily represent those of their affiliated organizations, or those of the publisher, the editors and the reviewers.

Any product that may be evaluated in this article or claim that may be made by its manufacturer is not guaranteed or endorsed by the publisher.

Abstract

The Coronavirus Disease 2019 (COVID-19) pandemic has unveiled diverse immunological complications extending beyond the acute phase of infection. We present a case series of four patients who developed autoimmune vasculitis and sarcoidosis post-recovery from COVID-19. Case presentations include recurrent fever and respiratory symptoms in a 36-year-old female, granulomatous liver lesions in a 63-year-old male, progressive dyspnea in a 44-year-old female, and diffuse alveolar hemorrhage in a 74-year-old female following severe pneumonia. These cases underscore the importance of vigilance for immunological sequelae in post-COVID-19 patients, particularly those with predisposing comorbidities. We tried to elucidate pathophysiological mechanisms and optimize management strategies for these rare but clinically significant manifestations.

The publisher is not responsible for the content or functionality of any supporting information supplied by the authors. Any queries should be directed to the corresponding author for the article.

All claims expressed in this article are solely those of the authors and do not necessarily represent those of their affiliated organizations, or those of the publisher, the editors and the reviewers.

Any product that may be evaluated in this article or claim that may be made by its manufacturer is not guaranteed or endorsed by the publisher.

Introduction

The Coronavirus Disease 2019 (COVID-19) pandemic caused by a novel coronavirus has been identified to belong to the β -coronavirus family. Inflammation caused by COVID-19 infection may worsen pre-existing quiescent conditions but may also cause them *de novo*. One of the major causes of mortality linked to the COVID-19 pandemic has been diffuse alveolar damage and associated immune thrombosis in the pulmonary capillary network and adjacent vessels.^{1,2}

Although cases of immunological complications associated with COVID-19 have been reported, the association is very rare. Herein, we report a case series of four cases who developed immunological complications, Anti-Neutrophil Cytoplasmic Antibody (ANCA)-associated vasculitis, and sarcoidosis in the post-recovery phase of Coronavirus 2 (SARS-CoV-2) infection.

Case Report

Case 1

A 36-year-old female, non-smoker, known case of Diabetes Mellitus (DM) type 2, hypertension, and hypothyroidism (Anti-Thyroid Peroxidase, Anti TPO+) presented with c/o fever, anosmia, and ageusia during the third wave of COVID-19 pandemic, she was advised Reverse Transcriptase - Polymerase Chain Reaction (RT-PCR) for COVID-19 which turns out to be positive, and hence she was advised for home isolation and was prescribed symptomatic treatment in view of COVID-

The publisher is not responsible for the content or functionality of any supporting information supplied by the authors. Any queries should be directed to the corresponding author for the article.

All claims expressed in this article are solely those of the authors and do not necessarily represent those of their affiliated organizations, or those of the publisher, the editors and the reviewers.

Any product that may be evaluated in this article or claim that may be made by its manufacturer is not guaranteed or endorsed by the publisher.

19 with mild severity. She presented 3 weeks later with continued symptoms of dry cough and intermittent fever, documented up to 102°F. She also complained of loss of appetite and loss of weight. Her sputum, blood, and urine cultures were sterile. Chest x-ray and Computed Tomography (CT) of the chest was advised, and it showed bilateral multifocal areas of Ground Glass Opacity (GGO) and nodules (Figure 1a, Figure 1b). On further evaluation of history, she gave a history of spontaneous abortions thrice in a span of 4 years. The Antinuclear Antibody (ANA), Extractable Nuclear Antigen (ENA) profile, and Antiphospholipid Antibodies (APLA) workups were negative. She was treated with intravenous antibiotics and low doses of steroids, but she did not respond well. Repeat CT chest showed increased size and number of nodules in subsequent CT chest. Fiber optic bronchoscopy was done, and Bronchoalveolar Lavage (BAL) was negative for all stains and cultures (bacterial, fungal, and mycobacterial), Cartridge-Based Nucleic Acid Amplification Test (CBNAAT) was negative, galactomannan was 1.23, and transbronchial lung biopsy was inconclusive. Intravenous antifungal (Caspofungin) was added to the treatment; steroids were tapered, suspecting fungal infection. Thereafter, an ANCA profile showed weakly positive p-ANCA and negative c-ANCA.

The case was further reevaluated in view of vasculitis; peripheral blood smear showed Microcytic hypochromic anemia with normal iron stores and mild proteinuria, with no hematuria or casts. Non-Contrast Computed Tomography scan of the Paranasal Sinuses Coronal (NCCT PNS) showed opacification and mucoperiosteal thickening involving bilateral maxillary, ethmoid, sphenoid, and frontal sinuses, suggestive of pansinusitis with no definite bone erosion. Two-

The publisher is not responsible for the content or functionality of any supporting information supplied by the authors. Any queries should be directed to the corresponding author for the article.

All claims expressed in this article are solely those of the authors and do not necessarily represent those of their affiliated organizations, or those of the publisher, the editors and the reviewers.

Any product that may be evaluated in this article or claim that may be made by its manufacturer is not guaranteed or endorsed by the publisher.

dimensional (2D) echo was normal, with an Ejection Fraction (EF) of 55%. Ultrasonography (USG) of the whole abdomen showed hepatomegaly with steatosis, raised renal cortical echogenicity, and subserosal fibroid. USG of the neck showed thyroiditis with sialadenitis. Positron Emission Tomography - Computed Tomography (PET-CT) showed metabolically active bilateral lung nodules with pleural thickening and bilateral pleural effusion. Pleural effusion diagnostic tap was mainly hemorrhagic and revealed protein 4.5gm%, glucose 345 mg/dL, Adenosine Deaminase (ADA) 28.6, Total Leucocyte Count (TLC) 65/mm³ with neutrophil 30%, and lymphocyte 70%. CT-guided biopsy from the lung nodule was inconclusive, and tissue fungal stain was negative for fungi, nocardia, and histoplasma. Considering the above features, a diagnosis of auto-immune vasculitis was made, and the patient was started on intravenous pulse steroids for 3 days, followed by oral tapering of steroids. The patient was also given injected rituximab infusion according to body surface area. The patient improved symptomatically and radiologically (Figure 1c, Figure 1d) and was discharged with a follow-up for a repeat rituximab infusion.

Case 2

A 63-year-old man, non-smoker, known case of DM, hypertension, and hypothyroidism presented with dry cough and dyspnea with Modified Medical Research Council (mMRC) grade 2 for 2 months. He also complained of loss of appetite and weight and a history of mild COVID-19

The publisher is not responsible for the content or functionality of any supporting information supplied by the authors. Any queries should be directed to the corresponding author for the article.

All claims expressed in this article are solely those of the authors and do not necessarily represent those of their affiliated organizations, or those of the publisher, the editors and the reviewers.

Any product that may be evaluated in this article or claim that may be made by its manufacturer is not guaranteed or endorsed by the publisher.

pneumonia 7 months prior. He had no family history of pulmonary fibrosis, pulmonary sarcoid, COPD, or any other lung disease. He was on a combination of voglibose, glimepiride, vildagliptin, and metformin for diabetes, olmesartan for hypertension, and levothyroxine for hypothyroidism. Chest X-ray and Contrast-Enhanced Computed Tomography (CECT) of the thorax revealed bilateral lower lobe diffuse GGOs and reticulations with mediastinal lymphadenopathy (Figure 2a, Figure 2b). CECT of the abdomen revealed multiple small nodular hypoechoic lesions in both liver and spleen with splenomegaly (Figure 2c). An empirical diagnosis of granulomatous disease was thought. On evaluation during admission, his hemoglobin was found to be 6.1, and he was positive for Indirect Coomb's test, was transfused with the least compatible match, and bone marrow aspiration was done, which showed age-related changes. 2D-echo revealed mild aortic regurgitation and tricuspid regurgitation with left ventricular hypertrophy and EF of 45-50%. USG-guided biopsy from the liver nodule revealed granulomatous inflammation. Fiberoptic bronchoscopy showed a normal bilateral bronchial tree, BAL CBNAAT was negative, and a transbronchial lung biopsy showed non-necrotizing granulomatous inflammation (Figure 2d). The Mantoux test was negative, and serum ACE levels were 74 U/L. A diagnosis of post-COVID-19 induced sarcoidosis was made, and the patient was started on steroids and improved symptomatically.

Case 3

The publisher is not responsible for the content or functionality of any supporting information supplied by the authors. Any queries should be directed to the corresponding author for the article.

All claims expressed in this article are solely those of the authors and do not necessarily represent those of their affiliated organizations, or those of the publisher, the editors and the reviewers.

Any product that may be evaluated in this article or claim that may be made by its manufacturer is not guaranteed or endorsed by the publisher.

A 44-year-old female, non-smoker, presented with complaints of gradually progressive exertional dyspnea on exertion after recovery from COVID-19 infection (moderate severity). She denied any respiratory symptoms before the COVID-19 Infection. She was also a known case of uncontrolled DM with HbA1c=9.2, Fasting Blood Sugar (FBS) 151mg/dL, and Post-Prandial Blood Sugar (PPBS) 202 mg/dL at the time of presentation. For diabetes, she was on a combination of metformin and teneligliptin. Chest X-ray and CECT of the chest showed patchy GGOs in the left perihilar region and bilateral lung bases with hilar adenopathy (Figure 3a, Figure 3b). Spirometry showed restrictive impairment with Forced Vital Capacity (FVC) of 58% of predicted values. Before presenting to us, the patient has taken various courses of oral and intravenous antibiotics and antihistaminics. The patient was evaluated further and found to be Mantoux negative, serum ACE 68 U/L. Although ANA screening was positive, the ENA profile was negative. An empirical diagnosis of pulmonary sarcoidosis was made. The patient was planned for fiber optic bronchoscopy; BAL was negative for all stains and cultures. However, trans-bronchial lung biopsy showed well-formed sarcoid-like granulomas, with few showing necrosis in a background of mild chronic inflammatory changes. The patient was initiated with oral steroids according to body weight. The patient is under follow-up at present, with symptomatic improvement.

Case 4

The publisher is not responsible for the content or functionality of any supporting information supplied by the authors. Any queries should be directed to the corresponding author for the article.

All claims expressed in this article are solely those of the authors and do not necessarily represent those of their affiliated organizations, or those of the publisher, the editors and the reviewers.

Any product that may be evaluated in this article or claim that may be made by its manufacturer is not guaranteed or endorsed by the publisher.

A 74-year-old female, non-smoker, presented with complaints of cough with minimal mucoid expectoration and gradually progressive exertional dyspnea for one year, progressing to mMRC grade 4 at the time of presentation. The patient also gave a history of one episode of blood-stained sputum two days before presenting, and her SpO₂ at the time of presentation was 72% room air. She has been a known case of hypertension and hypothyroidism for 10 years, for which she was taking tablets telmisartan-amlodipine and levothyroxine, respectively. On further evaluation, she had a past history of severe COVID-19 pneumonia almost 1.5 years ago and was managed with oxygen and IV remdesivir in the Intensive Care Unit (ICU) for one month. The patient was admitted and evaluated further. Blood investigations showed a hemoglobin of 8.9 g/dL, liver and kidney function at rest were normal. Urine analysis showed mild proteinuria with 2-3 red blood cells per high-power field and no casts. CECT chest s/o emphysematous changes seen involving apical segments of the bilateral upper lobe and superior segment of the left lower lobe. Para septal emphysematous changes were seen in the bilateral upper lobe and basal segments of the lower lobe. Diffuse GGOs were seen in the bilateral lung, suggesting diffuse alveolar hemorrhage. (Figure 4a, Figure 4b) The vasculitis profile showed positivity for Antigen Myeloperoxidase (MPO, or p-ANCA) and negative for proteinase 3 and Glomerular Basement Membrane (GBM). 2D-echo revealed mild concentric left ventricular hypertrophy with preserved systolic function, mild aortic sclerosis, trace mitral and tricuspid regurgitation, and EF of 50%. ANA screening was positive, and the ENA profile was positive for SS-A (both Ro52 and Ro60). A diagnosis of post-COVID p-ANCA associated vasculitis with diffuse alveolar hemorrhage was made. Bronchoscopy

The publisher is not responsible for the content or functionality of any supporting information supplied by the authors. Any queries should be directed to the corresponding author for the article.

All claims expressed in this article are solely those of the authors and do not necessarily represent those of their affiliated organizations, or those of the publisher, the editors and the reviewers.

Any product that may be evaluated in this article or claim that may be made by its manufacturer is not guaranteed or endorsed by the publisher.

could not be done in this patient due to high oxygen requirement and lack of consent. The patient was managed with intravenous steroids, and gradual improvement in hemoglobin and SpO₂ was seen.

Discussion

With the evolution of the COVID-19 pandemic, many related aspects are explored. Numerous anti-inflammatory therapeutic clinical trials have been conducted in the literature, offering the chance to find immune modulators that may help not just COVID-19 but also immune-mediated damage to distant organs. Therefore, SARS-CoV-2 has the potential to cause long-term harm in a variety of body parts through direct tissue damage and fibrosis, collateral damage from excessive inflammation, post-viral autoimmunity, and the effects of thrombotic complications.³

Despite the similar demographics of RT-PCR-positive patients, the immune responses found post-SARS-CoV-2 infection are immensely diverse, ranging from many to almost none. Individuals with more severe diseases are believed to frequently have increased amounts of antibodies. Considering this virus can cause type II and IV hypersensitivity reactions in addition to their specific cytopathic effect, COVID-19-mediated autoimmunity could be plausible.⁴ Various autoimmune complications have been reported post-COVID-19 infection, including CNS (GBS, acute motor axonal neuropathy),^{5,6} thrombocytopenia,⁷ Evans Syndrome,⁸ and autoimmune endocrine pathologies in the literature.

The publisher is not responsible for the content or functionality of any supporting information supplied by the authors. Any queries should be directed to the corresponding author for the article.

All claims expressed in this article are solely those of the authors and do not necessarily represent those of their affiliated organizations, or those of the publisher, the editors and the reviewers.

Any product that may be evaluated in this article or claim that may be made by its manufacturer is not guaranteed or endorsed by the publisher.

ANCA-associated vasculitides are rare diseases with an incidence of around 10 to 20 cases per million. Among all, Granulomatosis with Polyangiitis (GPA) is the most common disease, followed by Eosinophilic Granulomatosis with Polyangiitis (EGPA).⁹⁻¹¹ Literature shows similar pathogenetic mechanisms and clinical-radiological aspects between the hyper-inflammatory diseases and COVID-19. This might explain SARS-CoV-2 acting as a trigger for developing a rapid autoimmune and/or autoinflammatory dysregulation.¹² A part of the COVID-19 virus antigen is presented on the surface of antigen presentation cells (APC), which plays a crucial role in the body's immune response and ultimately leads to the production of IgM and IgG antibodies.¹³ In general, T cells are the major immune cells that fight against viral infections in the body either via the production of virus-specific antibodies (CD4-T cells mediated response) or by killing the virus-infected cells (CD8+ T cells mediated response).¹⁴

Only hypotheses can be made when we try to find a specific trigger in all cases of previously healthy people with a history of recent COVID-19 infection. One hypothesis is that COVID-19 acted as a trigger for ANCA-associated vasculitis and sarcoidosis.

On searching the literature further, few reports showed that COVID-19 patients showed a marked reduction in CD4+ and CD8+ T cell population, whereas the high proportions of HLA-DR and CD38 double-positive fractions indicate the hyperactivated status of T cells imparting severe immune injury.¹⁵ So, there could be several possible mechanisms involved in the depletion and dysfunction of T lymphocytes induced by SARS-CoV-2 such as it can directly infect T cells and

The publisher is not responsible for the content or functionality of any supporting information supplied by the authors. Any queries should be directed to the corresponding author for the article.

All claims expressed in this article are solely those of the authors and do not necessarily represent those of their affiliated organizations, or those of the publisher, the editors and the reviewers.

Any product that may be evaluated in this article or claim that may be made by its manufacturer is not guaranteed or endorsed by the publisher.

macrophages by binding to the surface markers (CD 26 and CD 147) or the ACE-2 receptors present on their surface.¹⁶

In our second and third cases, though it is difficult to prove whether sarcoidosis was present prior to COVID-19 infection or developed as sequelae to COVID-19 Infection or if COVID-19 unmasked the symptoms of asymptomatic sarcoidosis. However, seeing the history of both the patient and considering that there were no clinical or radiographic symptoms or signs of sarcoidosis before the COVID-19 infection, perturbation of the immune system is likely a causative agent in his development of sarcoidosis.

Autoantibodies to ANA and ENA have been seen in post-COVID-19 patients, with a frequency of 35.6% of autoantibodies to ANA and 25% of anti-Ro/SSA.¹⁷ Our last case also had positivity to ANA and SS-A in the ENA profile.

Conclusions

Immunological diseases are rare but disabling conditions that negatively affect an individual's quality of life, family, and healthcare. On the other hand, the COVID-19 pandemic is associated with different concurrent complications and potential sequelae that may emerge either early or late after the pandemic. Learning from the evolving evidence of COVID-19-mediated autoimmunity, it might be fair to think of autoimmune diseases as a serious complication of COVID-19. At the same time, comprehending the pathophysiology of this association can further help illuminate the

The publisher is not responsible for the content or functionality of any supporting information supplied by the authors. Any queries should be directed to the corresponding author for the article.

All claims expressed in this article are solely those of the authors and do not necessarily represent those of their affiliated organizations, or those of the publisher, the editors and the reviewers.

Any product that may be evaluated in this article or claim that may be made by its manufacturer is not guaranteed or endorsed by the publisher.

mechanism of viral injury to the host's body, whether it is the direct viral injury or autoimmune reactivity, which promotes a better and more efficient treatment strategy design.

The publisher is not responsible for the content or functionality of any supporting information supplied by the authors. Any queries should be directed to the corresponding author for the article.

All claims expressed in this article are solely those of the authors and do not necessarily represent those of their affiliated organizations, or those of the publisher, the editors and the reviewers.

Any product that may be evaluated in this article or claim that may be made by its manufacturer is not guaranteed or endorsed by the publisher.

References

1. Al-Ani F, Chehade S, Lazo-Langner A. Thrombosis risk associated with COVID-19 infection. A scoping review. *Thromb Res.* 2020;192:152-60.
2. Fox SE, Akmatbekov A, Harbert JL, et al. Pulmonary and cardiac pathology in African American patients with COVID-19: an autopsy series from New Orleans. *Lancet Respir Med.* 2020;8:681-6.
3. British Society for Immunology. Long-term Immunological health consequences of COVID-19. 2020. Available from: https://www.immunology.org/sites/default/files/2022-09/BSI_Long_Term_Immunology_Health_Consequences_Covid-19.pdf
4. Lin Y, Askonas B. Biological properties of an influenza A virus-specific killer T cell clone. Inhibition of virus replication in vivo and induction of delayed-type hypersensitivity reactions. *J Exp Med.* 1981;154:225-34.
5. Zhao H, Shen D, Zhou H, et al. Guillain-Barre syndrome associated with SARS-CoV-2 infection: causality or coincidence? *The Lancet Neurology.* 2020;19:383-4.
6. Ray A. Miller Fisher syndrome and COVID-19: is there a link? *BMJ Case Rep.* 2020;13:e236419.
7. Guan W-J, Ni ZY, Hu Y, et al. Clinical characteristics of coronavirus disease 2019 in China. *N Engl J Med.* 2020;382:1708-20.

The publisher is not responsible for the content or functionality of any supporting information supplied by the authors. Any queries should be directed to the corresponding author for the article.

All claims expressed in this article are solely those of the authors and do not necessarily represent those of their affiliated organizations, or those of the publisher, the editors and the reviewers.

Any product that may be evaluated in this article or claim that may be made by its manufacturer is not guaranteed or endorsed by the publisher.

8. Hindilerden F, Yonal-Hindilerden I, Akar E, et al. Severe autoimmune hemolytic anemia in COVID-19 infection, safely treated with steroids. *Mediterr J Hematol Infect Dis.* 2020;12:2020053
9. Watts RA, Lane SE, Bentham G, Scott DG. Epidemiology of systemic vasculitis: a ten-year study in the United Kingdom. *Arthritis Rheum.* 2000;43:414-9.
10. Gonzalez-Gay MA, Garcia-Porrúa C, Guerrero J, et al. The epidemiology of the primary systemic vasculitides in northwest Spain: implications of the Chapel Hill Consensus Conference definitions. *Arthritis Rheum.* 2003;49:388-93.
11. Mohammad AJ, Jacobsson LT, Westman KW, et al. Incidence and survival rates in Wegener's granulomatosis, microscopic polyangiitis, Churg-Strauss syndrome and polyarteritis nodosa. *Rheumatology (Oxford).* 2009;48:1560-5.
12. Caso F, Costa L, Ruscitti P. Could Sars-Coronavirus-2 trigger autoimmune and / or autoinflammatory mechanisms in genetically predisposed subjects? *Autoimmune Rev.* 2020;19:102524.
13. Li G., Chen X., Xu A. Profile of specific antibodies to the SARS-associated coronavirus. *N. Engl. J. Med.* 2003;349:508-9.
14. Mubarak A, Alturaiki W, Hemida MG. Middle East Respiratory Syndrome Coronavirus (MERS-CoV): Infection, Immunological Response, and Vaccine Development. *Journal of Immunology Research.* 2019;2019:6491738

The publisher is not responsible for the content or functionality of any supporting information supplied by the authors. Any queries should be directed to the corresponding author for the article.

All claims expressed in this article are solely those of the authors and do not necessarily represent those of their affiliated organizations, or those of the publisher, the editors and the reviewers.

Any product that may be evaluated in this article or claim that may be made by its manufacturer is not guaranteed or endorsed by the publisher.

15. Xu X-W, Wu X-X, Jiang X-G, et al. Clinical findings in a group of patients infected with the 2019 novel coronavirus (SARS-Cov-2) outside of Wuhan, China: retrospective case series. *BMJ* 2020;368:m606.
16. García LF. Immune response, inflammation, and the clinical spectrum of COVID-19. *Front. Immunol.* 2020;11:1441.
17. Gazzaruso C, Stella NC, Mariani G, et al. High prevalence of antinuclear antibodies and lupus anticoagulant in patients hospitalized for SARS-CoV2 pneumonia. *Clin. Rheumatol.* 2020;39:2095-7.

The publisher is not responsible for the content or functionality of any supporting information supplied by the authors. Any queries should be directed to the corresponding author for the article.

All claims expressed in this article are solely those of the authors and do not necessarily represent those of their affiliated organizations, or those of the publisher, the editors and the reviewers.

Any product that may be evaluated in this article or claim that may be made by its manufacturer is not guaranteed or endorsed by the publisher.

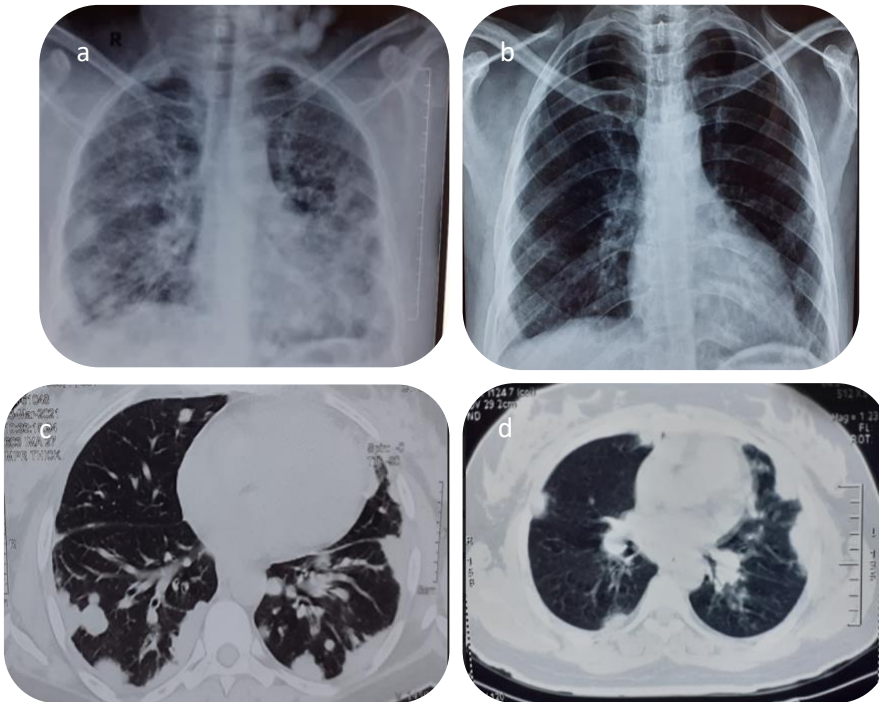


Figure 1. Case 1. Chest X-ray **a)** at presentation, **b)** after treatment; Computed Tomography (CT) of the thorax showing **c)** multiple nodules in bilateral lung, **d)** a decrease in the number of nodules after the treatment.

The publisher is not responsible for the content or functionality of any supporting information supplied by the authors. Any queries should be directed to the corresponding author for the article.

All claims expressed in this article are solely those of the authors and do not necessarily represent those of their affiliated organizations, or those of the publisher, the editors and the reviewers.

Any product that may be evaluated in this article or claim that may be made by its manufacturer is not guaranteed or endorsed by the publisher.

a,b)

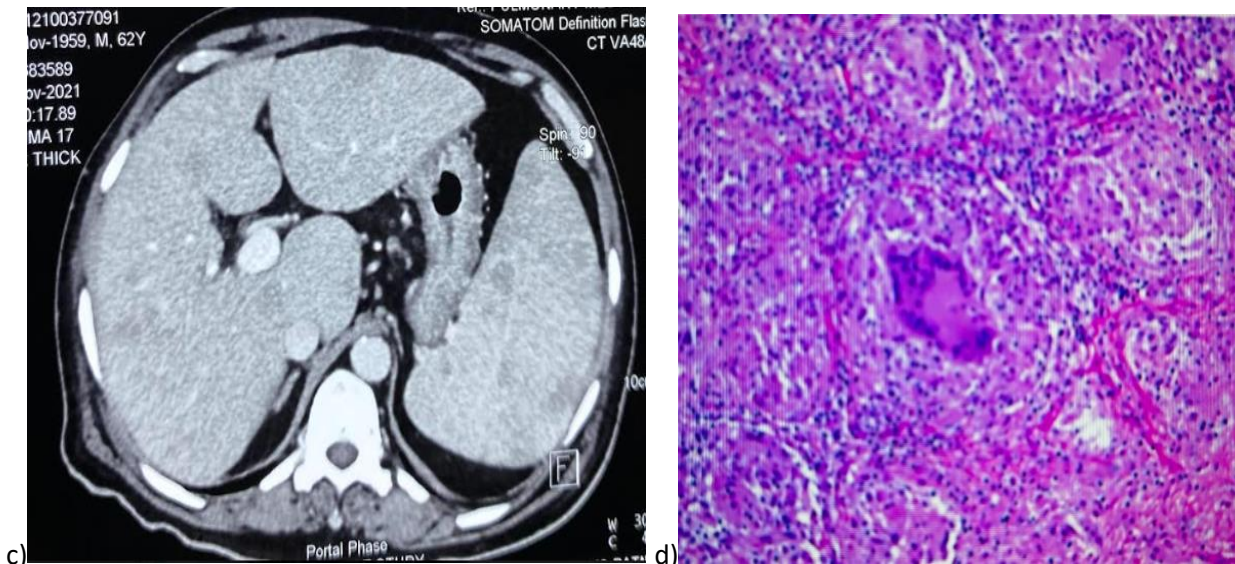
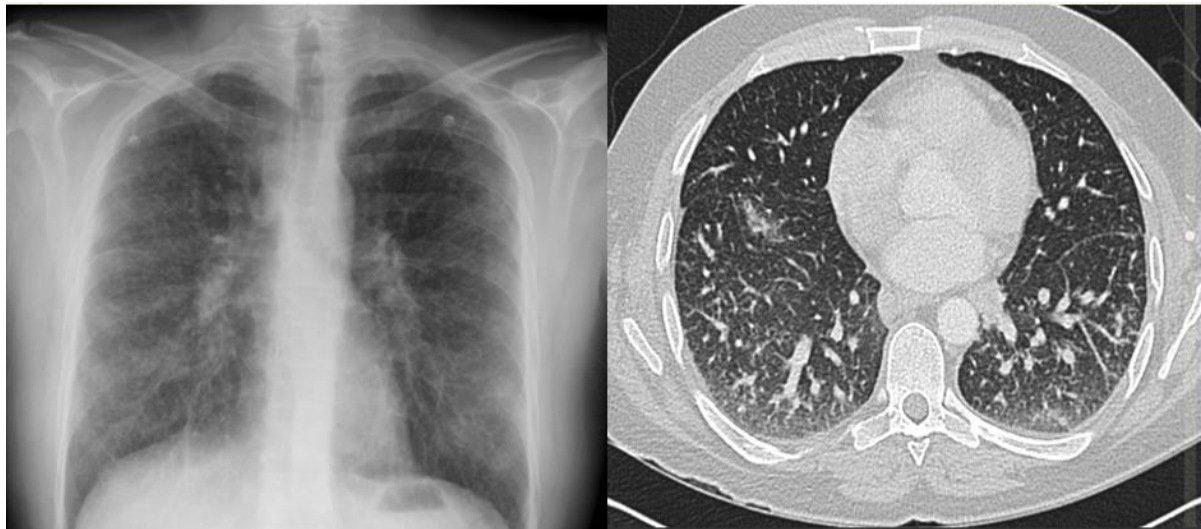


Figure 2. Case 2. **a)** Chest X-ray and **b)** Contrast-Enhanced Computed Tomography (CECT) of the thorax revealed bilateral lower lobe diffuse Ground Glass Opacities (GGOs) and reticulations with mediastinal lymphadenopathy. **c)** CECT abdomen revealed multiple small nodular

The publisher is not responsible for the content or functionality of any supporting information supplied by the authors. Any queries should be directed to the corresponding author for the article.

All claims expressed in this article are solely those of the authors and do not necessarily represent those of their affiliated organizations, or those of the publisher, the editors and the reviewers.

Any product that may be evaluated in this article or claim that may be made by its manufacturer is not guaranteed or endorsed by the publisher.

hypoechoic lesions in both liver and spleen with splenomegaly, and **d)** transbronchial lung biopsy was taken, which showed non-necrotizing granulomatous inflammation.

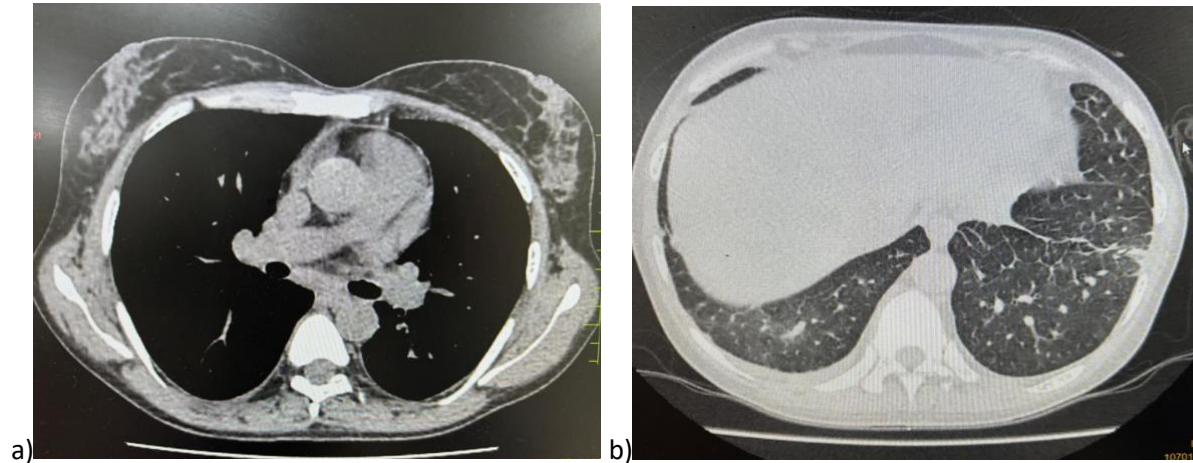


Figure 3. a) Computed Tomography (CT) of the thorax revealing bilateral lower lobe ground glass opacities and **b)** reticulations with subcarinal and right hilar mediastinal lymphadenopathy.

The publisher is not responsible for the content or functionality of any supporting information supplied by the authors. Any queries should be directed to the corresponding author for the article.

All claims expressed in this article are solely those of the authors and do not necessarily represent those of their affiliated organizations, or those of the publisher, the editors and the reviewers.

Any product that may be evaluated in this article or claim that may be made by its manufacturer is not guaranteed or endorsed by the publisher.

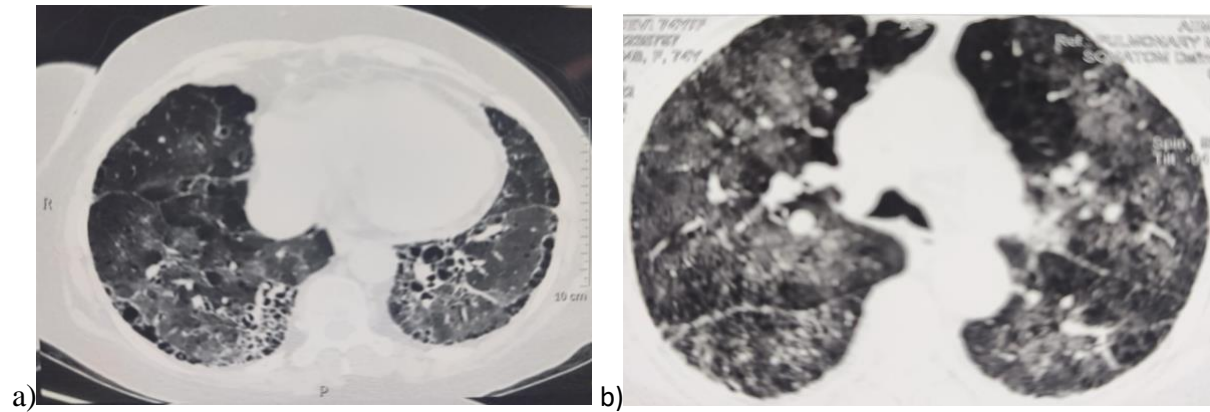


Figure 4. a) Para septal emphysematous changes were seen involving the superior segment of the left lower lobe and b) bilateral basal segments of the lower lobe. Diffuse GGOs were seen in the bilateral lung.

The publisher is not responsible for the content or functionality of any supporting information supplied by the authors. Any queries should be directed to the corresponding author for the article.

All claims expressed in this article are solely those of the authors and do not necessarily represent those of their affiliated organizations, or those of the publisher, the editors and the reviewers.

Any product that may be evaluated in this article or claim that may be made by its manufacturer is not guaranteed or endorsed by the publisher.