



eISSN 2039-4772

<https://www.pagepressjournals.org/index.php/chest/index>

Publisher's disclaimer. E-publishing ahead of print is increasingly important for the rapid dissemination of science. The **Early Access** service lets users access peer-reviewed articles well before print / regular issue publication, significantly reducing the time it takes for critical findings to reach the research community. These articles are searchable and citable by their DOI (Digital Object Identifier).

Chest Disease Reports is, therefore, e-publishing PDF files of an early version of manuscripts that have undergone a regular peer review and have been accepted for publication, but have not been through the typesetting, pagination and proofreading processes, which may lead to differences between this version and the final one. The final version of the manuscript will then appear in a regular issue of the journal.

E-publishing of this PDF file has been approved by the authors.

All legal disclaimers applicable to the journal apply to this production process as well.

Chest Disease Reports 2024 [online ahead of print]

To cite this article:

Pratibha Gupta Gogia, Shriram S. Shenoy, Tarun Bhatnagar, et al. The holy fluke - an unusual scenario of lung paragonimiasis. Chest Disease Reports. 2024;12:12418. doi:10.4081/cdr.12.12418

 ©The Author(s), 2024
Licensee PAGEPress, Italy

*The publisher is not responsible for the content or functionality of any supporting information supplied by the authors. Any queries should be directed to the corresponding author for the article.
All claims expressed in this article are solely those of the authors and do not necessarily represent those of their affiliated organizations, or those of the publisher, the editors and the reviewers.
Any product that may be evaluated in this article or claim that may be made by its manufacturer is not guaranteed or endorsed by the publisher.*

The holy fluke - an unusual scenario of lung paragonimiasis

Pratibha Gupta Gogia, Shriram S. Shenoy, Tarun Bhatnagar, Shruti Dogra, Sunil Laka

Department of Respiratory Medicine, Venkateshwar Hospital, Dwarka, New Delhi, India

Corresponding author: Pratibha Gupta Gogia, Department of Respiratory Medicine, Venkateshwar Hospital, Dwarka, New Delhi, India.

Tel. +91 9891170363.

E-mail: pratibha_gupta3@yahoo.com

Key words: paragonimus, lung fluke, zoonosis, Ganges.

Authors' contributions: all the authors made a substantive intellectual contribution. All the authors have read and approved the final version of the manuscript and agreed to be held accountable for all aspects of the work.

Conflict of interest: the authors declare no potential conflict of interest.

Funding: none.

*The publisher is not responsible for the content or functionality of any supporting information supplied by the authors. Any queries should be directed to the corresponding author for the article.
All claims expressed in this article are solely those of the authors and do not necessarily represent those of their affiliated organizations, or those of the publisher, the editors and the reviewers.
Any product that may be evaluated in this article or claim that may be made by its manufacturer is not guaranteed or endorsed by the publisher.*

Availability of data and materials: all data generated or analyzed during this study are included in this published article.

*The publisher is not responsible for the content or functionality of any supporting information supplied by the authors. Any queries should be directed to the corresponding author for the article.
All claims expressed in this article are solely those of the authors and do not necessarily represent those of their affiliated organizations, or those of the publisher, the editors and the reviewers.
Any product that may be evaluated in this article or claim that may be made by its manufacturer is not guaranteed or endorsed by the publisher.*

Abstract

Like many other foodborne parasites, lung fluke (*Paragonimus* species) was considered extinct and is now reemerging, especially in Eastern Asia, Africa, and South America. It commonly affects people consuming crabs and crayfish in their diet. This family of seafood and mollusks is considered an intermediate host for the parasite. Humans and other mammals, such as tigers and pigs incidentally consuming crustaceans, are the definitive hosts. Here, we present a case of pulmonary paragonimiasis in a strict vegetarian who developed the infestation, the possible cause being frequent baths in the holy river Ganges, a common practice amongst Hindus.

Another interesting aspect of this case is that the patient presented with signs and symptoms mimicking tuberculosis, which is also endemic in the region. Presenting symptoms of hemoptysis, generalized malaise, and a normal chest X-ray were misleading, while Flexible Bronchoscopy (FB) with Bronchoalveolar Lavage (BAL) confirmed the diagnosis. The patient made a full recovery with appropriate treatment.

The publisher is not responsible for the content or functionality of any supporting information supplied by the authors. Any queries should be directed to the corresponding author for the article.

All claims expressed in this article are solely those of the authors and do not necessarily represent those of their affiliated organizations, or those of the publisher, the editors and the reviewers.

Any product that may be evaluated in this article or claim that may be made by its manufacturer is not guaranteed or endorsed by the publisher.

Introduction

Paragonimiasis, or the Oriental lung fluke, is a considerable health issue not only in various Asian countries such as China, Japan, Korea, Philippines, and India but also in Africa, South, and North America. It remains under-diagnosed and under-reported mainly due to a lack of suspicion and the unavailability of definitive diagnostic modalities. It is commonly encountered among individuals consuming poorly cooked seafood, especially mollusks and crabs in their diet. We present a case of a strict vegetarian female from Bihar, a state in eastern India, presenting with mild hemoptysis with a habit of taking a dip in the holy river Ganges. She also reported gradually worsening malaise and was initially suspected to have *Mycobacterial Tuberculosis*. A Flexible Bronchoscopy (FB) with Bronchoalveolar Lavage (BAL) provided the diagnosis of pulmonary paragonimiasis. She recovered fully with an appropriate treatment.

Case Report

A 56-year-old female presented with streaky hemoptysis, recurrent low-grade fever, and fatigue of three months duration. She also reported to have lost 12 pounds of weight over the past two months. She gave a history of similar complaints two years earlier, which were managed conservatively by her family physician.

She was married with four children and was a strict vegetarian, with no history of any addictions. Her physical examination was unremarkable; except for pallor. Initial laboratory investigations revealed

The publisher is not responsible for the content or functionality of any supporting information supplied by the authors. Any queries should be directed to the corresponding author for the article.

All claims expressed in this article are solely those of the authors and do not necessarily represent those of their affiliated organizations, or those of the publisher, the editors and the reviewers.

Any product that may be evaluated in this article or claim that may be made by its manufacturer is not guaranteed or endorsed by the publisher.

hemoglobin of 10 gm/dL (normal: 10.8-12.3 g/dL) and peripheral eosinophilia of 8% (normal: less than 5%). Chest X-Ray was interpreted as unremarkable.

As her symptoms failed to improve with a course of antibiotics for presumed “acute bronchitis”, a Computed Tomography (CT) of the chest was obtained. The study revealed ground glass opacities with central cavitation involving the right middle lobe, a superior segment of the right lower lobe as well as a posterior segment of the left lower lobe (Figure 1).

Sputum studies for bacterial, mycobacterial, and fungal filaments were unrevealing. In view of persistent symptoms, an FB was performed. The endobronchial examination was unremarkable, and hence, the bronchoscope was wedged in the right middle lobe medial segment, and a BAL was performed. A trans-bronchial biopsy was performed from the right lower lobe. BAL revealed an eosinophil count of 12% and the cytology was positive for *Paragonimus Cystecercae* (Figure 2). Trans-bronchial lung biopsy showed eggs of *Paragonimus* measuring 80-90 μm x 40-45 μm on hematoxylin and eosin (H&E) stains (Figure 3).

A detailed history was elicited as the patient was a strict vegetarian, making it unexplainable that an infection was transmitted by eating crabs or crayfish. She revealed a history of daily dip in the Ganges as she lived in a city located on the banks of the holy river. She routinely drank the river water during her dip. This river is indeed a rich source of fish for the locals. She probably aspirated water infected with decayed crab or fish directly aspirating the metacerciae, the most plausible reason for the infestation in a staunch vegetarian. Treatment with praziquantel 25mg/kilogram three times a day for three consecutive days was promptly started; the patient made a complete clinical and radiographic recovery.

Discussion

The publisher is not responsible for the content or functionality of any supporting information supplied by the authors. Any queries should be directed to the corresponding author for the article.

All claims expressed in this article are solely those of the authors and do not necessarily represent those of their affiliated organizations, or those of the publisher, the editors and the reviewers.

Any product that may be evaluated in this article or claim that may be made by its manufacturer is not guaranteed or endorsed by the publisher.

Foodborne infestations such as tapeworm and lung flukes were on the decline due to better food preparations and personal hygiene all over the world. In recent years, however, the infestations have shown a reemergence, with 23 million people affected in 48 countries (maximum in China) and 243 million people at risk.^{1,2} A possible reason could be the increasing popularity of partially or uncooked non-vegetarian food choices and the ease and popularity of international travel.¹ Pulmonary paragonimiasis, also referred to as lung fluke, is distinct among foodborne zoonotic trematodes as it has a broad geographical distribution and has over 50 actual or potential causative species. Amongst ten valid pathogenic species, *P. westermani*, *P. heterotremus*, *P. philippinen*, *P. skrjabini*, and *P. miyazakii*, mainly found in Asia, constitute the most important disease-causing variants. The most common species in India is *P. heterotremus*,³ while *P. westermani*, which is the most common in other parts of the world, is seldom encountered.⁴

The first case of lung fluke in India, described in 1982, was from Manipur state, and since then, this northeastern region has been established as its endemic foci. It was recognized as a public health problem in India in 1986, when a total of 39 cases were reported over a short period of time.⁴ The first case ever reported in the world, in 1882, was also indirectly from India, where the fluke affected the lungs of a Bengal tiger in Amsterdam Zoo caught from India.⁵ Wild or domestic mammals such as wild boars, tigers, sheep, and pigs are the common reservoir (Paratenic host) for this parasite, and it often exists in them along with humans as a definitive host. It is usually acquired by eating freshwater crustaceans containing metacercaria but can also arise following ingestion of uncooked meat of mammalian paratenic hosts.⁶ Metacercaria in undercooked crabs or fishes (infective form) enter the human intestine, penetrate its walls and diaphragm, and reach pleural space around the lungs. A single adult stays in the pleural space until it finds another worm, then enters the lung tissues and forms a

The publisher is not responsible for the content or functionality of any supporting information supplied by the authors. Any queries should be directed to the corresponding author for the article.

All claims expressed in this article are solely those of the authors and do not necessarily represent those of their affiliated organizations, or those of the publisher, the editors and the reviewers.

Any product that may be evaluated in this article or claim that may be made by its manufacturer is not guaranteed or endorsed by the publisher.

capsule in which the pair resides; the eggs so formed are shed in sputum as well as stool. Eggs reach the mollusk stage and are then eaten by crabs/crayfishes to be further consumed by mammals, and the cycle repeats.

Common signs of the infestation are fever, hemoptysis, productive cough, weight loss, and radiological opacities mimicking tuberculosis, pneumonia, COVID-19 pneumonia, or lung cancer.⁷ It mainly affects the lungs but has also been reported in skin nodules, breast, intestinal wall, peritoneal cavity, liver, lymph nodes, brain, and genitourinary tract.⁸

An advanced Pubmed search with lung fluke and vegetarian as search words did not discover any result, making this case a possible first such case, all reported cases being in non-vegetarians. Our patient was a strict vegetarian, and the only possibility of ingesting metacercaria was by swallowing Ganges water while taking a dip, making it worth reporting. The holy river could be infected by the washing of infected utensils or by decayed crabs releasing metacercaria.

Radiologically, it is common to miss the diagnosis unless a parasite or migration track is detected. In a study by Sah *et al.* various CT findings reported were nodules, ground glass opacities, worm cysts, migration track, fibrosis, pleural effusion, pleural thickening, pleural calcification, and mediastinal lymphadenopathy.^{5,9}

Diagnosing lung fluke is challenging due to its rarity. Once suspected, it can be diagnosed by sputum smear examination, serological testing, bronchoscopy, BAL, and/or lung biopsy. Image-guided biopsies from other sites¹⁰ should also be considered based on the presentation. This case establishes the benefit of knowledge of segmental anatomy, BAL, and Transbronchial Biopsy (TBBx) in diagnosing a treatable cause. This being a neglected entity and the poor accessibility of serologic testing and molecular workup

The publisher is not responsible for the content or functionality of any supporting information supplied by the authors. Any queries should be directed to the corresponding author for the article.

All claims expressed in this article are solely those of the authors and do not necessarily represent those of their affiliated organizations, or those of the publisher, the editors and the reviewers.

Any product that may be evaluated in this article or claim that may be made by its manufacturer is not guaranteed or endorsed by the publisher.

(for species identification) makes the diagnosis more challenging.¹¹ A study from China reported that delayed diagnosis of (>25 weeks) in paragonimiasis cases between 1982 and 2003 was mainly due to misdiagnosis as tuberculosis, malignancy, or Chronic Obstructive Pulmonary Disease (COPD).¹² Mortality is low, but morbidity due to fever, hemoptysis, malaise, and extrapulmonary symptoms such as subcutaneous nodules, diarrhea, and seizure can be high.¹⁴

Finding eggs in sputum or faces is the 'gold standard' for the diagnosis. However, caution is needed in identifying fecal eggs as several unrelated intestinal trematodes produce similar eggs. Sputum examination also has its limitations, as eggs appear intermittently in pulmonary paragonimiasis and never in extra-pulmonary cases.¹³

Conclusions

This case highlights the fact that lung fluke can also be encountered in a vegetarian patient. The source of infection could be contaminated water or even a "holy" river. The disease is truly not extinct, and the incidences may be on the rise due to the fancy of eating raw seafood. The presentation mimics more common conditions such as tuberculosis; thus, a high degree of suspicion is required to establish the diagnosis. A BAL and a TBBx could establish the diagnosis.

The publisher is not responsible for the content or functionality of any supporting information supplied by the authors. Any queries should be directed to the corresponding author for the article.

All claims expressed in this article are solely those of the authors and do not necessarily represent those of their affiliated organizations, or those of the publisher, the editors and the reviewers.

Any product that may be evaluated in this article or claim that may be made by its manufacturer is not guaranteed or endorsed by the publisher.

References

1. Chai JY, Jung BK. General overview of the current status of human foodborne trematodiasis. *Parasitology* 2022;149:1262-85.
2. World Health Organization (WHO). Ending the neglect to attain the sustainable development goals: a road map for neglected tropical diseases 2021–2030. 2020. Available from: <https://www.who.int/publications/i/item/9789240010352>
3. Blair D. Lung flukes of the genus *Paragonimus*: ancient and re-emerging pathogens. *Parasitology* 2022;149:12
4. Singh TS, Sugiyama H, Rangsiruji A. *Paragonimus* and paragonimiasis in India. *Indian J Med Res* 2012;136:192-204.
5. Sah SK, Du S, Liu Y, et al. Imaging findings of *Paragonimus westermani*. *Radiology of Infectious Diseases* 2016;3:66-73.
6. Ruan Y, Tian T, Zhu ZL, et al. Assessing competence for helminthiasis: a lesson learnt from national contest of parasitic diseases in China in 2012–2016. *Acta Tropica* 2019;198:105078.
7. Diaz JH. Paragonimiasis acquired in the United States: native and nonnative species. *Clinical Microbiology Reviews* 2013;26:493-504.
8. Singh T, Hiromu S, Devi K, Singh W. First case of *Paragonimus westermani* infection in a female patient in India. *Indian Journal of Medical Microbiology* 2015;33:156.

9. Singh TS, Mutum SS, Razaque MA. Pulmonary paragonimiasis: clinical features, diagnosis and treatment of 39 cases in Manipur. *Trans R Soc Trop Med Hyg* 1986;80:967-71.
10. Blair D, Xu ZB, Agatsuma T. Paragonimiasis and the genus *Paragonimus*. *Advances in Parasitology* 1999;42:113-222.
11. Khemasuwan D, Farver C, Mehta AC. Parasitic diseases of the lung. *Diseases of the Central Airways* 2016:231-53.
12. Ahn CS, Shin JW, Kim JG, et al. Spectrum of pleuropulmonary paragonimiasis: an analysis of 685 cases diagnosed over 22 years. *Journal of Infection* 2021;82:150-8.
13. Feng Y, Fürst T, Liu L, Yang GJ. Estimation of disability weight for paragonimiasis: a systematic analysis. *Infectious Diseases Of Poverty* 2018;7:1-9.

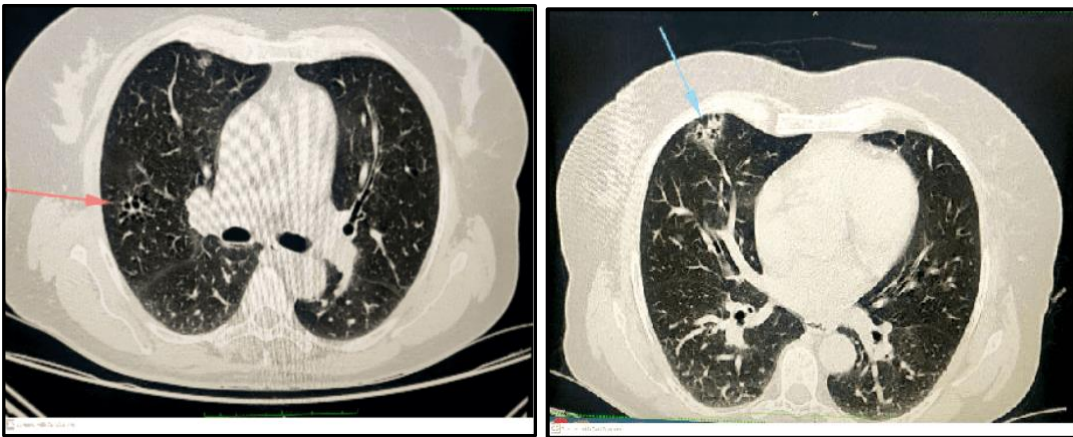


Figure 1. Ground glass opacity with consolidation in the middle lobe.

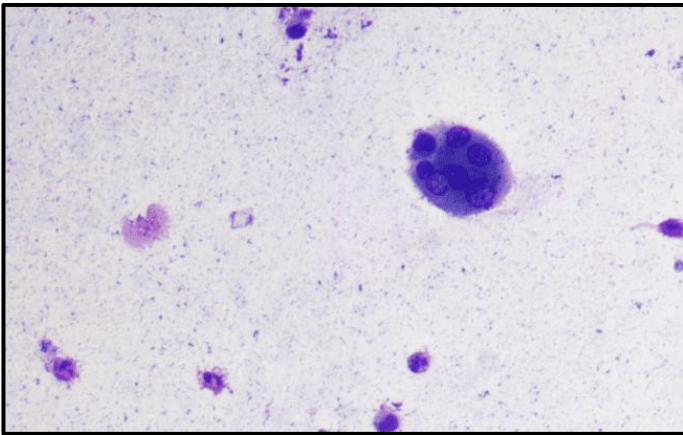


Figure 2. Bronchoalveolar Lavage (BAL) showing Pargonimus Cystecercae. Magnification: 40X.

*The publisher is not responsible for the content or functionality of any supporting information supplied by the authors. Any queries should be directed to the corresponding author for the article.
All claims expressed in this article are solely those of the authors and do not necessarily represent those of their affiliated organizations, or those of the publisher, the editors and the reviewers.
Any product that may be evaluated in this article or claim that may be made by its manufacturer is not guaranteed or endorsed by the publisher.*

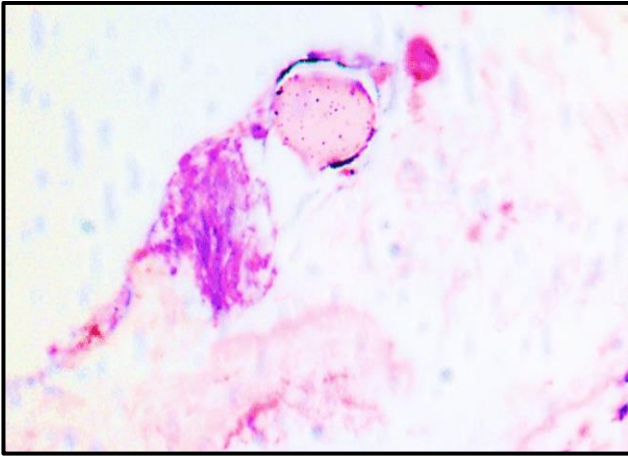


Figure 3. Transbronchial Lung Biopsy (TBBx) showing Paragonimus eggs (hematoxylin and eosin stain). Magnification: 40X.