



eISSN 2039-4772

<https://www.pagepressjournals.org/index.php/chest/index>

**Publisher's disclaimer.** E-publishing ahead of print is increasingly important for the rapid dissemination of science. The **Early Access** service lets users access peer-reviewed articles well before print / regular issue publication, significantly reducing the time it takes for critical findings to reach the research community.

These articles are searchable and citable by their DOI (Digital Object Identifier).

**Chest Disease Reports** is, therefore, e-publishing PDF files of an early version of manuscripts that have undergone a regular peer review and have been accepted for publication, but have not been through the typesetting, pagination and proofreading processes, which may lead to differences between this version and the final one. The final version of the manuscript will then appear in a regular issue of the journal.

E-publishing of this PDF file has been approved by the authors.

*All legal disclaimers applicable to the journal apply to this production process as well.*

Chest Disease Reports 2024 [online ahead of print]

To cite this article:

*The publisher is not responsible for the content or functionality of any supporting information supplied by the authors. Any queries should be directed to the corresponding author for the article.*

*All claims expressed in this article are solely those of the authors and do not necessarily represent those of their affiliated organizations, or those of the publisher, the editors and the reviewers. Any product that may be evaluated in this article or claim that may be made by its manufacturer is not guaranteed or endorsed by the publisher.*

Anh Huynh-My, Bao Le-Khac, Nam Vu-Hoai, Lam Nguyen-Ho. Radiological distribution of bronchiectasis could be a clue for an infrequent cause of chronic cough. *Chest Disease Reports*. 2024;12:11980.

doi:10.4081/cdr.2024.11980



©The Author(s), 2024

Licensee *PAGEPress*, Italy

*The publisher is not responsible for the content or functionality of any supporting information supplied by the authors. Any queries should be directed to the corresponding author for the article.*

*All claims expressed in this article are solely those of the authors and do not necessarily represent those of their affiliated organizations, or those of the publisher, the editors and the reviewers. Any product that may be evaluated in this article or claim that may be made by its manufacturer is not guaranteed or endorsed by the publisher.*

## Radiological distribution of bronchiectasis could be a clue for an infrequent cause of chronic cough

Anh Huynh-My<sup>1</sup>, Bao Le-Khac<sup>1</sup>, Nam Vu-Hoai<sup>2</sup>, Lam Nguyen-Ho<sup>1,2,3</sup>

<sup>1</sup>Department of Internal Medicine, University of Medicine and Pharmacy, Ho Chi Minh City;

<sup>2</sup>Respiratory Department, Cho Ray's Hospital;

<sup>3</sup>Department of Respiratory Functional Exploration, University Medical Center, Ho Chi Minh City, Vietnam;

**Corresponding author:** Lam Nguyen-Ho, University of Medicine and Pharmacy, 217 Hong Bang, ward 11, district 5, Ho Chi Minh City, Vietnam.

E-mail: [bsholam1986@gmail.com](mailto:bsholam1986@gmail.com) ; [nguyenholam@ump.edu.vn](mailto:nguyenholam@ump.edu.vn)

**Key words:** bronchoscopy, chronic cough, elderly, foreign body aspiration.

**Authors' contributions:** conceptualization, AHM, LNH; resources, BLK, NVH; writing-original draft, AHM LNH; writing-review and editing, BLK, NVH; supervision, BLK, NVH.

All the authors have read and approved the final version of the manuscript and agreed to be held accountable for all aspects of the work.

*The publisher is not responsible for the content or functionality of any supporting information supplied by the authors. Any queries should be directed to the corresponding author for the article.*

*All claims expressed in this article are solely those of the authors and do not necessarily represent those of their affiliated organizations, or those of the publisher, the editors and the reviewers. Any product that may be evaluated in this article or claim that may be made by its manufacturer is not guaranteed or endorsed by the publisher.*

**Conflict of interest:** the authors declare no potential conflict of interest.

**Funding:** none.

**Ethics approval and consent to participate:** appropriate written informed consent was obtained for publication of this case report and accompanying images.

**Availability of data and materials:** all data generated or analyzed during this study are included in this published article.

*The publisher is not responsible for the content or functionality of any supporting information supplied by the authors. Any queries should be directed to the corresponding author for the article.*

*All claims expressed in this article are solely those of the authors and do not necessarily represent those of their affiliated organizations, or those of the publisher, the editors and the reviewers. Any product that may be evaluated in this article or claim that may be made by its manufacturer is not guaranteed or endorsed by the publisher.*

## **Abstract**

Foreign Body Aspiration (FBA) in the elderly is an uncommon but potentially life-threatening condition in the acute setting, but it can also persist in the clinical setting of neglected foreign body with chronic and subtle respiratory symptoms. Chest computed tomography scan can overlook radiolucent foreign bodies but prominently focal lesion and bibasilar bronchiectasis in the appropriate clinical setting should increase the suspicion of FBA. Here we reported a 75-year-old female patient with chronic cough induced by neglected airway foreign body. Bronchoscopic removal of the foreign body was performed successfully, and her cough improved enormously after that.

*The publisher is not responsible for the content or functionality of any supporting information supplied by the authors. Any queries should be directed to the corresponding author for the article.*

*All claims expressed in this article are solely those of the authors and do not necessarily represent those of their affiliated organizations, or those of the publisher, the editors and the reviewers. Any product that may be evaluated in this article or claim that may be made by its manufacturer is not guaranteed or endorsed by the publisher.*

## Introduction

Foreign Body Aspiration (FBA) is one of the leading causes of life-threatening accidents at home and community. Although, the majority of FBA cases are primarily recorded in children, however it is still noted in adults, especially subjects with dysphagia. Risk factors in adults include age  $\geq 75$ ,<sup>1</sup> loss of consciousness due to trauma, alcohol abuse, disease or narcotic use.<sup>2</sup> Elderly patients have high risk of FBA because of age-related poor performance of swallowing, medication use (which reduces coughing and swallowing reflex), disease-related dysphagia (stroke and degenerative neurological diseases).<sup>2,3</sup> Out of the choking attack of aspiration, patients with FBA can present symptoms similar to those of chronic lung diseases (chronic obstructive pulmonary disease, asthma, and obstructive pneumonia)<sup>4,5</sup> due to its complications such as recurrent pneumonia, bronchiectasis, recurrent hemoptysis, pneumothorax, lung abscess, and pneumomediastinum.<sup>6</sup> Removal of foreign bodies should be performed as soon as possible because of its acute and long-term complications.<sup>6</sup> We report a case of chronic cough in an elderly patient whose final etiology was associated with a neglected airway foreign body.

## Case Report

A 75-year-old female patient presented at the respiratory outpatient clinic with a one-year history of dry cough. Her past medical history was hypertension which was treated with an angiotensin-converting enzyme inhibitor (a possible cause of chronic cough but it had been used for more than 10 years without previous cough). No symptoms relating to allergic rhinitis

*The publisher is not responsible for the content or functionality of any supporting information supplied by the authors. Any queries should be directed to the corresponding author for the article.*

*All claims expressed in this article are solely those of the authors and do not necessarily represent those of their affiliated organizations, or those of the publisher, the editors and the reviewers. Any product that may be evaluated in this article or claim that may be made by its manufacturer is not guaranteed or endorsed by the publisher.*

and asthma were documented. On physical examination, blood pressure 145/85 mmHg, pulse 87/minute, respiratory rate 18/minute, and Pulse Oximetry (SpO<sub>2</sub>) 99% with ambient air.

Lung auscultation showed bibasilar crackles scattered.

The patient had visited other hospitals previously with the normal result of Chest X-Ray (CXR), but her cough did not improve. Chest Computed Tomography (CT) scan undertaken revealed bibasilar bronchiectasis, prominently localized infiltration and fibrosis at the right lower lobe, and no foreign body (Figure 1). Suspecting micro-aspiration as an etiology of bibasilar bronchiectasis, patient's medical history was asked carefully to unravel the suitable symptoms and a potential attack of FBA before the occurring of cough. Therefore, bronchoscopy undertaken revealed the foreign body at the segmental bronchus of the right lower lobe. Bronchoscopic removal was performed successfully to show little cloudy pus under foreign body and its nature could be the head of a chili (Figure 2).

The Bronchial Lavage Fluid (BLF) cytology revealed neutrophil 62% and lymphocyte 38% and the microbiological tests of BLF (acid-fast bacillus smear, gene-Xpert, and mycobacteria growth indicator tube culture) were negative. She completed a 2-week course of antibiotics with amoxicillin/clavulanic acid 875 mg/125 mg oral twice daily and moxifloxacin 400 mg oral once daily. The results of treatment showed that cough symptoms improved significantly (stop coughing almost completely).

## **Discussion**

*The publisher is not responsible for the content or functionality of any supporting information supplied by the authors. Any queries should be directed to the corresponding author for the article.*

*All claims expressed in this article are solely those of the authors and do not necessarily represent those of their affiliated organizations, or those of the publisher, the editors and the reviewers. Any product that may be evaluated in this article or claim that may be made by its manufacturer is not guaranteed or endorsed by the publisher.*

The prevalence of chronic cough (duration >8 weeks) in adults is estimated to 10% with common causes in the setting of normal CXR including postnasal drip syndrome, cough-variant asthma, gastroesophageal reflux disease, eosinophilic bronchitis, or drug-induced cough.<sup>7</sup> However, when these causes are excluded, less common causes include bronchiectasis, lymphoma, persistent pneumonia, sarcoidosis, endobronchial tuberculosis, and FBA should be considered. In particular, chronic cough in patients with non-responsive pneumonia, the obstructive cause by tumor or foreign body should be concerned.<sup>8</sup>

FBA occurs more commonly in children, especially 75% of cases under 3 years.<sup>9,10</sup> It is also reported with the frequency of 1 in 400 bronchoscopy cases in adults.<sup>11</sup> The average age of aspirated adults is between 50 and 60 years old, and the risk of FBA seems to increase with age.<sup>2,4,5</sup> The chronic cough among elderly patients may be more complex because of changes in the cough reflex.<sup>12</sup> Due to the aging population increasing, pulmonologists and geriatricians have realized that micro-aspiration or even FBA may be important pathogenesis of aspiration pneumonia in this group.<sup>4,5,13,14</sup>

Cough is a common symptom of FBA, occurring in 58–96% of patients,<sup>4,15-17</sup> along with other symptoms such as wheezing, shortness of breath, hemoptysis, and chest pain all which were influenced by the foreign body size and its obstructive location. Asymptomatic FBA patients accounted for 2-10% were identified incidentally on radiology and bronchoscopy.<sup>4,15,18</sup> Large foreign bodies obstructing the main airway (pharynx and trachea) are more likely to cause acute asphyxia with supraglottic location in one-third cases.<sup>19</sup> More commonly, however, foreign bodies migrate into the lower lobes of the lung, especially the intermediate bronchus or

*The publisher is not responsible for the content or functionality of any supporting information supplied by the authors. Any queries should be directed to the corresponding author for the article.*

*All claims expressed in this article are solely those of the authors and do not necessarily represent those of their affiliated organizations, or those of the publisher, the editors and the reviewers. Any product that may be evaluated in this article or claim that may be made by its manufacturer is not guaranteed or endorsed by the publisher.*



branches of the right lower lobe bronchus similar to our case. The more vertical angle and larger diameter of the right main bronchus compared to the left could be underlying mechanism to explain.<sup>20</sup> Surprisingly, in adults, about 40% of FBA is found in the left airway opposite to only 5–11% of cases in the right bronchus.<sup>5,18,21-23</sup>

In children, foreign bodies such as nuts, seeds, and other organic matters are common. However, in adults, the nature of inhaled foreign bodies is diverse, ranging from organic to inorganic. Inorganic foreign body, such as nails (hands, feet), or needles occur mainly in young or middle-aged people during "do-it-yourself" activities, or in those with mental illness.<sup>24</sup>

Organic foreign body - food - is the most commonly reported inhaled foreign body due to poor chewing or swallowing function. The type of inhaled food varies according to local culture or ethnicity.<sup>25</sup> For example, in people in the West, China and the Middle East, FBA related to plant matter, bones and watermelon seeds are the most inhaled foods, respectively.<sup>15,26,27</sup>

In clinical practice, standard posterior-anterior and lateral CXR should be obtained in all suspected patients, even chest CT scan. Most foreign bodies are radiolucent and not easily identifiable on CXR.<sup>28,29</sup> In our case, as an example, even the result of chest CT scan was still inconclusive about the presence of a foreign body. Because of the silent and subtle presentation of FBA in the elderly, the imaging in most cases depicts the consequences of long-neglected FBA, including post-obstructive pneumonia, atelectasis, and rarely, emphysema, pneumothorax, unilateral pulmonary distension or focal bronchiectasis.<sup>23,28,30</sup> Our case showed prominent focal signs of pneumonia and bronchiectasis in the right lower lobe which was a suspicious clue for FBA.

*The publisher is not responsible for the content or functionality of any supporting information supplied by the authors. Any queries should be directed to the corresponding author for the article.*

*All claims expressed in this article are solely those of the authors and do not necessarily represent those of their affiliated organizations, or those of the publisher, the editors and the reviewers. Any product that may be evaluated in this article or claim that may be made by its manufacturer is not guaranteed or endorsed by the publisher.*

Given its wide availability, flexible bronchoscopy is often indicated for non-life-threatening FBA in adults, especially those with small foreign bodies in the lower airways or even the missed foreign body with chest CT imaging. Flexible bronchoscopy can provide information regarding the accurate location of foreign bodies, facilitate the selection of necessary instruments as well as conduct removal of foreign bodies.<sup>31</sup> With high clinical suspicion and localized imaging features, bronchoscopy was performed and the foreign body was removed successfully in our case. The foreign body is most likely a chili head. The nature of foreign body is a cough stimulant (capsaicin is a commonly extracted ingredient, used for the cough stimulation test in most studies). So cough in this case may be due to a combination of irritation from the foreign body as well as caused by the consequence of its obstruction.

## **Conclusions**

FBA in the elderly can encounter in clinical practice. In most cases, the clinical presentation of FBA in the elderly is persistent or insidious, possibly due to foreign bodies located in the distal bronchi. Cough is a common symptom, followed by symptoms associated with complications of FBA. Therefore, clinicians must always be vigilant about FBA when approaching the diagnosis of chronic cough, especially in situations of persistent cough that are poorly responsive to conventional therapies and in high-risk populations, includes people  $\geq 75$  years of age, neurological disorders, loss of consciousness and use of alcohol or sedatives. Chest CT scan can overlook radiolucent foreign bodies but prominently focal lesion and bibasilar bronchiectasis in the appropriate clinical setting should increase the suspicion of FBA.

*The publisher is not responsible for the content or functionality of any supporting information supplied by the authors. Any queries should be directed to the corresponding author for the article.*

*All claims expressed in this article are solely those of the authors and do not necessarily represent those of their affiliated organizations, or those of the publisher, the editors and the reviewers. Any product that may be evaluated in this article or claim that may be made by its manufacturer is not guaranteed or endorsed by the publisher.*

Bronchoscopy is still considered the gold standard in the diagnosis and treatment of FBA until now.

*The publisher is not responsible for the content or functionality of any supporting information supplied by the authors. Any queries should be directed to the corresponding author for the article.*

*All claims expressed in this article are solely those of the authors and do not necessarily represent those of their affiliated organizations, or those of the publisher, the editors and the reviewers. Any product that may be evaluated in this article or claim that may be made by its manufacturer is not guaranteed or endorsed by the publisher.*

## References

1. Rafanan AL, Mehta AC. Adult airway foreign body removal. What's new? Clinics in Chest Medicine. 2001;22:319-30.
2. Boyd M, Chatterjee A, Chiles C, Chin R. Tracheobronchial Foreign Body Aspiration in Adults. Southern Medical Journal. 2009;102:171-4.
3. Nguyen-Ho L. Expulsion of inhaled foreign body and risk of endotracheal tube block. Int J Fam Commun Med. 2018;2:19-20.
4. Boyd M, Watkins F, Singh S, et al. Prevalence of flexible bronchoscopic removal of foreign bodies in the advanced elderly. Age and Ageing. 2009;38:396-400.
5. Lin L, Lv L, Wang Y, et al. The clinical features of foreign body aspiration into the lower airway in geriatric patients. Clinical Interventions in Aging. 2014;9:1613-8.
6. Al-Majed SA, Ashour M, Al-Mobeireek AF, et al. Overlooked inhaled foreign bodies: late sequelae and the likelihood of recovery. Respiratory Medicine. 1997;91:293-6.
7. Irwin RS, French CL, Chang AB, Altman KW. Classification of Cough as a Symptom in Adults and Management Algorithms: CHEST Guideline and Expert Panel Report. Chest. 2018;153:196-209.
8. Bartlett JG, Dowell SF, Mandell LA, et al. Practice guidelines for the management of community-acquired pneumonia in adults. Infectious Diseases Society of America. Clinical infectious diseases : an official publication of the Infectious Diseases Society of America. 2000;31:347-82.

*The publisher is not responsible for the content or functionality of any supporting information supplied by the authors. Any queries should be directed to the corresponding author for the article.*

*All claims expressed in this article are solely those of the authors and do not necessarily represent those of their affiliated organizations, or those of the publisher, the editors and the reviewers. Any product that may be evaluated in this article or claim that may be made by its manufacturer is not guaranteed or endorsed by the publisher.*

9. Hsu W, Sheen T, Lin C, et al. Clinical experiences of removing foreign bodies in the airway and esophagus with a rigid endoscope: a series of 3217 cases from 1970 to 1996. *Otolaryngology--head and neck surgery : official journal of American Academy of Otolaryngology-Head and Neck Surgery*. 2000;122:450-4.
10. Baharloo F, Veyckemans F, Francis C, et al. Tracheobronchial foreign bodies: presentation and management in children and adults. *Chest*. 1999;115:1357-62.
11. Hewlett JC, Rickman OB, Lentz RJ, et al. Foreign body aspiration in adult airways: therapeutic approach. *Journal of Thoracic Disease*. 2017;9:3398-409.
12. Teramoto S, Matsuse T, Ouchi Y. Clinical significance of cough as a defense mechanism or a symptom in elderly patients with aspiration and diffuse aspiration bronchiolitis. *Chest*. 1999;115:602-3.
13. Teramoto S, Yamamoto H, Yamaguchi Y, et al. A novel diagnostic test for the risk of aspiration pneumonia in the elderly. *Chest*. 2004;125:801-2.
14. Vincent J-L. Nosocomial infections in adult intensive-care units. *The Lancet*. 2003;361:2068-77.
15. Limper AH, Prakash UB, Jain A. Tracheobronchial foreign bodies in adults. *Annals of Internal Medicine*. 1990;112:604-9.
16. Chen CH, Lai CL, Tsai TT, et al. Foreign body aspiration into the lower airway in Chinese adults. *Chest*. 1997;112:129-33.

*The publisher is not responsible for the content or functionality of any supporting information supplied by the authors. Any queries should be directed to the corresponding author for the article.*

*All claims expressed in this article are solely those of the authors and do not necessarily represent those of their affiliated organizations, or those of the publisher, the editors and the reviewers. Any product that may be evaluated in this article or claim that may be made by its manufacturer is not guaranteed or endorsed by the publisher.*

17. Mise K, Jurcev Savicevic A, Pavlov N, Jankovic SJSe. Removal of tracheobronchial foreign bodies in adults using flexible bronchoscopy: experience 1995–2006. *Surgical Endoscopy*. 2009;23:1360-4.
18. Dong YC, Zhou GW, Bai C, et al. Removal of tracheobronchial foreign bodies in adults using a flexible bronchoscope: experience with 200 cases in China. *Internal Medicine (Tokyo, Japan)*. 2012;51:2515-9.
19. Mittleman RE, Wetli CVJJ. The fatal cafe coronary: foreign-body airway obstruction. *JAMA*. 1982;247:1285-8.
20. Mehta A, Rafanan A. Extraction of Airway Foreign Body in Adults. *Journal of Bronchology & Interventional Pulmonology*. 2001;8:123-31.
21. Swanson KL, Prakash UB, McDougall JC, et al. Airway foreign bodies in adults. *Journal of Bronchology & Interventional Pulmonology*. 2003;10:107-11.
22. Debeljak A, Sorli J, Music E, Kecelj P. Bronchoscopic removal of foreign bodies in adults: experience with 62 patients from 1974-1998. *The European Respiratory Journal*. 1999;14:792-5.
23. Blanco Ramos M, Botana-Rial M, García-Fontán E, et al. Update in the extraction of airway foreign bodies in adults. *Journal of Thoracic Disease*. 2016;8:3452-6.
24. Medidi S, Fountain A, Radwan M, Rumbak M. "Fishing in the trachea": a unique case of foreign body aspiration. *J Bronchology Interv Pulmonol*. 2012;19:168-70.
25. Chooromi S, Curotta J. Foreign body aspiration and language spoken at home: 10-year review. *The Journal of Laryngology and Otology*. 2011;125:719-23.

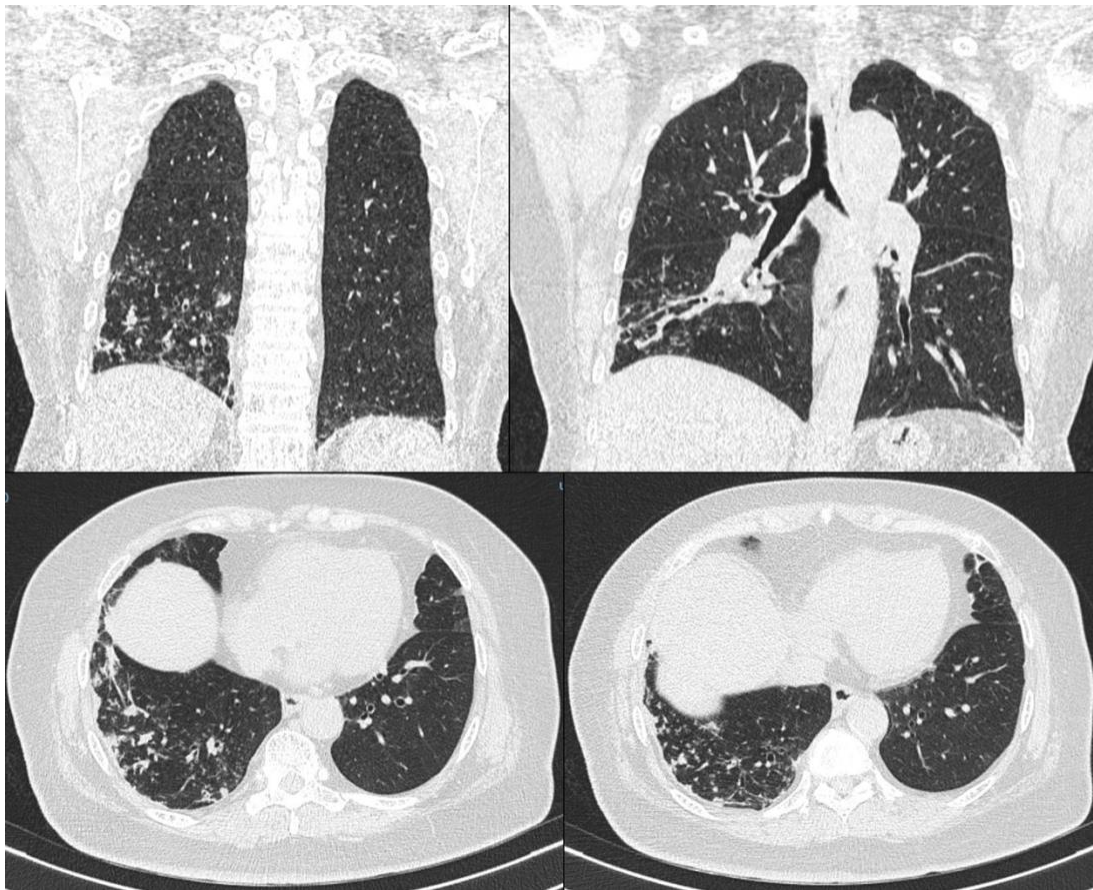
*The publisher is not responsible for the content or functionality of any supporting information supplied by the authors. Any queries should be directed to the corresponding author for the article.*

*All claims expressed in this article are solely those of the authors and do not necessarily represent those of their affiliated organizations, or those of the publisher, the editors and the reviewers. Any product that may be evaluated in this article or claim that may be made by its manufacturer is not guaranteed or endorsed by the publisher.*

26. Lan RJERJ. Non-asphyxiating tracheobronchial foreign bodies in adults. *European Respiratory Journal*. 1994;7:510-4.
27. Elhassani NB. Tracheobronchial foreign bodies in the Middle East: A Baghdad study. *The Journal of Thoracic and Cardiovascular Surgery*. 1988;96:621-5.
28. Ramos MB, Fernández-Villar A, Rivo JE, Leiro V, García-Fontán E, Botana MI, et al. Extraction of airway foreign bodies in adults: experience from 1987-2008. *Interactive Cardiovascular And Thoracic Surgery*. 2009;9:402-5.
29. Sersar SI, Rizk WH, Bilal M, et al. Inhaled foreign bodies: presentation, management and value of history and plain chest radiography in delayed presentation. *Otolaryngology - Head and Neck Surgery : official journal of American Academy of Otolaryngology. Head and Neck Surgery*. 2006;134:92-9.
30. Pinto A, Scaglione M, Pinto F, et al. Tracheobronchial aspiration of foreign bodies: current indications for emergency plain chest radiography. *La Radiologia Medica*. 2006;111:497-506.
31. Couper K, Abu Hassan A, Ohri V, et al. Removal of foreign body airway obstruction: A systematic review of interventions. *Resuscitation*. 2020;156:174-81.

*The publisher is not responsible for the content or functionality of any supporting information supplied by the authors. Any queries should be directed to the corresponding author for the article.*

*All claims expressed in this article are solely those of the authors and do not necessarily represent those of their affiliated organizations, or those of the publisher, the editors and the reviewers. Any product that may be evaluated in this article or claim that may be made by its manufacturer is not guaranteed or endorsed by the publisher.*

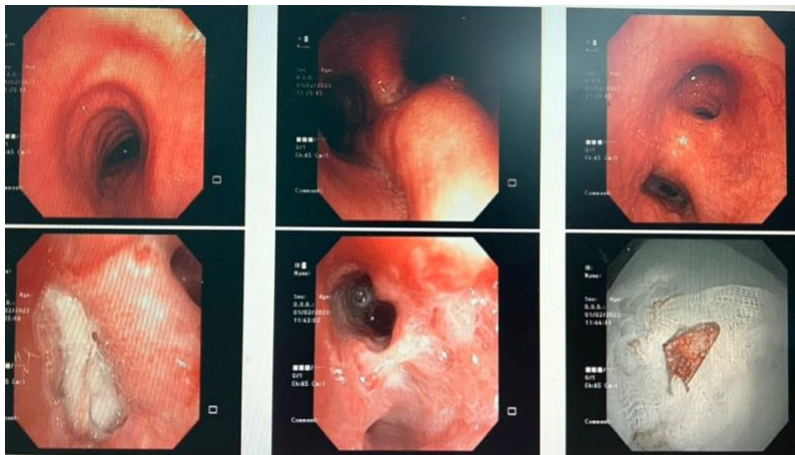


**Figure 1.** Chest Computed Tomography (CT) shows bibasilar tubular bronchiectasis, bibasilar fibrous lesions diffuse and at the right lower lobe prominent with bronchial wall thickening, fluid retention in some bronchial branches.

*The publisher is not responsible for the content or functionality of any supporting information supplied by the authors. Any queries should be directed to the corresponding author for the article.*

*All claims expressed in this article are solely those of the authors and do not necessarily represent those of their affiliated organizations, or those of the publisher, the editors and the reviewers. Any product that may be evaluated in this article or claim that may be made by its manufacturer is not guaranteed or endorsed by the publisher.*





**Figure 2.** Flexible bronchoscopy showed the foreign body, the possible head of chili pepper, removed successfully.

*The publisher is not responsible for the content or functionality of any supporting information supplied by the authors. Any queries should be directed to the corresponding author for the article.*

*All claims expressed in this article are solely those of the authors and do not necessarily represent those of their affiliated organizations, or those of the publisher, the editors and the reviewers. Any product that may be evaluated in this article or claim that may be made by its manufacturer is not guaranteed or endorsed by the publisher.*