

## Dental Implants in Sjögren Syndrome

Hamidreza Daneshparvar (1), Nasrin Esfahanizadeh (2), Reza Vafadoost (2)

(1) *Legal Medicine Research Center, Legal Medicine Organization, Tehran, Iran.* (2) *Department of Periodontology, Faculty of Dentistry, Tehran Medical Sciences, Islamic Azad University, Tehran, Iran.*

*This article is distributed under the terms of the Creative Commons Attribution Noncommercial License (CC BY-NC 4.0) which permits any noncommercial use, distribution, and reproduction in any medium, provided the original author(s) and source are credited.*

### Abstract

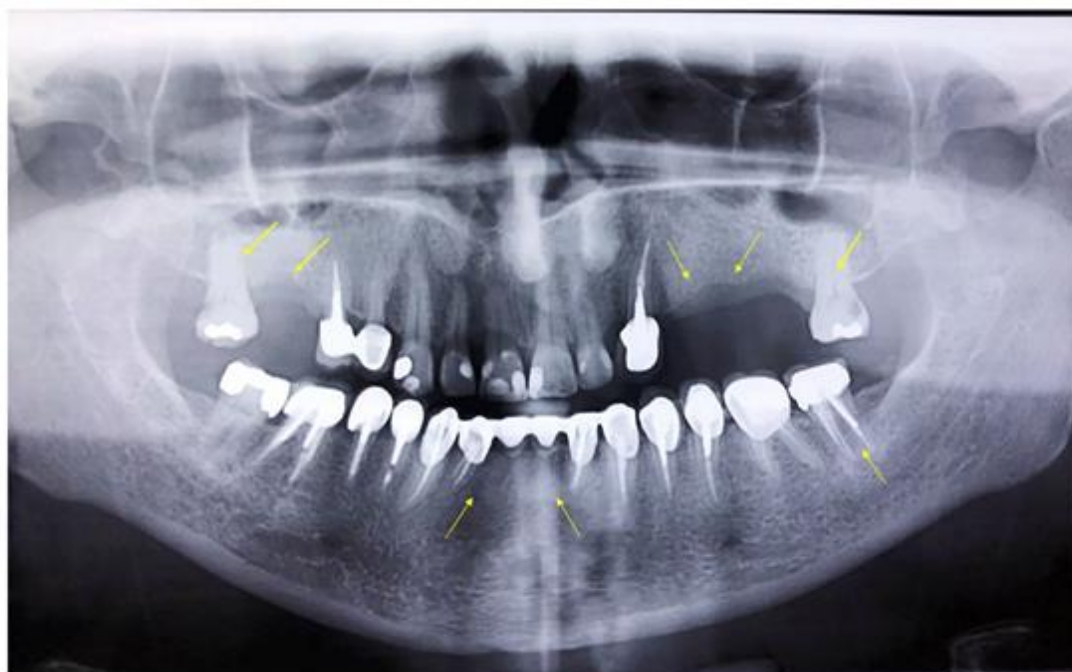
Sjögren's syndrome (SS) is a complex autoimmune disease that predominantly affects the exocrine glands, notably the salivary and lacrimal glands, resulting in dryness of the mucosa recognized as xerostomia. Chief oral complications reported by patients consist of high caries rate, burning sensation of the mucosa, early tooth loss, intensified tooth wear and repetitive failure of dental restorations. In particular, due to the decreased salivary flow, conventional removable prostheses might irritate the mucosa and lead to painful ulcerations at the borders of the denture. Implant-supported prostheses offer a unique solution to the difficulties experienced by edentulous patients with Sjögren's syndrome. This research showed no signs of peri-implantitis or peri-implant mucositis during 7-years following the placement of implants. The present study indicates that successful long-term maintenance of dental implants can be also achieved in SS patients.

**Key Words:** : Implant treatment; dental implants; Sjögren's syndrome; dental restoration failure; xerostomia; survival rate

*Eur J Transl Myol 30 (2): 334-340, 2020*

Sjögren's syndrome (SS) is a systemic autoimmune disease characterized by lymphocytic infiltration of exocrine glands, with salivary and lacrimal glands being the most commonly involved sites.<sup>1</sup> SS is diagnosed more frequently in women with 9:1 female/male ratio and has two points of incidence around 30-40 and 50-60 years of age,<sup>2,3</sup> and is categorized into primary or secondary SS caused by systemic diseases such as rheumatoid arthritis (RA), systemic lupus erythematosus (SLE), systemic sclerosis (SSc) and, autoimmune liver or thyroid diseases.<sup>4</sup> Progressive immune-mediated destruction of the disease affects several organs of the body including articular joints, central nervous system, lungs, and skin.<sup>5</sup> Main oral complications reported by patients consist of high caries rate, burning sensation of the mucosa, early tooth loss, increased tooth wear and recurring failure of dental restorations.<sup>6,7</sup> A considerable number of patients with SS complain of systemic dryness involving the mucosa of the mouth, the nose, the vagina, and the skin,<sup>8</sup> with the most common clinical manifestations include oral and eye dryness that is regularly present at the time of diagnosis.<sup>9</sup> Particularly in the mouth cavity, SS decreases saliva production and modifies the protein profile and the composition of saliva.<sup>10</sup> Saliva protects the soft tissues from dehydration, penetration, or

ulceration and stimulates tissue repair by decreasing clotting time and accelerating wound contraction.<sup>11,12</sup> Also, saliva, owing to its high mineral content, maintains oral homeostasis and stimulates the remineralization of teeth.<sup>13</sup> In SS, because of the disruption of this equilibrium, patients are at an increased risk of dental caries and tooth loss.<sup>14</sup> Therefore, patients with SS often require dentures early in their lives. However, these patients are challenged with numerous difficulties while wearing removable dentures since xerostomia (mucosal dryness) increases the risk of developing painful ulcerations in denture-bearing tissues, diminishes the retention of dentures, and other complications, such as local candida infections.<sup>10</sup> Implant-supported prostheses may propose a solution to resolve some of these prosthodontic complications in patients with SS.<sup>10</sup> Recent studies have revealed that dental implant therapy in SS patients may present a high implant survival rate, low marginal bone loss and low biological complications.<sup>3</sup> However, the evidence is limited. Most reports have shown promising results,<sup>15</sup> but one small study exhibited that marginal peri-implant bone loss and bleeding was higher in secondary SS (sSS) patients compared with patients with RA without sSS.<sup>16</sup> One of the strengths of this study is that it represents the long-term assessment of implant therapy since the insertion of



**Fig 1.** Radiographic evaluation of prosthetic reconstruction of teeth 16, 24, 25 and 26 at baseline

the first implants, which is only reported in one study in the literature.<sup>17</sup> We aimed to investigate the possibility of implant-supported fixed prostheses rehabilitation in patient (46-year-old female) with Sjogren's syndrome and the advantages of this treatment option during seven years.

### Materials and Methods

#### *Patient's selection*

A 46-year-old caucasian female patient presented to the private dental office for the implant-supported prosthetic reconstruction of teeth 16, 24, 25 and 26 in September 2010 (Figure 1). The patient's chief complaint was the inability to chew foods effectively, and there were no records of any systemic diseases at this time interval. Due to the existence of several old cement-retained fixed prostheses and the patient's reluctance to reconstruct the mouth at once, an intermittent treatment plan was chosen and, based on the patient's request and existent edentulous areas; the rehabilitation began from the maxilla. The patient was instructed to rinse the mouth with 0.12% chlorhexidine gluconate (Tehrandaru Pharmaceutical Co., Tehran, Iran) mouthwash for 1 minute preoperatively and then two times a day for one week postoperatively.

#### *Study design*

Dental implants (Implantium II, Dentium Co., Seoul, South Korea) were placed in the positions of both maxillary first molars (teeth 16 and 26) and maxillary left premolars (teeth 24 and 25). Also, a trans alveolar sinus floor elevation procedure without grafting materials was

performed by 2 mm for placing the dental implant in the position of maxillary right first molar.<sup>18</sup> Besides, guided-bone regeneration (GBR) procedure with a collagen membrane (Jason<sup>®</sup> membrane, Botiss biomaterials GmbH, Zossen, Germany) and grafting materials (Cerabone, Botiss biomaterials GmbH, Zossen, Germany) was done in the positions of maxillary left premolar due to the thinning of the buccal bone plate during the implant placement. Implantation was done according to the two-stage approach,<sup>19-21</sup> and adequate primary stability was achieved. The prosthesis reconstruction of the implanted sites was completed four months later. After the delivery of the prosthesis of all maxillary implants, both secondary molars which were maintained with the intention to preserve vertical dimensions were extracted, and the patient was enrolled in a maintenance program every six months. After one year, the teeth (20 and 42) were extracted, and two dental implants were placed two months later according to the staged protocol.<sup>22</sup>

#### *Variables and data sources*

The literature describes 23 SS patients who were treated with dental implants (Table 1). Of the reported patients, five had primary SS (pSS), 16 had sSS, and two patients had possible sSS. In almost all patients with sSS, the associated disease was rheumatoid arthritis (RA). For most of the patients, there are no records of smoking habits and data regarding the long-term success of the implants are limited. Indeed, it is well recognized that tobacco smoking is a critical risk factor for crystal bone loss around teeth and implants.<sup>23</sup> Hence, it is assumed

## Dental Implants in Sjögren Syndrome

Eur J Transl Myol 30 (2): 334-340, 2020

**Table 1.** Patients with Sjögren's syndrome reported being treated with implant-supported prostheses in the literature.

Study	Year/Ref.	No. of Implants	No. of Patients	Follow-up Duration (years)	Type of prosthesis	Follow-up results
Payne et al.	1997/ <sup>39</sup>	26	3	8	Fixed	Lost additional implant in one patient
Isidor et al.	1999/ <sup>38</sup>	52	8	4	Fixed or overdenture	Lost additional implant in two patients
Binon	2005/ <sup>17</sup>	6	1	13	Fixed	Stable
Oczakir et al.	2005/ <sup>40</sup>	12	2	2 and 5	Fixed	Stable
Spinato et al.	2010/ <sup>41</sup>	6	1	1	Fixed	Stable
Weinlander et al.	2010/ <sup>42</sup>	21	4	3.5 to 7.6	Fixed, Overdenture and complete denture	NS
Ergun et al.	2010/ <sup>43</sup>	6	1	2	Fixed	Stable
Peron et al.	2017/ <sup>44</sup>	5	1	3	Fixed	Stable
Chochlidakis et al.	2018/ <sup>15</sup>	6	1	2	Fixed	Stable
Mori et al.	2018/ <sup>26</sup>	8	1	3	Fixed	Stable

NS, Not specified; No., Number.

that smokers with SS are at an increased risk of peri-implantitis compared with non-smoker SS patients.<sup>24</sup> Further long-term controlled studies are required to assess the role of smoking as a confounding factor for peri-implantitis in SS patients.

### Results

#### *The first-year follow-up*

One year following the placement of dental implants in the posterior maxilla, the patient presented with the chief complaint of mobile old cement-retained fixed prostheses of the mandibular lateral incisors. The team of specialists including a periodontist and a prosthodontist concluded that the prognosis of both mandibular incisors is hopeless. Due to the presence of a thin buccal bone plate, a simultaneous GBR procedure was performed. The primary stability was adequate, and the healing of the tissues was uneventful. Reconstruction of the site by implant-supported four units prosthesis was completed three months after the dental implant placement.

#### *The fifth-year follow-up*

A the fifth-year follow-up, the patient presented with the intention for examination and possibly replacing the old cement-retained prostheses of mandibular left molars (teeth 36 and 37). She reported that she had been diagnosed with Sjögren's syndrome based on the

evaluation of a rheumatologist two years earlier. There were xerostomia and positive serology for SS markers. Long before the diagnosis of SS, she had suffered from intermittent unilateral swelling of the cervical lymph nodes, dry mouth, occasional fevers, malaise and numbness of the extremities, but after the consumption of prescribed drugs, the symptoms of SS were alleviated. She was taking prednisone 5mg (Abureyhan Pharmaceutical Co. Tehran, Iran), hydroxychloroquine sulfate (Tehrandaru Pharmaceutical Co., Tehran, Iran), alendronate 70mg (Avecinna Pharmaceutical Co. Tehran, Iran), multiple vitamins and artificial tear. Laboratory tests revealed high SGOT and SGPT levels, high erythrocyte sedimentation rate (ESR), standard serum protein electrophoresis, BUN, creatinine, calcium, and phosphorus levels. After consulting with the patient's physician and ensuring the stability of the disease, it was decided to continue dental treatment. Following a careful inspection, the teeth were concluded to have a hopeless prognosis because of extensive caries. Therefore, teeth 36 and 37 were extracted, and a single implant was placed in the position of the mandibular first molar. The prosthetic reconstruction of the mandibular left first molar was completed four months later. Afterward, the patient was enrolled in a supportive care program every six months.

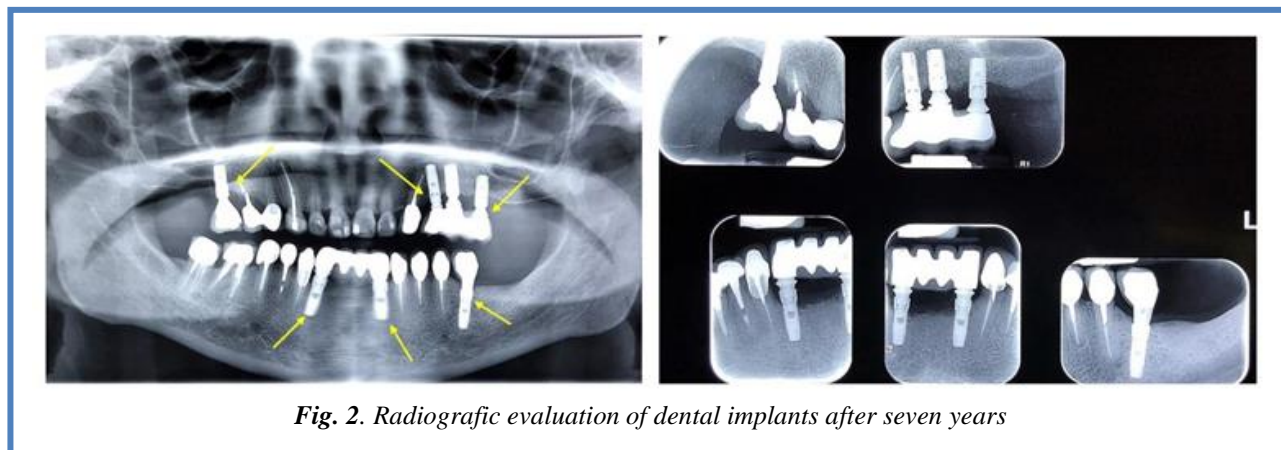


Fig. 2. Radiographic evaluation of dental implants after seven years

#### The seventh-year follow-up

In the recent follow-up visit in December 2018, no signs of inflammation, pain or bleeding were observed in the implant-reconstructed sites. The very first paced dental implant in the posterior maxilla seven years ago were also functional and free of any signs of pathology. The radiographic evaluation revealed some bone loss in the maxillary first molars, especially on the right side. Considering that another physician extracted the right upper molar, the radiographic resorption of the bone in the distal side of the maxillary first molar implant could be due to the traumatic extraction of the adjacent tooth. However, clinically there were no signs of peri-implant mucositis or peri-implantitis (Figure 2).

#### Discussion

There are several articles in the literature reporting the successful rehabilitation of medically compromised patients with dental implants<sup>25</sup>. Accordingly, this research discussed a patient with SS, who was effectively treated with implant-supported prostheses. The literature did not contain definite evidence about the long-term success of dental implants in SS-affected patients but delayed healing implants in patients with SS have exhibited crestal bone loss without clinical symptoms.<sup>15</sup> Also, it has been proposed that implant therapy in patients with SS carries potential risks such as disturbed wound healing, early failure of osseointegration and the development of peri-implantitis.<sup>26-28</sup> This report indicated that dental implants are a safe and predictable alternative for the treatment of edentulous patients with SS. In order to comprehend the challenges in the dental management of SS patients, a review of the literature regarding the dental implants in SS patients is necessary. The reviewed literature suggests that it is feasible to place dental implants in patients with SS, however, underlines that the success rate is lower than in a healthy population. Several factors might influence postoperative healing in SS patients, including altered protein profile in the saliva, modifications of the normal flora, and the consumption of systemic steroids.<sup>3,8</sup> The described patient in this report had experienced no comorbidities and was

diagnosed with pSS. Thus, it is reasonable to presume that all the challenges and complications, which may be encountered in the treatment of this patient, are related to the SS. As mentioned earlier, the most common challenge in the dental management of SS patients is the dryness of the mouth.<sup>14</sup> The patient had experienced SS related symptoms long before the definite diagnosis of SS. Because no removable dentures were worn by the patient and the presence of mild symptoms, it was difficult to conclude an SS diagnosis at the first visit in 2010. Previous studies have demonstrated that oncology patients who underwent radiotherapy to the head and neck, developed xerostomia and had a predisposition to developing peri-implantitis.<sup>29</sup> It is also stated that SS patients showed a significant elevation in the serum IgG antibody levels to *Aggregatibacter actinomycetem comitans* and *Porphyromonas gingivalis* compared to healthy subjects and therefore are at high risk for the development of peri-implantitis.<sup>30-34</sup> However, despite some bone loss in the distal side of one implant, all inserted implants in this specific patient were stable during the 7-year follow-up period, and no signs of pathology were seen. Also, the inserted implants demonstrated uneventful postoperative healing and achieved adequate oral function and stability. This observation suggests that given implant maintenance therapy was successful. The supportive maintenance program consisted of recall once every six months; disinfection therapy using 0.2% chlorhexidine gel (PerioKin, Laboratorios Kin, SA, USA); and application of fluoride to the remaining teeth. As mentioned earlier, the potential risk of peri-implantitis in SS patients demands the importance of regular maintenance therapy<sup>35</sup>. A recent clinical trial highlights that supportive maintenance therapy reduces the risk of peri-implantitis from 44% to 18%.<sup>36</sup> These results highlighted that in the dental management of SS patients, the synchronization between the periodontist, prosthodontist and rheumatologist is of great significance. The literature also describes distal extremities' neuropathies, which was reported by the patient in this study.<sup>37</sup> Accordingly, it is essential to be concerned about local neuropathy following dental implant surgery in patients affected with

SS. In this regard, the patient reported no neurosensory disturbances after implant placement. Considering the high prevalence of sSS, it is likely that dentists will encounter sSS patients in their daily practice.<sup>3</sup> It is fundamental to bear in mind the lower success rates of the dental implant in patients with SS compared to healthy patients; however, improving the patient's quality of life with the appropriate dental implant treatment plan is similarly essential. It has been reported that the self-confidence and oral function of the SS patients, will significantly improve with implant-supported prostheses compared with removable complete dentures.<sup>38</sup> The present study indicates that successful long-term maintenance of dental implants can be achieved in SS patients.

In summary, implant-supported prosthodontic rehabilitation of the SS patient is a safe and predictable treatment option. No signs of peri-implantitis or peri-implant mucositis were observed during 7-years following the placement of implants. The reports on this subject are limited in the literature, but indicating a lower success rate of the dental implant in SS patients compared with healthy subjects. Further studies are required to achieve the most beneficial clinical approach in the dental management of SS patients.

### List of acronyms

BUN: Blood urea nitrogen  
ESR: Erythrocyte sedimentation rate  
GBR: Guided-bone regeneration  
IgG: Immunoglobulin G  
pSS: Primary Sjögren's syndrome  
RA: Rheumatoid arthritis  
SGOT: Serum glutamic oxaloacetic transaminase  
SGPT: Serum glutamic pyruvic transaminase  
SLE: Systemic lupus erythematosus  
SS: Sjögren's syndrome  
SSc: Systemic sclerosis  
sSS: Secondary Sjögren's syndrome

### Authors contributions

HD, NE and RV equally participated in experimental design, data collection, writing and manuscript revision.

**Acknowledgments** None.

**Funding** This research study did not receive any specific grant from funding agencies in the public, commercial, or not-for-profit sectors.

### Conflict of Interest

The authors declare they have no financial, personal, or other conflicts of interest and confirm that this article is an original work and is not under publication nor reviewing elsewhere.

### Ethical Publication Statement

We confirm that we have read the Journal's position on issues involved in ethical publication and affirm that this report is consistent with those guidelines.

### Corresponding Author

Dr. Nasrin Esfahanizadeh, Department of Periodontology, Faculty of Dentistry, Tehran Medical Sciences, Islamic Azad University, Tehran, Iran. Tel: +989122156687. ORCID iD: 0000-0002-6136-9456  
Email: [n\\_esfahanizadeh@yahoo.com](mailto:n_esfahanizadeh@yahoo.com)

### E-mails of co-authors

*Hamidreza Daneshparva:* [hardanesh@yahoo.com](mailto:hardanesh@yahoo.com)

ORCID iD: 0000-0003-2927-0904

*Reza Vafadoost:* [dr.vafadoost@gmail.com](mailto:dr.vafadoost@gmail.com)

ORCID iD: 0000-0003-0042-9184

### References

1. Reale M, D'Angelo C, Costantini E, et al. MicroRNA in Sjogren's Syndrome: Their Potential Roles in Pathogenesis and Diagnosis. *J Immunol Res* 2018; 2018:7510174. 10.1155/2018/7510174.
2. Ji J, Sundquist J, Sundquist K. Gender-specific incidence of autoimmune diseases from national registers. *J Autoimmun* 2016;69:102-6. 10.1016/j.jaut.2016.03.003.
3. Almeida D, Vianna K, Arriaga P, et al. Dental implants in Sjogren's syndrome patients: A systematic review. *PLoS One* 2017;12:e0189507. 10.1371/journal.pone.0189507.
4. Vivino FB. Sjogren's syndrome: Clinical aspects. *Clin Immunol* 2017;182:48-54. 10.1016/j.clim.2017.04.005.
5. Brito-Zeron P, Ramos-Casals M, group E-Stf. Advances in the understanding and treatment of systemic complications in Sjogren's syndrome. *Curr Opin Rheumatol* 2014;26:520-7. 10.1097/BOR.0000000000000096.
6. Mathews SA, Kurien BT, Scofield RH. Oral manifestations of Sjogren's syndrome. *J Dent Res* 2008; 87:308-18. 10.1177/154405910808700411.
7. Seifi Kafshgari H, Yazdani M, Ranjbar R, et al. The effect of Citrullus colocynthis extracts on Streptococcus mutans, Candida albicans, normal gingival fibroblast and breast cancer cells. *J Biol Res* 2019;92. 10.4081/jbr.2019.8201.
8. Goules AV, Tzioufas AG. Primary Sjogren's syndrome: clinical phenotypes, outcome and the development of biomarkers. *Immunol Res* 2017;65:331-44. 10.1007/s12026-016-8844-4.
9. Cornec D, Jamin C, Pers JO. Sjogren's syndrome: where do we stand, and where shall we go? *J Autoimmun* 2014;51:109-14. 10.1016/j.jaut.2014.02.006.
10. Albrecht K, Callhoff J, Westhoff G, et al. The Prevalence of Dental Implants and Related Factors in Patients with Sjogren Syndrome: Results from a Cohort Study. *J Rheumatol* 2016;43:1380-5. 10.3899/jrheum.151167.
11. Dawes C, Pedersen AM, Villa A, et al. The functions of human saliva: A review sponsored by the World Workshop on Oral Medicine VI. *Arch*

- Oral Biol 2015;60:863-74. 10.1016/j.archoralbio.2015.03.004.
12. Karami A, Tebyanian H, Barkhordari A, et al. Healing effects of ointment drug on full-thickness wound. *C R Acad Bulg Sci* 2019;72:123-9.
  13. Pedersen AM, Bardow A, Nauntofte B. Salivary changes and dental caries as potential oral markers of autoimmune salivary gland dysfunction in primary Sjogren's syndrome. *BMC Clin Pathol* 2005;5:4. 10.1186/1472-6890-5-4.
  14. Jorkjend L, Johansson A, Johansson A, et al. Periodontitis, caries and salivary factors in Sjögren's syndrome patients compared to sex- and age-matched controls. *Journal of Oral Rehabilitation* 2003;30:369-78. 10.1046/j.1365-2842.2003.01088.x
  15. Chochlidakis K, Ercoli C, Elad S. Challenges in implant-supported dental treatment in patients with Sjogren's syndrome: A case report and literature review. *Quintessence Int* 2016;47:515-24. 10.3290/j.qi.a36009.
  16. Krennmair G, Seemann R, Piehslinger E. Dental implants in patients with rheumatoid arthritis: clinical outcome and peri-implant findings. *J Clin Periodontol* 2010;37:928-36. 10.1111/j.1600-051X.2010.01606.x.
  17. Binon PP. Thirteen-year follow-up of a mandibular implant-supported fixed complete denture in a patient with Sjogren's syndrome: a clinical report. *J Prosthet Dent* 2005;94:409-13. 10.1016/j.prosdent.2005.09.010.
  18. Pjetursson BE, Lang NP. Sinus floor elevation utilizing the transalveolar approach. *Periodontol* 2000 2014; 66:59-71. 10.1111/prd.12043.
  19. Esposito M, Grusovin MG, Chew YS, et al. One-stage versus two-stage implant placement. A Cochrane systematic review of randomised controlled clinical trials. *Eur J Oral Implantol* 2009; 2:91-9.
  20. Soufdoost RS, Yazdani M, Tahmasebi E, et al. In vitro and in vivo evaluation of novel Tadalafil/ $\beta$ -TCP/Collagen scaffold for bone regeneration: A rabbit critical-size calvarial defect study. *Biocybernetics and Biomedical Engineering* 2019. <https://doi.org/10.1016/j.bbe.2019.07.003>.
  21. Esfahanizadeh N, Daneshparvar P, Takzaree N, et al. Histologic Evaluation of the Bone Regeneration Capacities of Bio-Oss and MinerOss X in Rabbit Calvarial Defects. *Int J Periodontics Restorative Dent* 2019; 39:e219-e27.
  22. Klokkevold PR, Han TJ, Camargo PM. Aesthetic management of extractions for implant site development: delayed versus staged implant placement. *Pract Periodontics Aesthet Dent* 1999; 11:603-10; quiz 12.
  23. Veitz-Keenan A. Marginal bone loss and dental implant failure may be increased in smokers. *Evidence-based dentistry* 2016; 17:6-7. 10.1038/sj.ebd.6401145.
  24. Negri BM, Pimentel SP, Casati MZ, et al. Impact of a chronic smoking habit on the osteo-immunoinflammatory mediators in the peri-implant fluid of clinically healthy dental implants. *Arch Oral Biol* 2016;70:55-61. 10.1016/j.archoralbio.2016.05.014.
  25. Esfahanizadeh N, Yousefi H. Successful Implant Placement in a Case of Florid Cemento-Osseous Dysplasia: A Case Report and Literature Review. *J Oral Implantol* 2018; 44:275-9. 10.1563/aaaid-joi-D-17-00140.
  26. Mori G, Kobayashi T, Ito T, et al. Implant-supported Prosthesis in Patient with Sjogren's Syndrome: Clinical Report with 3-year Follow-up. *The Bulletin of Tokyo Dental College* 2018; 59:201-6. 10.2209/tdcpublication.2017-0036.
  27. Shakeri F, Tebyanian H, Karami A, et al. Effect of Topical Phenytoin on Wound Healing. *Trauma Mon* 2017; 22:e35488. doi: 10.5812/trauma mon.35488.
  28. Babavalian H, Latifi AM, Shokrgozar MA, et al. Cloning and expression of recombinant human platelet-derived growth factor-BB in *Pichia Pink*. *Cell Mol Biol (Noisy-le-grand)* 2016; 62:45-51. <https://doi.org/10.14715/cmb/2016.62.8.8>.
  29. Hessling SA, Wehrhan F, Schmitt CM, et al. Implant-based rehabilitation in oncology patients can be performed with high long-term success. *Journal of oral and maxillofacial surgery : official J Oral Maxillofac Surg* 2015;73:889-96. 10.1016/j.joms.2014.11.009.
  30. Celenligil H, Eratalay K, Kansu E, et al. Periodontal status and serum antibody responses to oral microorganisms in Sjogren's syndrome. *Journal of periodontology* 1998; 69:571-7. 10.1902/jop.1998.69.5.571.
  31. Khomarlou N, Aberoomand-Azar P, Lashgari AP, et al. Essential oil composition and in vitro antibacterial activity of *Chenopodium album* subsp. *striatum*. *Acta Biologica Hungarica* 2018; 69:144-55. <https://doi.org/10.1556/018.69.2018.2.4>.
  32. Mosaddad SA, Tahmasebi E, Yazdani A, et al. Oral microbial biofilms: an update. *Mosaddad SA, Tahmasebi E, Yazdani A. Eur J Clin Microbiol Infect Dis* 2019. 10.1007/s10096-019-03641-9.
  33. Esfahanizadeh N, Nourani Mohammad R, Bahador A, et al. The Anti-biofilm Activity of Nanometric Zinc doped Bioactive Glass against Putative Periodontal Pathogens: An in vitro Study. *Biomedical Glasses* 2018. p. 95.
  34. Esfahanizadeh N, Mirmalek SP, Bahador A, et al. Formation of biofilm on various implant abutment materials. *Gen Dent* 2018; 66:39-44.
  35. Jepsen S, Berglundh T, Genco R, et al. Primary prevention of peri-implantitis: managing peri-

## Dental Implants in Sjögren Syndrome

Eur J Transl Myol 30 (2): 334-340, 2020

- implant mucositis. *J Clin Periodontol* 2015; 42 Suppl 16:S152-7. 10.1111/jcpe.12369.
36. Costa FO, Takenaka-Martinez S, Cota LO, et al. Peri-implant disease in subjects with and without preventive maintenance: a 5-year follow-up. *J Clin Periodontol* 2012; 39:173-81. 10.1111/j.1600-051X.2011.01819.x.
  37. Pavlakis PP, Alexopoulos H, Kosmidis ML, et al. Peripheral neuropathies in Sjogren's syndrome: a critical update on clinical features and pathogenetic mechanisms. *J Autoimmun* 2012; 39:27-33. 10.1016/j.jaut.2012.01.003.
  38. Isidor F, Brøndum K, Hansen H, et al. Outcome of treatment with implant-retained dental prostheses in patients with Sjögren syndrome. *Int J Oral Maxillofac Implants* 1999; 14:736-43.
  39. Payne AG, Lownie JF, Van Der Linden WJ. Implant-supported prostheses in patients with Sjogren's syndrome: a clinical report on three patients. *Int J Oral Maxillofac Implants* 1997;12:679-85.
  40. Oczakir C, Balmer S, Mericske-Stern R. Implant-prosthodontic treatment for special care patients: a case series study. *Int J Oral Maxillofac Implants* 2005; 18:383-9.
  41. Spinato S, Soardi CM, Zane AM. A mandibular implant-supported fixed complete dental prosthesis in a patient with Sjogren syndrome: case report. *Implant Dent* 2010; 19:178-83. 10.1097/ID.0b013e3181dbe081.
  42. Weinlander M, Krennmair G, Piehslinger E. Implant prosthodontic rehabilitation of patients with rheumatic disorders: a case series report. *Int J Oral Maxillofac Implants* 2010; 23:22-8.
  43. Ergun S, Katz J, Cifter ED, et al. Implant-supported oral rehabilitation of a patient with systemic lupus erythematosus: case report and review of the literature. *Quintessence Int* 2010; 41:863-7.
  44. Peron C, Javed F, Romanos GE. Immediate Loading of Tantalum-Based Implants in Fresh Extraction Sockets in Patient With Sjogren Syndrome: A Case Report and Literature Review. *Implant Dent* 2017;26:634-8. 10.1097/id.0000000000000594.

Submission: January, 9, 2020

Revision received: February 15, 2020

Acceptance: February 16, 2020