

# Penile lengthening original technique using a pubo-cavernous spacer. Long term results from a series of over 200 patients

Antonio Rossi<sup>1</sup>, Giovanni Alei<sup>2</sup>, Marco Frisenda<sup>1</sup>, Antonio Tufano<sup>1</sup>, Pietro Viscuso<sup>1</sup>,  
Guglielmo Mantica<sup>3</sup>, Pierluigi Bove<sup>4</sup>, Rosario Leonardi<sup>5</sup>, Alessandro Calarco<sup>6</sup>

<sup>1</sup> Maternal and Infantile and Urogynaecological Sciences Department, Sapienza University of Rome, Rome, Italy;

<sup>2</sup> Department of General Surgery and Plastic Aesthetic Surgery, Sapienza University of Rome, Rome, Italy;

<sup>3</sup> Policlinico San Martino, Genova, Italy;

<sup>4</sup> San Carlo di Nancy Hospital, Rome, Italy;

<sup>5</sup> Casa di Cura Musumeci-Gecas, Gravina di Catania (CT), Italy;

<sup>6</sup> Department of Urology, "Cristo Re" Hospital, Rome, Italy.

**Summary** *Introduction: We report our long experience in the surgical treatment of patients requesting penile lengthening by suspensory ligament release and placement of a custom-made soft silicone pubo-cavernous spacer. The aim was to show that with this surgical technique the results obtained are maintained over time. It is crucial to achieve postoperative satisfaction of these patients who show fragility and self-esteem problems.*

*Methods: From 1999 to 2020, we treated 245 patients with congenital or acquired penile brevity. We carefully analysed the preoperative and postoperative (at 6, 12, 24 and 48 months) penile size of the patients to evaluate whether this technique could allow the long-term maintenance of aesthetic results.*

*We also assessed preoperative erectile function and we focused on the psychological aspects to avoid surgery in patients with dysmorphism. This original technique involves the section of the suspensory ligament and the implantation of a silicone spacer between the pubic symphysis and the corpora cavernosa. This spacer is conformed to the patient anatomy and maintains the relationship between the anatomical structures unchanged over time. Sexual self-esteem and patient satisfaction were assessed with the APPSSI questionnaire.*

*Results: The mean increase in penile length was about 2.5 cm in flaccid state and 1.9 cm in stretched state. There were no injuries of the neurovascular bundle or urethra, and no erectile dysfunction was noted. These results persisted at 6, 12, 24 and 48 months without significant differences. Over 80% of patients stated that they were completely satisfied with the results obtained. This satisfaction remained stable along follow up.*

*Conclusion: The section of the suspensory ligament and the implant of the soft silicone spacer provide real penis elongation with satisfactory results that persist over time. This technique avoids the frequent complication of short-term shortening due to the scar adhesions of the edges of the dissected ligament. The high aesthetic satisfaction of patients is stable at controls at 6, 12, 24 and 48 months.*

**KEY WORDS:** Penile lengthening; Penile augmentation; Penile elongation; Pubo-cavernous spacer; Small penis; Suspensory ligament release.

Submitted 8 September 2022; Accepted 9 September 2022

No conflict of interest declared.

## INTRODUCTION

Men have always been worried about penis size, which can seriously affect their self-esteem. They have the tendency to seek their identity in the penis with the belief that "bigger is better". The stigmas of a small penis, as well as the increasing media influence on sexual issues, have created an increase demand for penile enhancement (1). The term microphallus or micropenis is referred to a penis that is formed normally but is of a small size (less than 7-8 cm during erection or stretched state) and it is probably associated with abnormal production, or a reduced activity, of LH hormone (2). On the other hand, the altered perception of the organ size is called "dysmorphism". These patients present with a normal-sized penis but are dissatisfied both in a flaccid state and during erection (3, 4). It is mandatory for these patients to undergo a psychosexual counselling and try to avoid surgery. The demand for penile lengthening had a tremendous increase in recent years.

According to the published data, majority of men who request penile enhancement surgery usually have a normally sized and normally functioning penis (5). In our experience, the most common request for penile lengthening comes from patients that suffer from the so-called "locker room syndrome", i.e. anxiety and embarrassment arising from changing in front of the others. At present, no current consensus guidelines are available for treatment of patients with a normal-sized penis (6).

The short penis can be congenital or acquired. The congenital small penis is defined as measurements of < 7-8 cm upon erection. The acquired disorders are caused by Peyronie's disease or outcomes of partial penectomy for penile carcinoma. Finally, there are cases of relative short penis due to excess pubic fat.

The reported normal length of an adult flaccid penis ranges between 7.6 cm and 10.7 cm, and between 11.4 cm and 14.8 cm in erection (7). The increase in length following surgery that is required to satisfy the patient is not well established and is not adequately emphasized in the medical literature.

The gold standard of penile lengthening technique consists in the dissection of the suspensory ligament followed by cutaneous “V to Y” or “Z” plasties (8-10). In cases where the penile shortening is associated with abundant pubic fat, the dissection of the suspensory ligament is performed along with a suprapubic lipectomy or pubic liposuction (11). This cosmetic surgery is commonly performed by experienced plastic surgeons and results in an aesthetic visual lengthening effect. In the last years, new surgical techniques for penile lengthening have been developed to improve the aesthetic appearance and functional state of the penis, giving rise to much controversy regarding their safety, and efficacy (12-18).

We report our approach of penile lengthening using a soft silicone pubo-cavernous spacer after suspensory ligament release.

### METHODS

This study is a retrospective analysis of patients who underwent penile lengthening by sectioning of penile suspensory ligament and using a soft silicone custom-made spacer made between the 1999 and the 2020. We have used this surgical procedure in 245 patients aging between 18 and 67 (average age 35 years).

The study population included patients with congenital small penis (172); patients with short penis due to fibrosis caused by either Peyronie’s disease or trauma (67); patients with short penis resulting from partial penectomy for penile carcinoma (6).

In order to select patients qualified for surgery, every patient underwent a pre-surgical diagnostic screening consisting of:

- medical history, physical examination, sexual hormone profiles.
- psychiatric/psychosexual assessment.

All patients were interviewed by an andro-sexologist. This was done especially in order to understand the motivations, expectations, self-esteem, and to discourage from surgery patients with dysmorphic disorder.

Preoperative photographs and measurements of the penis were carried out in flaccid state, stretched state and during maximal erection, after intracavernous injection of alprostadil (Prostaglandin E1 PGE1: 1-5 mcg).

The preoperative measures were taken from the base of the penis to the tip of the glans. Penile length during erection was also evaluated from the pubo-penile junction to the tip of the glans in the dorsal surface in order to evaluate the angle between the penis shaft and the pubis. This is important to select patients for procedure; in fact patients with laxity of the suspensory ligament or angle > 30° upon erection, were excluded because in these cases we will not obtain significant improvement in length.

Average measures were 5.6 cm (from 3.8 to 8.2 cm) in flaccid state (mean initial flaccid length), 10.9 cm (from 6.2 to 13.5 cm) during stretched state (mean initial erect length or SPL) and 11.2 (from 6.5 to 14 cm) during erection.

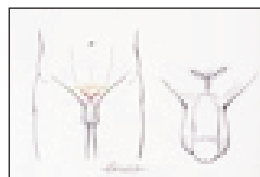Each patient underwent a Doppler penile ultrasound in the flaccid and erect state after PGE1 administration to identify any preexisting condition such as Peyronie’s disease and vascular erectile dysfunction.

The erectile function was also assessed with the administration of the *International Index of Erectile Function Questionnaire* (IIEF) and with a nocturnal penile tumescence test (*Rigiscan Plus - Dacomed Corporation, Minneapolis, MN, USA*).

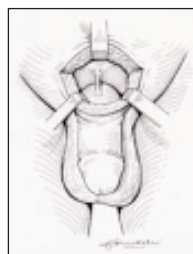
### Surgical technique

Skin incision is made with the V-Y technique in order to allow simultaneous skin lengthening at the time of suturing. The incision is performed about 2-3 cm at the midpoint of the pubo-penile arch (Figure 1).

After the incision of the subcutaneous tissue, the *Scarpa* fascia is reached. This is exposed in order to reveal the



**Figure 1.**  
Skin incision with V-Y technique.  
Each branch is about 2 cm



**Figure 2.**  
Exposure of the penis suspensory ligament.



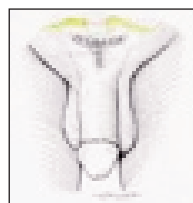
**Figure 3.**  
Suspensory ligament release by scissors along the anterior side of the pubic symphysis.



**Figure 4.**  
Conformation of the spacer and its relations with the anatomical structures. Passage of the points of O Prolene.



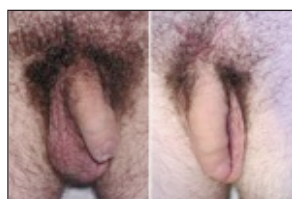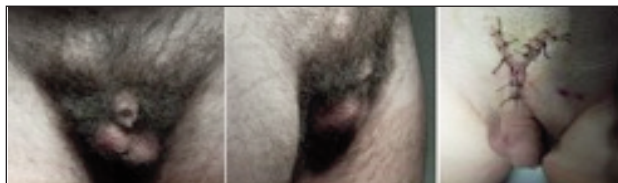
**Figure 5.**  
3D reconstruction of the relationships between the spacer and the surrounding anatomical structures.



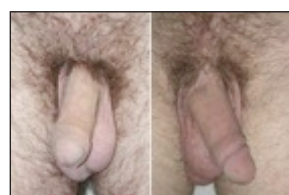**Figure 6.**  
Final Y suture in order to stretch the pubic skin.

**Figure 7.**

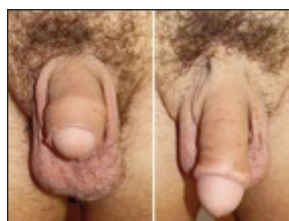Preoperative and postoperative result at 7 days.

**Figure 8.**

Preoperative and postoperative result at 30 days.

**Figure 9.**

Preoperative and postoperative result at 6 months.

**Figure 10.**

Preoperative and postoperative result at 12 months.

fundiform ligament, that is then resected. Below it, the suspensory ligament (Figure 2) is dissected by scissors along the anterior side of the pubic symphysis in an area which is usually avascular (Figure 3).

This step is performed while the assistant keeps the patient's penis fully stretch in order to feel the release of the corpora cavernosa.

At this point a block of soft silicone (*Allied Biomedical carving blocks*) is cut to fit the angle created by the cavernous bodies and the pubic symphysis, taking care to conform with the measurements of the newly formed cavity; the spacer is shaped to come into contact anteriorly with the surface of the corpora cavernosa which is convex, while posteriorly with the anterior wall of the pubic symphysis which is concave (Figure 4).

Four 0 Prolene stitches are passed through the spacer, two stitches in the deep part, one on the left and one on the right side, and two stitches in the superficial part. Holding back the spacer, the stitches are passed through the periosteum of the pubic symphysis into the deep part. The silicon spacer is inserted into the cavity and the first two stitches, previously placed in the deep part, are tied. The other two stitches are secured to the periosteum in the uppermost part of the newly formed cavity, taking care not to exert pressure upon the penile structures (Figures 4, 5).

A drain is placed in the deeper part of the formed cavity, which is usually removed 12 to 24 hours after surgery.

The subcutaneous part, in the deep tract, is closed with polyglycolic acid, then the *Scarpa* fascia is sutured using interrupted sutures in polyglycolic acid. A Y suture, in polyglycolic acid or silk, is then performed to guarantee lowering of the pubo-penile arch (Figure 6).

This latter surgical step is of utmost importance in order to avoid impairment of the lengthening procedure. According to the surgeon's opinion, this can also be integrated with further cutaneous plasty with Z elongation. Placement of a bladder catheter at the end of surgery depends on the type of anesthesia used. In case a catheter is placed, this must be removed within 12 hours.

In our case series, the mean operative time was 78 minutes, ranging from 58 to 116 minutes. Postoperative antibiotic therapy consists of a combined therapy with rifampicin 300 mg/die, minocycline 50 mg/die and moxifloxacin 400 mg/die for one week. Patients are instructed to refrain from sexual intercourses for 30 days after surgery. No traction or vacuum device was used postoperatively.

#### Postoperative follow-up and statistical analysis

After the post-operative checks, the patients were evaluated at 6, 12, 24 and 48 months.

The objective increase in length was calculated by subtracting the preoperative flaccid length and preoperative SPL from the postoperative flaccid length and postoperative SPL respectively.

The satisfaction of surgical outcome was assessed at 6, 12, 24 and 48 months after surgery by directly asking the patients: "Are you satisfied with the result of surgery?" and with the APPSSI questionnaire at the annual check.

The results expressed as mean  $\pm$  standard deviation (SD) were compared using paired and unpaired Student T test, Fischer exact probability test and Chi-squared test.

#### RESULTS

Good aesthetic results were obtained in all cases.

The results relating to the aetiology are shown in Table 1. All patients, despite of the aetiology category, showed a significant increase of penile length (Figures 7-9).

The mean increase in flaccid state was  $2.54 \pm 0.9$  cm ( $p < 0.005$ ), and in stretched state was  $1.91 \pm 1.1$  cm ( $p < 0.005$ ). Minimal lengthening obtained in flaccid state was 1.6 cm and in stretched state was 0.9 cm. The best result was an elongation of 3.5 cm in the flaccid state and of 3.0 cm in stretched state (Figure 10).

The psychosexual impact of the operation was favorable in the majority of cases. Sexual self-esteem and patient satisfaction were significantly improved, as shown by the results of the *Augmentation Phalloplasty Patient Selection and Satisfaction Inventory* (APPSSI) completed 12 months postoperatively (Table 2).

Improved self-esteem was recorded in all but eleven patients (234 out of 245 patients scored 95.9%).

Two hundred (81.6%) out of 245 patients were completely satisfied with the outcomes of surgery to all follow-up checks. Sexual activity was encouraged from the fourth postoperative week.

At the 6 and 12-month follow-up visit, all patients reported a normal erectile function. The 6-month IIEF was com-

**Table 1.**  
Results in relation to etiology.

	Patient n°	Mean initial flaccid length, cm	Mean initial stretched penile length, (SPL ± SD), cm	Mean increase in flaccid state, cm	Mean increase in stretched penile length (SPL ± SD), cm	Satisfaction %
Overall	245	5.6 ± 0.8	10.9 ± 1.1	2.54 ± 0.9**	1.91 ± 1.1**	81.6
Congenital small penis	113	6.5 ± 0.9	11.4 ± 1.6	2.7 ± 0.8*	1.2 ± 1.2*	93
Congenital micropenis	69	3.8 ± 1.1	11.5 ± 2.7	2.2 ± 0.7	1.7 ± 1.3	87
Peyronie's disease	60	4.9 ± 0.9	6.2 ± 1.7	3 ± 0.5	1.8 ± 1.2	80
Penile trauma	7	7.7	9.3	2.8	1.8	93
Penile carcinoma	6	5.6	6.8	2.5	2	75

SPL = stretched penile length; SD = standard deviation. Student T test. \*p < 0.005. Student T test. \*\*p < 0.0005.

**Table 2.**  
APPSSI results.

Suitability assessment (preoperative)	n°	Outcome evaluation (1 year postoperative)	n°
Slight sexual confidence disturbance and/or weak willingness to undergo surgery (total score 10-12)	0 (unsuitable candidate)	No complaints of penile inadequacy and excited about postoperative result (total score 10-12)	177 patients
Mild complaints, with surgery appearing as a remote option (total score 7-9)	12 patients	Mild complaints but satisfied (total score 7-9)	58 patients
Moderate complaints but skeptical of surgery (total score 4-6)	68 patients	Moderate complaints, with no improvement or indifferent results (total score 4-6)	10 patients
Severe complaints, with surgery inevitable option (total score 0-3)	165 patients	Severe complaints, condition worse than preoperatively (total score 0-3)	0 patients

Patients total (N): 245 patients.  
Chi-square test with three degrees of freedom = 134.1.  
P < 0.00001. Fisher exact probability test P < 0.00001.  
APPSSI = Augmentation Phalloplasty Patient Selection and Satisfaction Inventory.

pleted, and no substantial difference compared to preoperative was found. No postoperative nighttime rigidometry was necessary.

As far as the complications are concerned, the following minor events have been observed: infection of the wound in 6 patients (2.5%), moderate pain which disappeared after four weeks in 43 patients (17.5%), and pain exceeding 2 months in 8 patients (3.2%). No alterations in sensitivity during sexual intercourses were reported.

At 12 and 24 months after surgery the penile ultrasound in flaccid state and during erection performed to all patients revealed the correct positioning of space-maintainer.

Only one patient requested removal of the spacer after 13 years. This patient had an important weight loss (43.5 kg) and the spacer came slightly to the surface without creating problems during intercourse.

**DISCUSSION**

Men with small penis are insecure and question their own sexual value (1).

By cutting the suspensory ligament below the symphysis the penis can be elongated.

However, the suspensory ligament resection does not guarantee definitive results due to scarring of the tissue along the edges of the resection of the ligament itself (6, 19).

In order to maintain the distance between the dorsal side of the cavernous bodies and the pubic symphysis, we have made various attempts (considered several possibilities), at first by using a silicone tip of a penile prosthesis and then a testicular silicone prosthesis as described by other surgeons (10). These materials, both biocompatible and available on the market, were not found to be suit-

able for this purpose. In this case series, a soft type silicone polymer was used as space maintainer.

This material has the following advantages: soft type silicone is available in many shapes and sizes; all carving blocks are made of solid silicone elastomer designed for permanent implantation; implants may be trimmed with a scalpel or scissors to meet the individual patient's needs; implants may be adaptable with the shape and dimension of every newly formed cavity.

All the above-mentioned advantages are not achievable by using a testicular prosthesis or fat flap, because it cannot adapt its shape to the cavity.

Dermal fat grafts or harvesting fat from remote sites were occasionally used to fill the dead space created by the descent of the corpora off the pubic bone after sectioning the suspensory ligament (20).

The extraction of the fat flap, on the other hand, makes the entire procedure extended in time and more invasive, as it is associated with higher morbidity, and bleeding can occur in the donor site. Moreover, it does not avoid the fibrotic retraction that is responsible for the reattachment of the penis to the pubis. The adjunctive post-operative stretching with vacuum devices or penile extenders is necessary in order to overcome this condition, with an increase in the final cost.

Moreover, published data on the resulting change in the penile length, using testicular prosthesis or fat flap, are scarce and controversy (21).

Advancing of the skin is always necessary. At this level, particularly in close proximity to the pubo-penile junction, the skin is thick, with more or less abundant adipose tissue and, in addition, it is hairy, therefore any insufficient advancement towards the penile shaft of the penis could cause an unsatisfactory result.

M plasty, which became popular in China, is frequently responsible for hypertrophic scars and even necrosis of tissue at the outer edge of the flaps. The V-Y advancement is the most commonly used technique; however, several concerns have been risen about the site and extent of the incision (22). The advantages of a Y suture, in our opinion are to guarantee lowering of the pubo-penile arch (Figure 5) and to avoid impairment of the lengthening performed.

Postoperative penile traction was not used, as per our experience, the positioning of the penile extender or vacuum device caused discomfort for the patients, was complicated and risky to manage and has given poor results. Our technique on the other hand, which includes inserting the space-maintainer of soft silicone into the new cavity, showed a very low incidence of penile retraction.

Finally, it is extremely important that the urologist evaluates very carefully the patient's reasons for requesting this kind of treatment, what does the patient expect from it and, in general terms, his psychological situation.

We personally insist that our patients have two or more sessions with an andro-sexologist and we stress that counselling cannot be conducted either by a "psychologist" or by a "sexologist" who do not have a proven specific competence in andrological problems. At the end of the counselling the andro-sexologist will prepare a signed report, which in turn will be signed by the patient as his approval.

It is also mandatory that the surgeon is particularly careful in case of patients looking only for cosmetic results, partly because their expectations may be far beyond reality and partly because the best surgical result involves a "normal" organ. Patients with dysmorphic disorder, profoundly depressed, psychotic patients or patients with not realistic expectations should not be submitted to this surgical procedure (1).

## CONCLUSIONS

Suspensory ligament release alone does not guarantee definitive results. Moreover, in some cases worsen the clinical situation due to scarring of the tissue along the edges of the resection of the ligament itself. The placement of a silicon spacer between the penis and the pubis seems to give the best results, as it prevents reattachment and a possible reshortening.

The definitive separation between the two anatomical structures is simple to carry out thanks to this small device. The soft silicone makes it easy to shape the spacer and adapt it to the newly formed anatomical cavity of each patient. It is also easy to fix to the pubis and remains stable over time (unlike the fibrosis resulting by use of other materials such as dermal matrix).

In our opinion this technique should finally guarantee excellent long-term aesthetic results and high satisfaction rate preventing local recurrence and the loss of the good initial results obtained.

## FOOTNOTE

Original drawings were made by G. Alei.

## REFERENCES

1. Sharp G, Oates J. Sociocultural influences on men's penis size perceptions and decisions to undergo penile augmentation: a qualitative study. *Aesthet Surg J*. 2019; 39:1253-1259.
2. Aaronson IA. Micropenis: medical and surgical implications. *J Urol*. 1994; 152:4-14.
3. Woodhouse CR. The sexual and reproductive consequences of congenital genitourinary anomalies. *J Urol*. 1994; 152:645-51.
4. Veale D, Miles S, Read J, et al. Relationship between self-discrepancy and worries about penis size in men with body dysmorphic disorder. *Body Image*. 2016; 17:48-56.
5. Mondaini N, Ponchiotti R, Gontero P, et al. Penile length is normal in most men seeking penile lengthening procedures. *Int J Impot Res*. 2002; 14:283-286.
6. Spyropoulos E, Christoforidis C, Borousas D, et al. Augmentation phalloplasty surgery for penile dysmorphism in young adults: considerations regarding patient selection, outcome evaluation and techniques applied. *Eur Urol*. 2005; 48:121-128.
7. Veale D, Miles S, Bramley S, et al. Am I normal? A systematic review and construction of nomograms for flaccid and erect penis length and circumference in up to 15,521 men. *BJU Int*. 2015; 115:978-986.
8. Campbell J, Gillis J. A review of penile elongation surgery. *Transl Androl Urol*. 2017; 6:69-78.
9. Hoznek A, Rahmouni A, Abbou C, et al. The suspensory ligament of the penis: an anatomic and radiologic description. *Surg Radiol Anat*. 1998; 20:413-417.
10. Li CY, Kayes O, Kell PD, et al. Penile suspensory ligament division for penile augmentation: indications and results. *Eur Urol*. 2006; 49:729-733.
11. Pestana IA, Greenfield JM, Walsh M, et al. Management of "buried" penis in adulthood: an overview. *Plast Reconstr Surg*. 2009; 124:1186-1195.
12. Protogerou V, Anagnostopoulou S, Venierates D, et al. Penis ligaments: their use in "increasing" the size of the penis in penile augmentation procedures. Anatomical description in human cadavers and clinical results of a phalloplasty series. *Ann Ital Chir*. 2010; 81:199-204.
13. Alter GJ, Jordan GH. Penile elongation and girth enhancement. *AUA Update Series* 2007; 26:229-237.
14. Srinivas BV, Vasan SS, Mohammed S. Penile lengthening procedure with V-Y advancement flap and an interposing silicone sheath: A novel methodology. *Indian J Urol*. 2012; 28:340-342
15. Perovic SV, Djordjevic ML, Kekic ZK, Djakovic NG. Penile surgery and reconstruction. *Curr Opin Urol*. 2002; 12:191-194.
16. Goodwin WE, Scott WW. Phalloplasty. *J Urol*. 1952; 68:903-908.
17. Long DC. [Elongation of the penis]. *Zhonghua Zheng Xing Shao Shang wai ke za zhi = Zhonghua Zheng Xing Shao Shang Waike [i.e. Waike] Zazhi = Chinese Journal of Plastic Surgery and Burns*. 1990; 6:17-9.
18. Wessells H, Lue TF, McAninch JW. Complications of penile lengthening and augmentation seen at 1 referral center. *J Urol*. 1996; 155:1617-1620.
19. Shaeer O, Shaeer K, el-Sebaie A. Minimizing the losses in penile lengthening: "V-Y half-skin half-fat advancement flap" and "T-closure" combined with severing the suspensory ligament. *J Sex Med*. 2006; 3:155-60.
20. Vardi Y, Har-Shai Y, Gil T, Gruenwald I. A critical analysis of penile enhancement procedures for patients with normal penile size:

*surgical techniques, success, and complications Eur Urol. 2008; 54:1042-1050.*

21. Dillon BE, Chama NB, Honig SC. Penile size and penile enlargement surgery: a review. *Int J Impot Res. 2008; 20:519-529.*

22. Mertziotis N, Kozyrakis D, Bogris E. Is V-Y plasty necessary for penile lengthening? Girth enhancement and increased length solely through circumcision: description of a novel technique *Asian J Androl. 2013; 15:819-823.*

### Correspondence

Antonio Rossi, MD

antonio.rossi@uniroma1.it

Marco Frisenda, MD

marco.frisenda57hu@gmail.com

Antonio Tufano, MD

antonio.tufano@uniroma1.it

Pietro Viscuso, MD

pietro.viscuso@uniroma1.it

Maternal and Infantile and Urogynaecological Sciences Department  
Sapienza University of Rome, viale del Policlinico 155, 00161 Rome (Italy)

Giovanni Alei, MD

giovanni.alei@gmail.com

Department of General Surgery and Plastic Aesthetic Surgery,  
Sapienza University of Rome, viale del Policlinico 155, 00161 Rome (Italy)

Mantica Guglielmo, MD

guglielmo.mantica@gmail.com

Policlinico San Martino, Largo Rosanna Benzi, 10, 16132, Genova (Italy)

Bove Pierluigi, MD

San Carlo di Nancy Hospital, Via Aurelia, 275, 00165, Rome (Italy)

pierluigi.bove@uniroma2.it

Leonardi Rosario, MD

leonardi.r@tiscali.it

Casa di Cura Musumeci - Gecas,  
Via dell'Autonomia 57, Gravina di Catania (CT) (Italy)

Alessandro Calarco, MD (Corresponding Author)

alecalarco@gmail.com

Department of Urology, "Cristo Re" Hospital,  
via delle Calasanziane 25, 00167 Rome (Italy)