

# Management of encrusted ureteral stents: Two center experience

Mohanaragam Thangavelu<sup>1</sup>, Mohamed Yehia Abdallah<sup>2</sup>, Olubenga John Isola<sup>2</sup>, Ahmed Kotb<sup>3</sup>

<sup>1</sup> Department of Urology, Ysbyty Gwynedd, Bangor, LL57 2PW, United Kingdom;

<sup>2</sup> Department of Urology, Wrexham Maelor Hospital, Wrexham LL13 7TD, United Kingdom;

<sup>3</sup> Northern Ontario School of Medicine, TBRHSC, 980 Oliver Road, Thunder Bay, Ontario, Canada.

**Summary** Introduction: We present our experience of the endourological management of encrusted ureteral stents (EUS) and a literature review on forgotten encrusted ureteral stents.

Methods: A total of 13 encrusted ureteral stents from 12 patients were removed in two hospitals. The medical records were retrospectively analyzed for stent indication, indwelling time, clinical presentation, investigations, type and the number of surgical procedures, operative time, complications, duration of hospital stay, and the follow-up.

Results: Five ureteral stents (US) inserted before ESWL (extracorporeal shockwave lithotripsy) for renal stones, seven US for ureteric stones with ureteric colic, and one ureteral stent for post ureteroscopy procedure. The mean indwelling time was  $15.07 \pm 7.34$  months with a range from 6 to 24 months.

The mean Kidney, Ureter and Bladder (KUB) score of encrustation grading was  $11.84 \pm 2.07$  with a range from 9 to 15. The encrusted stents were removed by a combination of cystolithotripsy, semi-rigid ureteroscopy (URS), retrograde intrarenal surgery (RIRS), percutaneous nephrolithotomy (PCNL), and ESWL. The average total number of procedures to remove one EUS was  $3 \pm 1.08$  with a range of 2 to 5 procedures. Six encrusted stents were removed in one, five stents required two, one stent required three and one stent required four hospital admissions. The median operative time was 210 minutes with a range of 60 to 660 minutes per EUS removal and the mean hospital stay was  $2.69 \pm 1.43$  days with a range of 1 to 6 days. All patients had successful removal of encrusted stent and complete stone clearance with no major complications. In the follow-up, one patient had recurrent ureteric stone, one patient on regular stent exchange due to poor renal function and one patient developed significant ureteric stricture referred for reconstruction.

Conclusions: Removal of forgotten encrusted impacted ureteral stents is challenging and requires a multimodal surgical approach. It adds significant costs to the health care system and in addition it affects patient safety and quality of life. Patient education, avoiding unnecessary ureteral stent placement and a computerized stent monitoring system reduces the incidence of forgotten ureteral stents and their complications.

**KEY WORDS:** Encrusted ureteral stent; Bioflim; KUB score; Encrustation risk factor; Computerized stent registry.

Submitted 9 June 2022; Accepted 23 June 2022

No conflict of interest declared.

## INTRODUCTION

Ureteral stents are commonly used implants in urology practice mainly to relieve the ureteral obstruction due to stones, fibrosis, malignancy, and extrinsic compression. It is also used in ureteral reconstructive surgery and iatrogenic ureteral injuries to promote ureteral healing (1). The ureteral stents are intended for temporary use and should be removed or replaced within a specific time frame; otherwise prolonged stent presence beyond the specific time known as forgotten stents can lead to complications like stent encrustation, fragmentation, obstruction, urosepsis, renal failure, and mortality (2).

The incidence of forgotten ureteral stents is approximately 12% (2) and in the UK, a study reported that 13.6% of postoperative urology negligence claims are due to forgotten ureteral stents (3). Divakaruni *et al.* (2) quote that men are 2.8 times more likely to have forgotten stents than females and patients without health insurance are 6 times more likely to have forgotten stents. Alnadhari *et al.* (4) in their study of the management of 40 forgotten encrusted ureteral stents found that in 47.5% of forgotten EUS were due to poor patient compliance and either patient ignored or forgot the physician's advice about the timely removal of the ureteral stents; 30% of the cases failed to attend hospital for stent removal due to financial reasons, 12.5% of cases were due to delay in the endourological procedure following ESWL, and 10% of cases were due to poor communication between the doctor and the patient. The cost of removal of forgotten encrusted stents is 6.9 times higher than the cost of timely stent removal because of additional costs involved in multiple interventions and it affects patient safety and quality of life (5).

## METHODS

A retrospective analysis of 13 encrusted impacted ureteral stents in 12 patients treated in two hospitals between 2014 to 2021 was done. The inclusion criterion was failed ureteral stent removal by flexible cystoscopy under local anesthetic and clear evidence of stent encrustations on X-ray KUB (Kidney, Ureter, and Bladder) or Computed Tomogram Kidney Ureter and Bladder (CT-KUB). The primary outcome was successful removal of the encrusted impacted stent and the secondary outcome was the number and type of surgical procedures, operative time, hospi-

tal stay, perioperative complications, and stone and stent free rates. All patients had preoperative renal function tests, urine cultures, X-ray KUB, CT KUB and in selective cases a DMSA (*Dimercaptosuccinic acid*) renal radionuclide scan was done for patients with poor renal parenchyma.

The degree of encrustation was graded by the KUB score system based on imaging. Treatment was planned based on the degree and location of stent encrustation (KUB Score), renal function, presence of urinary tract infection, and other comorbid conditions. Appropriate antibiotics were administered prior to surgical intervention for positive urine cultures.

Initially, ESWL was given a maximum of 3 sittings for proximal coil encrustations < 15 mm. All invasive endourological procedures started with clearing the bladder end encrustation by mechanical cystolithopaxy by stone punch and some cases with LASER energy through the cystoscope. For the ureteral body encrustation, a 7.5 Fr semirigid ureteroscope was passed beside the encrusted stent from the ureteric orifice to work the way up towards the pelvicalyceal system using Holmium Laser energy for fragmentation. After clearing the ureteral body encrustation, a ureteral access sheath was placed and the proximal coil encrustation was cleared by a flexible ureteroscope (Storz Flex X2) and Holmium Laser. For denser and larger calcification of the proximal end, PCNL was done as a second sitting. Stent fragmentation occurred during the retrograde ureteroscopy and the pieces were left in the pyelocaliceal system which were later retrieved during PCNL or RIRS. For non-capacious ureter, additional (Tandem) stents were inserted followed by ureteroscopy in 2 weeks. No undue force was used to pull the encrusted stent during any of the above procedures. All patients had postprocedural ureteral stent insertion which was removed in 2 weeks. In all our patients we dealt with the bladder and ureteral body encrustation first before dealing with proximal end encrustation with RIRS or PCNL; only in a few patients ESWL was given first for mild to moderate proximal end encrustation.

The postoperative complications were graded according to the modified Clavien Dindo classification. All patients had postoperative X-ray KUB before discharge and follow-up non-contrast CT KUB and renal function in 4 months.

**Table 1.**  
*Demographic details.*

Variables	Total No.	Mean	Range
Encrusted stents/patients	13/12		
Males/females	11/1		
Age-years		61.15 ± 13.22	29 to 84
Side - right/left	7/6		
Stent indwelling time - months		15.07 ± 7.34	6 to 24
Stent indication			
Pre ESWL for renal stones	5		
Ureteric stones - colic	7		
Post ureteroscopy	1		
Reasons for delayed stent removal			
Forgotten	9		
Delay in the secondary procedure	4		
EGFR (ml/min)		61.07 ± 23.28	28 to 90
Urine culture (positive/no growth) patients	5/7		

**Table 2.**  
*Operative and postoperative details.*

Variables	No of pts.	Mean	Range
Encrustation grading - KUB score		11.84 ± 2.07	9 to 15
Total number of procedures per encrusted stent removal		3 ± 1.08	2 to 5
Total number of hospital Admissions per encrusted stent removal		1.76 ± 0.92	1 to 4
Total number of hospital stay per encrusted stent removal - days		2.69 ± 1.43	1 to 6
Total operative time per encrusted stent removal - minutes		249.61 ± 169.19 Median - 210 min	60 to 660
Post operative complications			
Clavien Dindo grade 1	6		
Clavien Dindo grade 2	3		
12 months Follow up - Patients			
Stone/stent free	8		
Recurrent stone	1		
Ureteric stricture	1		
Lost follow up	2		
Combination of procedures per stent removal			
Cystolithotripsy/URS/RIRS/ESWL	1 (7.6%)		
Cystolithotripsy/URS/ESWL	2 (15.3%)		
Cystolithotripsy/URS/PCNL	2 (15.3%)		
Cystolithotripsy/URS/RIRS	8 (61.5%)		

**RESULTS**

In our study 13, encrusted stents were removed from 12 patients with one patient with bilateral stents (Table 1). The average encrustation grading score at the proximal end (K) was 3.15 ± 1.62, at the stent body (U) was 4.3 ± 0.85 and at the distal end (B) was 4.38 ± 0.76. The average overall Arenas KUB score was 11.84 ± 2.07 (Table 2). In our study 3 patients with EUS had ESWL for the proximal end with poor results, and the majority of the stents were removed by cystolithoripsy, rigid URS, and RIRS, and two stents had PCNL for the proximal end (Figures 1-4). All the encrusted stents in our study were radio-opaque and 5 patients had a course of antibiotics for symptomatic UTIs with positive urine cultures prior to the procedure. The mean total number of procedures carried out was 3 ± 1.08 with a range of 2 to 5 per encrusted stent removal. All patients after the removal of the encrusted stent had post-operative ureteral stent which was removed with a flexible cystoscope within 14 days. The median operative time was 210 minutes with a range of 60 to 660 minutes and the mean hospital stay was 2.69 ± 1.43 days.

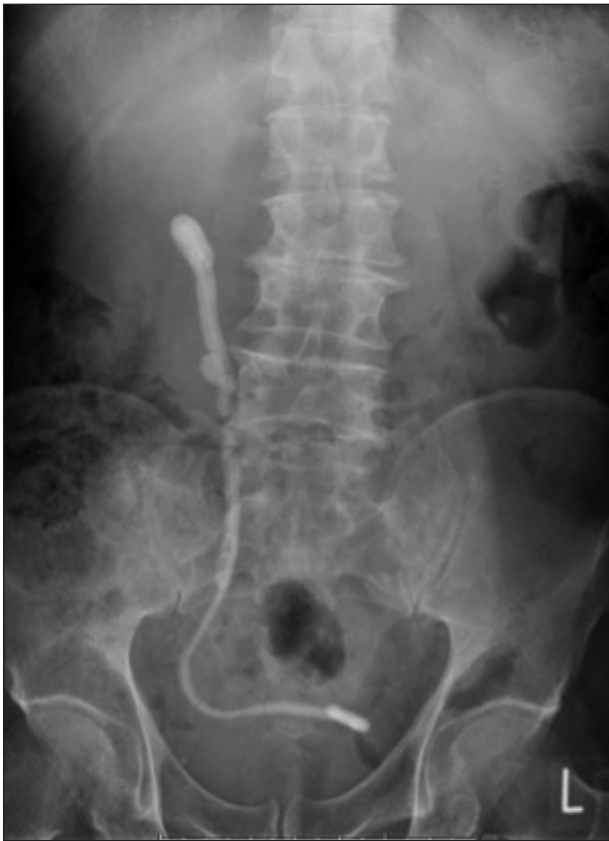No significant immediate postoperative complications were noted apart from mild haematuria in 6 and fever in 3 patients. Three patients had insignificant residual stone fragments (< 3 mm) treated conservatively. At 12 months of review, 8 patients were stone-free, 2 patients lost follow-up, 1 patient required repeated stenting of a renal unit due to pre-existing poor renal function and 1 patient developed significant ureteric stricture referred for reconstruction surgery.

**DISCUSSION**

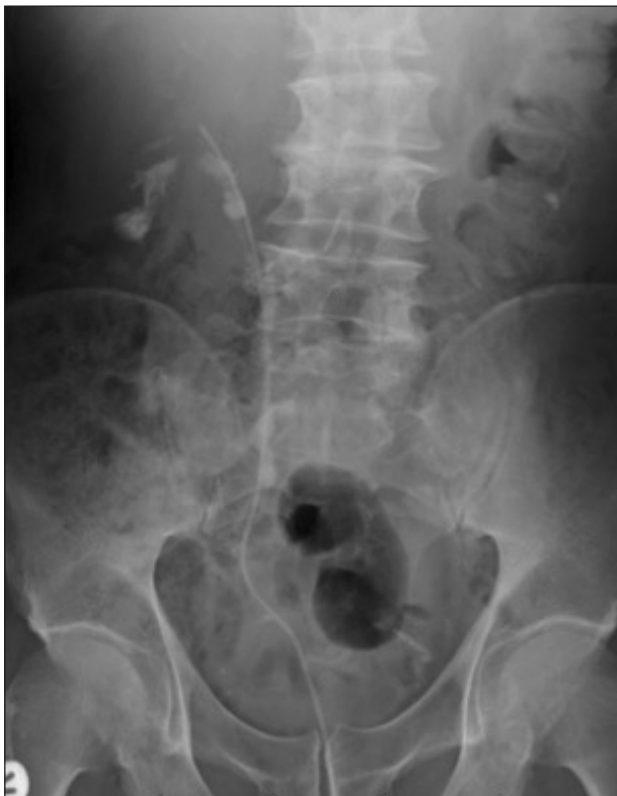*Risk factors and mechanism of encrustation*

Stent encrustation occurs when minerals from the urine

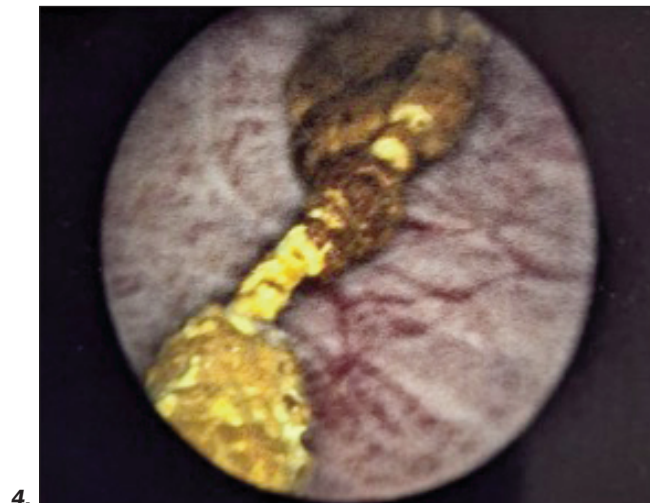
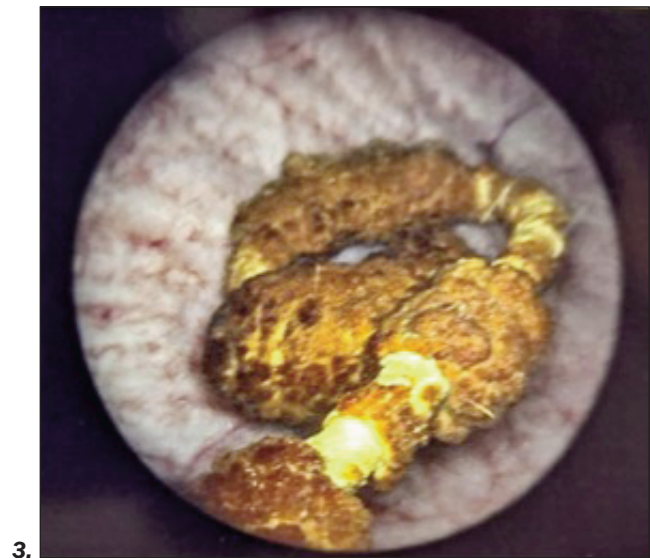
**Figure 1.**  
Xray KUB - Right whole ureteral stent encrustation.



**Figure 2.**  
X ray KUB - Fine fragmentation and removal of the encrusted stent with ureteric catheter in place.



**Figures 3, 4.**  
Endoscopic picture of lower end ureteral stent encrustation.



deposit on the outer and inner surface of the stent in both infected and non-infected urine environments. Various factors like stent material, bacterial colonization, and patient-specific factors influence stent encrustation but the main risk factor is the duration of stent indwelling time. *El-Faquith et al.* (6) in their study in 1991, reported stent encrustation rates of 9.2 % in 6 weeks, 47.5% between 6 to 12 weeks, and 76.3 % after 12 weeks of indwelling time. *Kawahara et al.* (7) reported similar encrustation rates of 27%, 57%, and 76% at equivalent time intervals; 30% of the stents removed before 12 weeks showed luminal encrustation but only 4% of the patients had clinical symptoms of stent obstruction (6). Bacterial colonization and bacterial biofilm play a critical role in stent encrustation but how it exactly triggers the encrustation process is poorly understood. *Tunney et al.* reported (8) that 90% of the removed ureteral stents had bacterial colonization and 55% had adherent biofilm. *Shabeena et al.* (9) reported 90% colonization rates in 120 days of ureteral stent insertion. *Escherichia coli*, *Streptococcus spp.*, and *Pseudomonas spp.* are commonly isolated but no specific pathogens have been attributed to

triggering encrustation. Newer studies on the urinary microbiome implicate that commensurate bacteria in urine rather than the pathogenic strains facilitate urolithiasis and stent encrustation (10).

Conditions like recurrent UTI, chronic kidney disease, and diabetes mellitus increase the urinary bacterial load or the presence of urolithiasis risk factors like specific diets, history of stone disease, malabsorption disorders, and cancer chemotherapy facilitate stent encrustation (11). Stent encrustation risk is high in pregnancy due to absorptive hypercalciuria and hyperuricosuria which require frequent stent changes in 4 to 6 weeks to avoid encrustation resulting in blocked stents. Urinary infection with urease-producing bacteria like *Pseudomonas*, *Proteus*, and *Klebsiella spp* hydrolyze urea into ammonia and carbon dioxide making urine alkaline and resulting in precipitation of ammonium, magnesium phosphate (struvite) on the stent surface.

The encrustation rates correlated with stent diameter rather than stent length or patency and a study (7) reported 6 F stent developed more encrustation than the 7 F stent. The mechanism of stent encrustation is complex and all stents after insertion are immediately coated with a conditioning film made of patient-specific glycoproteins and materials from the urinary composition. Further, the conditioning film may remain stable or could develop a bacterial biofilm that precipitates minerals on the stent surface causing stent encrustation; this provides a nidus for bacterial infection leading to urosepsis, obstruction, or renal failure (1, 12).

### Presentation and complications

The clinical presentation of the forgotten encrusted stent is variable. *Abdelaziz et al.* (13) reported that predominant symptoms of forgotten stents were storage bladder symptoms, haematuria; other symptoms such as gross haematuria, flank, urethral and suprapubic pain were minimal as these patients tolerated the stent-related symptoms for more than 6 months. The asymptomatic patients are more prone to neglect or forget the stent and therefore develop serious complications that are time-related, such as encrustation, fragmentation, and obstruction. In our study 80% of patients with encrusted stents presented with intermittent haematuria, recurrent urinary tract infection (UTIs), storage urinary symptoms, flank pain, and no symptoms in 20%.

### Challenges in the management of encrusted stents

Plain X-ray underestimates the stone burden and non-contrast computed tomography (CT) is essential for planning the treatment. The extent and location of encrustation, associated stone burden, renal function, and presence of urinary infection determine the treatment approach. Active urinary infection should be treated appropriately and urosepsis due to obstructed infected kidney may require an initial percutaneous nephrostomy to stabilize the patient before any intervention.

Nephrectomy may be considered if there is poor renal parenchyma with a split function < 20%.

*Arenas et al.* (14) developed a KUB grading system for encrusted ureteral stents. This system grades 1 to 5 according to the size of the calcification in or around the stent in the region of the *kidney* (K), *ureter* (U), *bladder*

(B), and the total score represented as the KUB score. They noted that the K score  $\geq 3$  was associated with multiple surgeries, multimodal surgery, operative time > 180 min, and lower stone-free rate, while the U score  $\geq 3$  was only associated with longer operative time and the B score  $\geq 3$  was associated with a lower stone-free rate. Overall KUB score  $\geq 9$  requires multiple surgeries, longer operative time and lower stone-free rates. Our study results agree with the finding that multiple endourological procedures are required for total KUB scores  $\geq 9$ .

The proximal stone burden is the main factor that determines the requirement of multiple surgeries and associated complications. In the presence of normal renal function, ESWL is indicated for mild to moderate encrustation of renal end and proximal ureteral body encrustation. The lower encrusted segment in the bladder and in the ureteral part was always released first before dealing with surgical removal of the proximal end (15) apart from giving ESWL for the proximal end of the encrusted stent. The bladder end and ureteral part of the encrusted stent were removed in pieces after releasing encrustation and cutting the stent with a Holmium LASER during URS, to create space for ureteral access sheath placement and RIRS to deal with the proximal coil encrustation. PCNL is reserved for complex proximal end encrustation and for cases of RIRS or ESWL failures. Open pyelolithotomy, cystolithotomy, or laparoscopic surgeries are sometimes required following the failure of endourological management.

The treatment described is used as a guideline and should be tailored according to the individual patient, clinical assessment, surgeon's experience, and available resources. The approach should be in a stepwise multimodal fashion to remove the encrusted stent and achieve stone and stent-free status with the preservation of renal function (16). Although majority of the encrusted ureteral stent need multimodal management, *Lio et al.* (17) in their case series described a minimally invasive technique under fluoroscopy of removing and replacing obstructed encrusted ureteral stents in female patients under local anaesthetic, however the obstructed ureteral stents removed with this technique had obstruction mainly caused by intraluminal incrustation.

*Monga et al.* (18) reported a series of 22 forgotten ureteral stents left in situ for over 6 months and found that 68% were calcified, 18% fragmented, and 14% fragmented and calcified. In their series, which included 22 forgotten and 9 migrated stents, procedures to render stent free were ureteroscopy 52%, PCNL 26%, ESWL 32%, cystolithotripsy 19%, open cystolithotomy 3%, simple nephrectomy 3% and multiple procedures were necessary in 19% of the patients.

In our study of 13 encrusted ureteral stents, 50% had significant proximal encrustation, and all of them had bladder end and ureteral body encrustation; 61.5% of EUS were removed by cystolithotripsy, URS and RIRS, 15.3% by cystolithotripsy, URS and ESWL, 15.3% by cystolithotripsy, URS and PCNL, 7.6% by cystolithotripsy, URS, RIRS, and ESWL. None of the encrusted stents were removed by open surgery in our study.

From our results, the average total number of procedures carried out was  $3 \pm 1.08$  with a range of 2 to 5 per EUS removal and the average time of hospital stays was  $2.69 \pm$

1.43 days with a range of 1 to 6 days per EUS removal. *Alnadhari et al.* (4) in their study reported a mean of 2.25 urologic procedures needed per EUS removal with a range of 1 to 10 procedures performed in a single or multiple anesthetic sessions.

Encrustation prevention: stent materials and technology: Stent biomaterials and coating substances could potentially alter bacterial adhesion thereby reducing bacterial colonization, bacterial biofilm formation, stent encrustation, and urosepsis. Silicone is a highly biocompatible material that resists encrustation and biofilm formation but is not commonly used because of low tensile strength, higher friction co-efficiency, and its softness prone to kinking and compression (8, 19). The majority of currently used ureteral stents are made of polyurethane-based material with copolymers because of their favorable mechanical properties and low manufacturing cost (20). *In vitro* study by *Tunney et al.* (8) compared encrustation rates of five different materials with an artificial solution similar to the urinary composition for 14 weeks. All developed some encrustation but silicone developed the least encrustation by 10 weeks followed by polyurethane, *Silitek*, *Percuflex*, and hydrogel coated polyurethane.

Stents coated with various materials could alter the stent surface to reduce bacterial adhesion and encrustation. Hydrogel-coated polyurethane stent swells on contact with water and retains water to alter the stent surface to reduce bacterial adhesion and encrustation along with reduction of friction coefficient for easier stent insertion (21). Drug coated stents with silver nitrate, and ofloxacin have not proved to reduce biofilm or encrustation in clinical trials, moreover antibiotic-infused stents have the potential risk of developing antibiotic resistance (22).

Coating with heparin, a naturally occurring glycosaminoglycan anticoagulant exhibits antiadhesive properties which could reduce bacterial adhesion and prevent bacterial biofilm formation and encrustation (23) but results from clinical trials are contradictory and heparin-coated stents are not regularly used in the clinical practice. Silicone-coated polyurethane stents, newer stent coating materials like bacteriolytic enzymes, peptides, oxalate degrading enzymes, and essential oils have been explored (24), and all aimed to alter bacterial adhesion, biofilm formation, and reduce stent encrustation and urosepsis.

Metallic ureteral stents made of alloy are used in malignant ureteric obstruction has provided superior patency rates at 12 months compared with polyurethane stents requiring less frequent stent changes but still, stent encrustations occurred macroscopically in 22% and microscopically in all after an indwelling time between 8 to 14 months (25).

Biodegradable ureteral stents by constantly altering the stent surface could prevent bacterial adhesion and encrustation and it also eliminates the need for stent removal. Currently available biodegradable materials made of natural or synthetic polymers have excellent biocompatibility with faster degradation which also reduces tissue inflammation useful in relieving the benign urinary obstruction. Prospective multicenter human trials are required before routine use in clinical practice (26). Similar to the prevention of urolithiasis, increased fluid intake and citrate supplements decreased the incidence of stent encrustation.

### Computerized stent registry

Even in current times, ureteral stent logbooks and tracking cards are maintained for monitoring however, human error and negligence are fundamental causes for the failure of these manual systems. *Monga* (27) reported that 10% of patients with forgotten stents fail to show up for scheduled stent retrieval despite being educated by physicians. Similarly, 8.66% of patients were aware that they had ureteral stents but did not attend for stent removal (28). Therefore patient education and awareness alone are not sufficient to prevent forgotten stents and related complications.

The treating doctor and the hospital are responsible for both the monitoring and removal of ureteral stents and multiple level safety precautions should be implemented for the timely removal or replacement of the stent. Computerized applications and electronic reminders appear to be reliable and efficient, and the utilization of automated algorithms has reduced the incidence of forgotten stents (28).

*Lin et al.* (28) retrospectively analyzed the monitoring of 12,440 ureteral stent placements in 10,105 patients registered on the *Auto registration monitoring system* (ARMS) an automated program closely tied with the hospital billing system in *Taipei Veterans General Hospital* over a period of 8 years. They reported 85.07% of patients who had their stents removed before the deadline were automatically detected. In the rest 14.93% of patients whose stents were not registered as removed it was found that 1.2% of patients had stents removed in other hospitals, 4.85% had died, 8.66% patients were aware of ureteral stents but did not come for stent removal and 0.21% of patients were not aware that they have ureteral stent which was placed in the operating room in non-urological patients. They reported that there were no new forgotten ureteral stents after the introduction of ARMS.

Development of a universally acceptable automated stent registry interface which could integrate with the existing hospital patient management system but also linked to the regional database would be ideal to monitor the ureteral stents after their insertion till their removal or replacement after the specific time interval.

The *Healthcare Safety Investigation Branch* (HSIB) from the UK published a report on the unplanned delayed removal of ureteric stents in October 2020 (29). The report showed the seriousness of the problem and made four safety recommendations including the development of a stone pathway, the use of a stent registry database, reviewing the *British Association of Urology surgeons* (BAUS) stent information leaflet, and clear communication with the general practitioner following patient discharge with stents.

### CONCLUSIONS

Avoidance of unnecessary stent insertion is the key to the prevention of stent-related complications. Patient education, judicious follow-up arrangements, computerized stent registry warning system could help in the timely removal of the stents, avoiding prolonged indwelling time which is the main risk factor for encrustation.

Removal of encrusted impacted stents requires a multi-

modal approach adding significant costs to the health care system and more importantly affecting patient safety and quality of life. Ureteral stent technology is continuously evolving and current research should focus on developing biocompatible materials, newer coating substances, surface engineering, and stent design to reduce stent-related symptoms and complications.

#### ACKNOWLEDGEMENT

We thank Dr Arundoss Gangadharan, Consultant Paediatrician, who helped in organizing the references in this article.

#### REFERENCES

1. Lange D, Bidnur S, Hoag N, Chew BH. Ureteral stent-associated complications-where we are and where we are going. *Nat Rev Urol*. 2015; 12:17-25.
2. Divakaruni N, Palmer CJ, Tek P, et al. Forgotten ureteral stents: who's at risk? *J Endourol*. 2013; 27:1051-4.
3. Osman N, Collins G. Urological litigation in the UK National Health Service (NHS): an analysis of 14 years of successful claims. *BJU international* 2011; 108:162-5.
4. Alnadhari I, Alwan M, Salah M, Ghilan A. Treatment of retained encrusted ureteral Double-J stent. *Arch Ital Urol Androl* 2019; 90:265-269.
5. Sancaktutar A, H HS, Bozkurt Y, Penbegül N, Atar M. Treatment of forgotten ureteral stents: how much does it really cost? A cost-effectiveness study in 27 patients. *Urol Res*. 2012; 40:317-25.
6. el-Faqih SR, Shamsuddin AB, Chakrabarti A, et al. Polyurethane internal ureteral stents in treatment of stone patients: morbidity related to indwelling times. *J Urol* 1991; 146:1487-91.
7. Kawahara T, Ito H, Terao H, et al. Ureteral stent encrustation, incrustation, and coloring: morbidity related to indwelling times. *J Endourol*. 2012; 26:178-82.
8. Tunney MM, Keane PF, Jones DS, Gorman SP. Comparative assessment of ureteral stent biomaterial encrustation. *Biomaterials*. 1996; 17:1541-6.
9. Shabeena KS, Bhargava R, Manzoor MAP, Mujeeburahiman M. Characteristics of bacterial colonization after indwelling double-J ureteral stents for different time duration. *Urol Ann*. 2018; 10:71-75.
10. Zampini A, Nguyen A, Rose E, et al. Defining dysbiosis in patients with urolithiasis. *Sci Rep*. 2019; 9:5425.
11. Beysens M, Tailly TO. Ureteral stents in urolithiasis. *Asian J Urol*. 2018; 5:274-286.
12. Tomer N, Garden E, Small A, Palese M. Ureteral stent encrustation: epidemiology, pathophysiology, management and current technology. *J Urol*. 2021; 205:68-77.
13. Abdelaziz AY WBF, Mosharafa AA, Abelasoul MA, et al. Forgotten ureteral stents: Risk factors, complications and management. *African Journal of Urology*. 2018; 24:28-33.
14. Arenas JL, Shen JK, Keheila M, et al. Kidney, Ureter, and Bladder (KUB): A novel grading system for encrusted ureteral stents. *Urology*. 2016; 97:51-55.
15. Lam J, Gupta M. Tips and tricks for the management of retained ureteral stents. *J Endourol*. 2002; 16:733-41.
16. Bultitude MF, Tiptaft RC, Glass JM, Dasgupta P. Management of encrusted ureteral stents impacted in upper tract. *Urology*. 2003; 62:622-6.
17. De Rose AF, Di Grazia E, Magnano San Lio V, et al. Complications of endourological procedures and their treatment. *Arch Ital Urol Androl*. 2020; 92:321-325.
18. Monga M, Klein E, Castañeda-Zúñiga W, Thomas R. The forgotten indwelling ureteral stent: a urological dilemma. *J Urol*. 1995; 153:1817-9.
19. Barghouthy Y, Wiseman O, Ventimiglia E, et al. Silicone-hydro-coated ureteral stents encrustation and biofilm formation after 3-week dwell time: results of a prospective randomized multicenter clinical study. *World J Urol*. 2021; 39:3623-3629.
20. Venkatesan N, Shroff S, Jayachandran K, Doble M. Polymers as ureteral stents. *J Endourol*. 2010; 24:191-8.
21. Ahmed E. Hydrogel: Preparation, characterization, and applications: A review. *J Adv Res*. 2015; 6:105-21.
22. Singha P, Locklin J, Handa H. A review of the recent advances in antimicrobial coatings for urinary catheters. *Acta Biomater*. 2017; 50:20-40.
23. Al-Aown A, Kyriazis I, Kallidonis P, et al. Ureteral stents: new ideas, new designs. *Ther Adv Urol*. 2010; 2:85-92.
24. Glinel K, Thebault P, Humblot V, Pradier C, Tjouenne. Antibacterial surfaces developed from bio-inspired approaches. *Acta Biomater*. 2012; 8:1670-84.
25. Kallidonis P, Georgiopoulos I, Kyriazis I, et al. The full metallic double-pigtail ureteral stent: Review of the clinical outcome and current status. *Indian J Urol*. 2015; 31:8-14.
26. Janssen P, Tailly T. New stent technologies. *Urol Clin North Am*. 2022; 49:185-196.
27. Monga M. The dwell time of indwelling ureteral stents--the clock is ticking but when should we set the alarm? *J Urol*. 2011; 185:387.
28. Lin K, Chen P, Fan Y, Huang W. Preventing forgotten double J ureteral stents in a high-volume service medical center: An autoregistration monitoring system. *J Chin Med Assoc*. 2020; 83:382-385.
29. Branch HsI. Unplanned delayed removal of ureteric stent. Healthcare safety Investigation Branch. <https://www.hsib.org.uk/investigations-and-reports/unplanned-delayed-removal-of-ureteric-stents/>

#### Correspondence

Mohanaragam Thangavelu, MBBS, FEBU, FRCS (Urology) (Corresponding Author)  
drtmohan@hotmail.com  
Consultant Urology, Betsi Cadwaladr University Health Board  
Ysbyty Gwynedd, Bangor, LL57 2PW, United Kingdom

Mohamed Yehia Abdallah, MD, FRCS (Urology)  
Mohamed.yehia@wales.nhs.uk  
Olubenga John Isola, MD  
gbenga.isola@yahoo.co.uk  
Department of Urology, Wrexham Maelor Hospital, Wrexham, LL13 7TD, United Kingdom

Ahmed Kotb, MD  
drahmedfali@gmail.com  
Northern Ontario School of Medicine, TBRHSC, 980 Oliver Road,  
Thunder Bay, Ontario, Canada. P7B 6V4