

# One step nucleic acid amplification (OSNA) for detection of lymph node metastasis during robotic radical prostatectomy for prostate cancer: A pilot study

Omer Burak Argun<sup>1</sup>, Panagiotis Mourmouris<sup>2</sup>, Yesim Saglican<sup>3</sup>, Tunkut Doganca<sup>4</sup>, Mustafa Bilal Tuna<sup>5</sup>, Cavit Kerem Kayhan<sup>6</sup>, Ozge Yalcinkaya<sup>6</sup>, Ilter Tufek<sup>1</sup>, Halil Kara<sup>7</sup>, Can Obek<sup>1</sup>, Umit Ince<sup>3</sup>, Lazaros Tzelves<sup>2</sup>, Andreas Skolarikos<sup>2</sup>, Ali Rıza Kural<sup>1</sup>

<sup>1</sup> Acibadem Mehmet Ali Aydinlar University, School of Medicine, Department of Urology, Istanbul, Turkey;

<sup>2</sup> National and Kapodistrian University of Athens, Sismanogleio General Hospital, 2nd Department of Urology, Athens, Greece;

<sup>3</sup> Acibadem Mehmet Ali Aydinlar University, School of Medicine, Department of Pathology, Istanbul, Turkey;

<sup>4</sup> Acibadem Taksim Hospital, Department of Urology, Istanbul, Turkey;

<sup>5</sup> Acibadem Maslak Hospital, Department of Urology, Istanbul, Turkey;

<sup>6</sup> Acibadem Maslak Hospital, Department of Pathology, Istanbul, Turkey;

<sup>7</sup> Acibadem Maslak Hospital, Department of General Surgery, Istanbul, Turkey.

## Summary

**Introduction:** The OSNA technique is based on reverse transcription loop-mediated DNA amplification for the detection of cytokeratin 19 (CK19) messenger RNA (mRNA). The purpose of our paper, which represents the first study in the literature, is to test the accuracy of this method in the detection of lymph node metastases in patients undergoing robotic radical prostatectomy with lymph node dissection.

**Methods:** Our cohort consisted of patients that have undergone robotic radical prostatectomy with extended lymph node dissection. Lymph nodes were evaluated with imprint technique and then with frozen section examination. The remaining tissue was evaluated by OSNA method. Lymph nodes were defined as 'negative' or 'positive' according to mRNA copy number.

**Results:** 7 patients and 25 lymph nodes were included in our cohort. Two patients were found negative with all pathology methods. In one patient the standard stains revealed a suspicious outcome but it was positive for micrometastasis with OSNA. In another patient the outcome was positive for standard stains and negative for OSNA. Finally, 2 patients were found positive for OSNA and negative for imprint methods.

**Conclusions:** One Step Nucleic Acid Amplification (OSNA) method using CK19 seems to fail in detection of lymph node metastases in prostate cancer patients undergoing radical prostatectomy and lymph node dissection.

**KEY WORDS:** Prostate cancer; Metastases; Lymph nodes; One step nucleic acid amplification.

Submitted 24 January 2022; Accepted 2 March 2022

## INTRODUCTION

Pelvic lymph node metastasis is associated with poor prognosis and upstages prostatic carcinoma. Pelvic lymph node dissection (PLND) is currently the most accurate lymph node (LN) staging procedure for prostate cancer (PCa). None of the available radiologic imaging modalities provides an equivalent sensitivity for the detection of

LN involvement. The sensitivity of abdominal computed tomography (CT) and multiparametric magnetic resonance imaging (mpMRI) for lymph node metastasis is less than 40% according to a recent study (1).

In addition, nuclear medicine-based imaging modalities (11C- or 18F- choline- and 68Ga-PSMA), PET-CT for initial staging of prostate cancer may provide low sensitivity (49-66%) in detection of LN metastases (1, 2).

Today, the gold-standard evaluation of lymph node metastasis remains multistep analysis of the lymph nodes via hematoxylin-eosin stained sections, combined with immunohistochemistry for cytokeratin expression. However, there is no standardized assessment method for nodal status in prostate cancer. Histopathologic evaluation of lymph nodes varies between laboratories. Intraoperative frozen section (FS) assessment of pelvic lymph nodes (PLNs) is being used not so often, but for some triage patients. Additionally, the role of FS in identifying small metastases and influencing the completion of the RP can be queried.

The routine FS of PLNs has been questioned by several studies (3, 4). There are studies, which report a wide range of sensitivity for FS of PLNs, between 33% to 77% (5). If the metastasis is small and not visible on macroscopic evaluation, freezing and cryostat section may waste the tissue, which is very important during permanent embedding. Regarding technical details, fatty lymph nodes are not good candidates for frozen section analysis as microscopic metastasis can be lost during defatting process. All these shortcomings of the pathological evaluation of the lymph nodes brought out different technologies like Polymerase Chain Reaction (PCR) based techniques.

PCR-based techniques such as one-step nucleic acid amplification (OSNA) assay are viable alternatives. The OSNA technique for pathological evaluation of lymph node is based on reverse transcription loop-mediated DNA amplification for the detection of cytokeratin 19 (CK19)

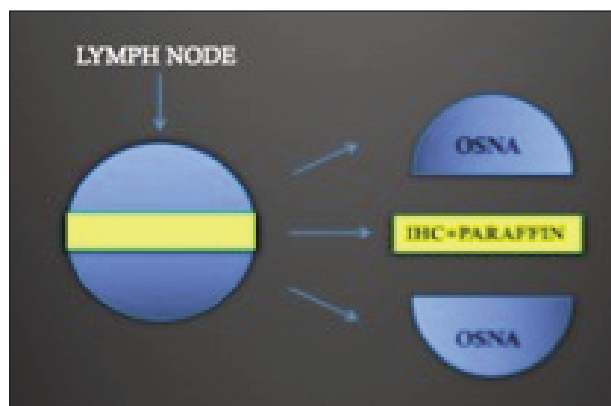
messenger RNA (mRNA). The idea behind this relatively novel study with micromolecular histopathologic technique is detection of CK 19 in lymphatic tissue due to prostate cancer metastasis, which is normally not expressed. Our goal was to evaluate the use of the OSNA method to detect cancer metastasis in entire lymph node in comparison with conventional methods in prostate cancer patients who underwent robotic radical prostatectomy and lymph node dissection.

**MATERIAL AND METHODS**

Our cohort consisted of patients that have been diagnosed with intermediate and high-risk prostate cancer and who have undergone robotic radical prostatectomy with extended lymph node dissection. Institutional Review Board approval was taken from ethical committee. Informed and written consent was obtained from all patients. Lymph node template included caudally, femoral canal; medially, the side wall of the bladder; laterally, up to the genitofemoral nerve; posteriorly, the obturator muscle and floor of the obturator fossa down to the internal iliac vessels; cranially, the common iliac region where the ureter crosses the common iliac artery and aortic bifurcation up to the inferior mesenteric artery. Patients with previous and/or additional malignancies and with a history of pelvic radiotherapy were excluded from the study. A summary of patient and tumor characteristics is shown in Table 1.

Suspicious lymph node regions were defined pre-operatively with the use of imaging methods such as *prostate specific membrane antigen positron emission tomography* (PSMA-PET) or *Magnetic Resonance Imaging* (MRI). Following the completion of the lymph node dissection, the suspicious lymphatic tissue samples were removed through the assistant port site inside an organ bag. Lymphatic tissues were sent to the pathology department immediately and dissected out from the fatty tissue. Care has been taken to perform lymph node dissection before the prostatectomy, as this could potentially contaminate the lymph node tissues with CK19 positive tissues. Following step was cutting the suspected lymph node through the sagittal plane. Each plane (facing each other) was evaluated with imprint technique and then with frozen section examination. Touch imprint cytology was carried out by gently touching the fresh tissue on a clean glass slide and fixing immediately imprints in 95% ethyl

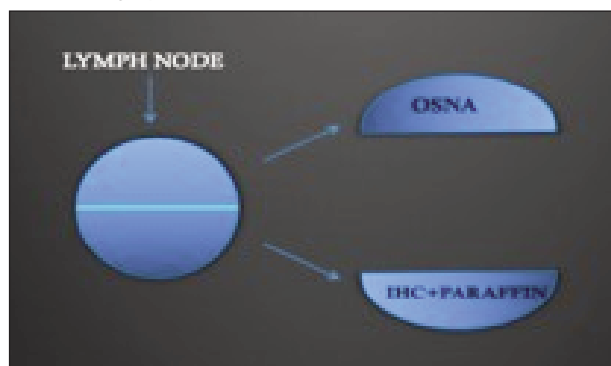
**Figure 1.**  
Process of lymph nodes larger than 5 mm.



alcohol and staining with *hematoxylin and eosin* (H&E) stains. Frozen section study was performed by processing tissue in cryostat at -10°C to -15°C and cutting thin sections of 3-5 µm thickness and staining using H&E. If the lymph nodes were large enough (> 5 mm in diameter), a segment of approximately 2-3 mm from the middle of the lymph node was removed and stored for paraffin sampling and *immunohistochemistry* (IHC) evaluation as stated in the consent form (Figure 1). The remaining tissue was evaluated by OSNA method or stored at minus 18°C if OSNA procedure was not possible at the time of operation. In case of a small lymph node (< 5 mm), cutting was performed in two pieces and used one piece of it (Figure 2), whereas the second one was examined with H&E staining and paraffin sampling which were golden standard for post-operative evaluation.

The fresh sections stored for OSNA evaluation were transformed to a homogenized dilution with the use of a 4 ml of lysing buffer (*Lynorhag, Sysmex, Kobe, Japan*) for 90 seconds and then the latter was centrifuged for one minute at 10,000 G. Next, CK19 and beta-actin mRNA were amplified by *Reverse Transcription Loop-Mediated Amplification* (RT-LAMP) in the RD-100i (*Lynoamp, Sysmex, Kobe*). The use of the dedicated kit provided by the manufacturer (*Lynoamp, Sysmex, Kobe*) allowed the start of the automated procedure that was performed without the need of RNA purification. LNs were defined

**Figure 2.**  
Process of lymph nodes smaller than 5 mm.



**Table 1.**  
*Pre and perioperative characteristics of patients.*

Patient	Age	PSA	Pre-op GS	Clinical stage	Post-op GS	Pathology stage	Surgical margins
1	60	7,5	3+4	cT2b	3+4	pT2c	Negative
2	68	8	4+5	cT3	4+5	pT3b	Negative
3	69	8,5	4+4	cT3	3+4	pT3a	Negative
4	64	15	4+4	cT2c	4+4	pT2c	Negative
5	73	5,2	4+5	cT3	5+4	pT3b	Negative
6	68	20	4+4	cT3	4+4	pT3b	Negative
7	68	8	4+3	cT2c	5+4	pT3b	Negative

PSA: Prostate specific antigen; GS: Gleason Score.

as 'negative' or 'positive' according to mRNA copy number. CK 19 mRNA copies/mL less than 250 were defined as negative (-), 250-5000 were defined as positive for micrometastases and copies exceeding 5000 were defined as positive for macrometastases, according to manufacturer's manual

## RESULTS

7 patients and 25 lymph nodes were included in our cohort. In the first and second patients, 2 and 4 lymph nodes were used for analysis from the harvested lymphatic tissue. In all cases OSNA was performed intraoperatively except one that due to device failure was performed postoperatively. They were all negative for imprint analysis, frozen section (H&E) staining and OSNA. In third patient 5 lymph nodes from different areas were selected according to the aforementioned criteria and one of them was suspicious in imprint analysis but also it was positive for micrometastasis in OSNA evaluation. In fourth patient, there was micrometastasis in imprint analysis and H&E staining but negative for OSNA and frozen section analysis. In fifth patient, even though OSNA was positive for micrometastasis, imprint analysis and frozen section +(H&E) staining failed to confirm it. In sixth patient, 4 lymph nodes were harvested and in one of them OSNA was positive even though the imprint and frozen section analysis were negative. In seventh patient, we harvested 5 lymph nodes and 3 of them were found to be positive for macrometastasis but negative for OSNA (Table 2). In this cohort of lymph nodes, OSNA method was discordant for evaluation of metastatic lymph node status.

**Table 2.**  
Results of lymph nodes analysis of patients.

Patient	Lymph node location	Imprint+ H&E staining	Frozen+ H&E staining	OSNA	
1	Right common iliac	0	0	0	Negative
	Right external iliac	0	0	0	Negative
2	Right obturator	0	0	0	Negative
	Left obturator	0	0	0	Negative
	Pre-sacral	0	0	0	Negative
	Right external iliac	0	0	0	Negative
3	Left common iliac	0	0	0	Negative
	Left external iliac	0	0	0	Negative
	Right common iliac	S	0	1	1100 copies
	Left obturator	0	0	0	Negative
	Right external iliac	0	0	0	Negative
4	Right obturator	0	1	0	Negative
5	Right obturator	0	0	1	400 copies
	Left obturator	0	0	0	Negative
	Right common iliac	0	0	0	Negative
6	Right obturator	0	0	1	400 copies
	Left obturator	0	0	0	Negative
	Left external iliac	0	0	0	Negative
	Left common iliac	0	0	0	Negative
7	Right obturator+external iliac	1	S	0	Negative
	Right obturator+external iliac	0	0	0	Negative
	Left obturator+external iliac	1	1	0	Negative
	Left obturator+external iliac	1	1	0	Negative
	Left common iliac	0	0	0	Negative

0 = Negative; 1 = Positive; S = Inconclusive.

## DISCUSSION

Today, hematoxylin-eosin staining and immunohistochemical methods are used in the detection of lymph node metastases of prostate cancer. Because of the technical difficulties and also the nature of the sampling method, identification of cancerous cells in the entire lymph node is not feasible and metastasis status is reported by random sampling of the lymph tissues (1). The single-step nucleic acid amplification (OSNA) method, has proven its value in the sentinel lymph node sampling of breast cancer (2). Meanwhile its use in other malignancies (colorectal, head and neck, gynecological, lung, thyroid, gastric) has yielded promising outcomes (5-10). Its use can be expanded to intraoperative identification of positive lymph nodes that may potentially alter the course of the procedure in the future (11). As well there are even studies in the literature implying that the OSNA method can potentially gain the first place as a standard for pathological examination of lymph node infiltration (12).

The presence of lymph node metastasis in patients with prostate cancer can significantly alter the management and the prognosis of the disease. Lymph node status remains a significant prognostic factor and an important part of the decision-making process regarding adjuvant treatment for prostate cancer patients.

Our study represents the first study that tests the potential role of the OSNA method in diagnosing lymph node infiltration in patients with prostate cancer.

The OSNA system (Sysmex Corporation, Kobe, Japan), combines reverse transcription (RT) with isothermal loop-mediated DNA amplification (RT-LAMP) for detection of CK19 messenger RNA (mRNA) as a marker of cancerous cells since CK19 mRNA in the glandular epithelial cells should not normally be present in the lymph nodes (13). When compared to other techniques for intraoperative evaluation of sentinel node metastases in breast cancer, outcomes of OSNA technique are relatively controversial. There are studies that report a clear advantage of the more popular *imprints cytology* (IC) with a calculated accuracy of 96.12% (14), whereas in other studies the OSNA method is found to be equally reliable (detection rates 11.8 vs 12.1%) when compared to other techniques such as *cytokeratin immunohistochemistry* (CK-IHC) (15). When cost is concerned there is limited data in the literature and mostly achieved from studies for breast cancer.

The hypothesis was that with a reliable intra-operative diagnostic tool, the patients would be spared from a second procedure in order to excise the remaining lymph nodes that could be potentially infiltrated. The data, even though controversial, imply that OSNA method is not cost effective for the intraoperative diagnosis of sentinel lymph node metastases despite its accuracy that reaches almost 91% (16). However, Guillén-Paredes MP *et al.* in patients with breast cancer metastases, report reduced hospital stay and operating time with OSNA method resulting in a saving of 439.67 € per patient, but their study is a retrospective with a low number of patients, so their results must be interpreted with caution (17). Prostate cancer patients can potentially survive for more than 15 years and most of them will be receiving some kind of treatment. Hence cost analysis of this method for prostate cancer can potentially yield different outcomes

compared to breast cancer. No data exist in the literature concerning the use of OSNA method in detecting possible positive lymph nodes in prostate cancer patients. The only one available in the literature reports preliminary results of this method in prostatectomy specimens and not in lymph nodes (18). This study implicates CK19 as a potential marker for prostate cancer specimens and presents some promising results. Nevertheless, based on our results CK19 doesn't seem to yield satisfactory results as far as lymph nodes metastasis is concerned.

Furthermore, the true clinical impact of this method (if any), lies in positive lymph node detection since the methods for detecting prostate cancer in prostate glands are already completely satisfying something that does not imply for lymph nodes.

Our study is a pilot study and so it cannot avoid several limitations. First of all the number of patients is very small and the number of lymph nodes tested.

Nevertheless, this is the first study to test the potential role of OSNA in lymph nodes metastases for prostate cancer and also the number of patients with positive lymph nodes in radical prostatectomy series is relatively small. Finally, our study did not test either cost or potential survival benefit for patients that were found to be positive with the OSNA method. The purpose of our paper was to study the potential role of a novel detection method (OSNA), already used in other malignancies, in prostate cancer. Future well-designed studies are needed to confirm if these methods can increase the detection rate of lymph node metastases and provide any survival benefit for the patients.

## CONCLUSIONS

OSNA method using CK19 was not sufficient to demonstrate lymph node metastases in prostate cancer patients undergoing radical prostatectomy and lymph node dissection compared to golden standards.

## REFERENCES

1. Kryvenko ON, Epstein JI. Histologic criteria and pitfalls in the diagnosis of lymphovascular invasion in radical prostatectomy specimens. *Am J Surg Pathol.* 2012; 36:1865-73.
2. Shi F, Liang Z, Zhang Q, et al. The performance of one-step nucleic acid amplification assay for intraoperative detection of sentinel lymph node macrometastasis in breast cancer: An updated meta-analysis. *Breast.* 2018; 39:39-45.
3. Young MP, Kirby RS, O'Donoghue EP, Parkinson MC. Accuracy and cost of intraoperative lymph node frozen sections at radical prostatectomy. *J Clin Pathol.* 1999; 52: 925-7.
4. Kakehi Y, Kamoto T, Okuno H, et al. Per-operative frozen section examination of pelvic nodes is unnecessary for the majority of clinically localized prostate cancers in the prostate-specific antigen era. *Int J Urol.* 2000; 7:281-6.
5. Wild JB, Iqbal N, Francombe J, et al. Is it time for one-step nucleic acid amplification (OSNA) in colorectal cancer? A systematic review and meta-analysis. *Tech Coloproctol.* 2017; 21:693-699.
6. Zhou M, Wang X, Jiang L, et al. The diagnostic value of one step nucleic acid amplification (OSNA) in differentiating lymph node

metastasis of tumors: A systematic review and meta-analysis. *Int J Surg.* 2018; 56:49-56

7. Fanfani F, Monterossi G, Ghizzoni V, et al. One-Step Nucleic Acid Amplification (OSNA): A fast molecular test based on CK19 mRNA concentration for assessment of lymph-nodes metastases in early stage endometrial cancer. *PLoS One.* 2018; 13:e0195877.

8. Nakagawa K, Asamura H, Tsuta K, et al. The novel one-step nucleic acid amplification (OSNA) assay for the diagnosis of lymph node metastasis in patients with non-small cell lung cancer (NSCLC): Results of a multicenter prospective study. *Lung Cancer.* 2016; 97:1-7.

9. González O, Iglesias C, Zafon C, et al. Detection of thyroid papillary carcinoma lymph node metastases using One Step Nucleic Acid Amplification (OSNA): preliminary results. *J Invest Surg.* 2015; 28:153-9.

10. Nakabayashi K, Uraoka T, Shibuya M, et al. Rapid detection of CEA mRNA in peritoneal washes using One-Step Nucleic acid Amplification (OSNA) for gastric cancer patients. *Clin Chim Acta.* 2015; 439:137-42.

11. Yeung TM, Wang LM, Colling R, et al. Intraoperative identification and analysis of lymph nodes at laparoscopic colorectal cancer surgery using fluorescence imaging combined with rapid OSNA pathological assessment. *Surg Endosc.* 2018; 32:1073-1076.

12. Tamaki Y. One-step nucleic acid amplification (OSNA): where do we go with it? *Int J Clin Oncol.* 2017; 22:3-10.

13. Tsujimoto M, Nakabayashi K, Yoshidome K, et al. Onestep nucleic acid amplification (OSNA) for intraoperative detection of lymph node metastasis in breast cancer patients. *Clin Cancer Res* 2007; 13:4808-4816.

14. Luna-Tomás MA, Solà-Suárez M, Mariscal-Martínez A, et al. Is OSNA better than imprint cytology for intraoperative diagnosis of cancer involvement of axillary sentinel node in breast cancer? *Breast.* 2018; 38:181-187.

15. Shigematsu H, Ozaki S, Yasui D, et al. Comparison of CK-IHC assay on serial frozen sections, the OSNA assay, and in combination for intraoperative evaluation of SLN metastases in breast cancer. *Breast Cancer.* 2018; 25:191-197.

16. Huxley N, Jones-Hughes T, Coelho H, et al. A systematic review and economic evaluation of intraoperative tests [RD-100i one-step nucleic acid amplification (OSNA) system and Metasin test] for detecting sentinel lymph node metastases in breast cancer. *Health Technol Assess.* 2015; 19:v-xxv, 1-215.

17. Guillén-Paredes MP1, Carrasco-González L, Chaves-Benito A, et al. One-step nucleic acid amplification (OSNA) assay for sentinel lymph node metastases as an alternative to conventional postoperative histology in breast cancer: cost-benefit analysis. *Cir Esp.* 2011; 89:456-62.

18. Winter A, Engels S, Goos P, et al. Detection of CK19 mRNA Using One-step Nucleic Acid Amplification (OSNA) in Prostate Cancer: Preliminary Results. *J Cancer.* 2018; 9:4611-4617.

## Correspondence

Omer Burak Argun, MD, Associate Professor of Urology  
drburakargun@gmail.com

Ilter Tufek, MD, Professor of Urology  
iltertuf@gmail.com

Ali Rıza Kural, MD, Professor of Urology  
arkural@gmail.com

Acibadem Mehmet Ali Aydınlar University, School of Medicine,  
Department of Urology  
Buyukdere Cad 40 Maslak 34457 Istanbul (Turkey)

*Panagiotis Mourmouris, MD, Urologist (Corresponding Author)*

thodoros13@yahoo.com

National and Kapodistrian University of Athens, Sismanogleio General Hospital,  
2<sup>nd</sup> Department of Urology  
Sismanogliou 37, Marousi 151 26 (Greece)

*Yesim Saglican, MD, Associate Professor of Pathology*

yesim.saglican@acibadem.com.tr

*Umit Ince, MD, Professor of Pathology*

umit.ince@acibadem.com

Acibadem Mehmet Ali Aydinlar University, School of Medicine, Department of Pathology  
Buyukdere Cad 40 Maslak 34457 Istanbul (Turkey)

*Tunkut Doganca, MD, Urologist*

tunkutdoganca@gmail.com

Acibadem Taksim Hospital, Department of Urology  
Inonu Mahallesi, Nizamiye Cd. No:9, 34373 Sisli, Istanbul (Turkey)

*Mustafa Bilal Tuna, MD, Urologist*

mustafabilaltuna@gmail.com

*Cavit Kerem Kayhan, Biologist*

cavit.kerem.kayhan@acibadem.com

Acibadem Maslak Hospital, Department of Pathology  
Buyukdere Cad 40 Maslak 34457 Istanbul (Turkey)

*Ozge Yalcinkaya, Pathology Technician*

ozge.yalcinkaya@acibadem.com

*Halil Kara, MD, General Surgeon*

halil.kara@acibadem.com

Acibadem Maslak Hospital, Department of General Surgery  
Buyukdere Cad 40 Maslak 34457 Istanbul (Turkey)

*Can Obek, MD, Professor of Urology*

canobek@yahoo.com

*Lazaros Tzelvels, MD, Urologist*

lazarostzelvels@gmail.com

*Andreas Skolarikos, MD, PhD, Professor of Urology*

andskol@yahoo.com

2<sup>nd</sup> Department of Urology, National and Kapodistrian University of Athens,  
Sismanogleio General Hospital, Sismanogliou 37, Marousi 151 26 (Greece)