

# Antegrade placement of JJ catheter in the treatment of malignant ureteral obstruction: Retrospective analysis of a single centre

Eser Ordek<sup>1</sup>, Mehmet Kolu<sup>2</sup>, Mehmet Demir<sup>3</sup>, Bulent Kati<sup>3</sup>, Eyyup Sabri Pelit<sup>3</sup>, Ismail Yagmur<sup>3</sup>

<sup>1</sup> Kahta State Hospital, Urology Department, Adiyaman/Turkey;

<sup>2</sup> Harran University, Faculty of Medicine, Radiology Department, Sanliurfa, Turkey;

<sup>3</sup> Harran University, Faculty of Medicine, Urology Department, Sanliurfa, Turkey.

**Summary** *Objective: The aim of the present study was to examine the results of antegrade JJ stent placement in upper urinary tract obstruction in patients where retrograde placement was not possible.*

*Methods: In this retrospective study, patients who underwent antegrade JJ stent placement for malignant ureteral obstruction in the urology clinic of a university hospital between January 1, 2018 and December 31, 2020 were included in the study.*

*JJ stent was placed under local or general anaesthesia guided by ultrasonography and fluoroscopy. Age, gender, kidney function values, pathologies causing obstruction, and complications of the patients were examined.*

*Results: In this study, 40 patients (16 men, 24 women) who underwent antegrade JJ stent placement were included. The mean ages of the women and men included were 51 (31-91) years and 62.5 (26-81) years, respectively. In all, antegrade JJ stenting was performed in 61 renal units of these patients.*

*Of these, 21 were bilateral, 11 in the right collecting system and 8 in the left collecting systems. Clinical and technical success was achieved in 59 of the 61 procedures (96.6%). Arteriovenous fistula developed in only one patient, whereas no serious complications such as massive bleeding, resistant hematuria or pseudoaneurysm occurred in the remaining patients. The procedure was completed in a mean time of 15-30 minutes.*

*Conclusions: Antegrade JJ stent placement is a procedure with a high success rate and low risk of complications that can be used in patients with severe ureteral obstruction owing to malignant or benign aetiologies. This method should be applied in centres experienced in malignant ureteral obstruction and on patients where retrograde placement was not possible. Furthermore, it should be considered as an alternative treatment option to open surgery as it can be performed under local anaesthesia in patients at a high risk of anaesthesia.*

**KEY WORDS:** Malignant ureteral obstruction; Obstructive uropathy; Genitourinary neoplasms; Antegrade JJ stenting.

Submitted 9 March 2022; Accepted 16 March 2022

## INTRODUCTION

Ureteral stents were first developed by Zimskind *et al.* (1) in 1967 and have since been used in the treatment of ureteral obstruction or various urogenital fistulas. Over time, indications of the use of ureteral stents have

expanded significantly (2). Today, they are almost considered a standard and indispensable urological tool.

Ureteral obstruction is a complex and heterogeneous clinical condition therefore determining the ideal decompression method can be challenging for urologists. These obstructions may develop owing to malignant or benign aetiologies. Malignancy that leads to this type of complex obstruction may originate from organs external to the urinary system as colorectal or gynaecological tumors or from organs internal to urinary system such as bladder and prostate cancers (3) (Figure 1).

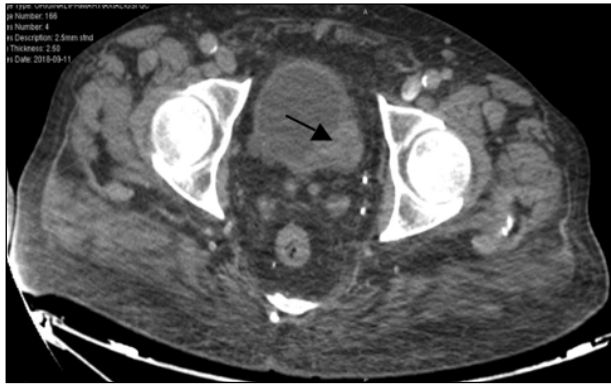The aetiology of benign ureteral obstructions can be intra-ureteral or extra-ureteral. Intra-ureteral causes are the result of various pathologies such as ureteropelvic junction obstruction, impacted chronic ureteral stones or strictures after recurrent endoscopic interventional procedures. Extra-ureteral benign obstructions may be caused by the obstetric causes, uterine leiomyomas or retroperitoneal fibrosis (4).

In cases of malignancy that cause severe ureteral obstruction, the benefits of draining the upper urinary system include symptomatic relief, preservation and maintenance of renal function, reduction of hospital stay and minimisation of the negative effects on the patient's quality of life (3-5).

However, there is still no clear guideline on ideal methods for how to free urinary flow in the management of ureteral obstructions (6). In patients without lower urogenital system pathologies and active urinary tract infection, retrograde ureteral stenting can be used as an alternative for long-term ureteral obstruction or fistula treatment.

The JJ stents used in this procedure are normally inserted in a retrograde approach by using a guidewire placed by cystoscopic or ureterorenoscopic method (1). However, in this approach, it is sometimes not possible to advance the guidewire proximally to the site of obstruction due to technical shortcomings, especially in patients with anatomical dislocation of the bladder wall, abnormally localised ureteral orifice by the tumor or in patients with malignant obstruction involving a long ureteral segment. In addition, retrograde ureteral stenting can sometimes be difficult or even unsuccessful in patients with obstructed

**Figure 1.**  
3 × 3 × 4 cm bladder tumour localised to the left lateral-bladder base that completely covers the left orifice (indicated by the arrow sign).



tive malignancy in the lower urogenital system, those who undergo urinary diversion surgery with ileal conduit, or patients with anatomical changes due to renal transplantation (7). In addition, retrograde ureteral stenting is usually performed under spinal or general anaesthesia that can be associated to serious complications and may be contraindicated in high-risk comorbid patients. In such cases, the best option is a permanent percutaneous nephrostomy or the placement of an ureteral JJ catheter in an antegrade manner with a percutaneous approach (8).

Percutaneous nephrostomy is a minimally invasive treatment option commonly used in the treatment of acute hydronephrosis, which aims to maintain existing renal function by providing drainage of intra-renal content. Although percutaneous nephrostomy is a very useful and feasible method, it has certain disadvantages compared to antegrade JJ stenting such as a more negative effect on patient comfort, a high risk of infection and easy dislocation of the catheter (8-9).

Antegrade JJ stenting is a minimally invasive alternative treatment technique (8) that is described by several studies in the literature.

The aim of the present study was to provide a retrospective analysis of antegrade JJ stenting results in a patient population with malignant ureteral obstruction who could not undergo retrograde JJ stenting in a tertiary health centre.

## MATERIALS AND METHODS

### Patient selection

Ethical approval was obtained from the local ethics committee for the study (Decision no: HRU/21.11.29).

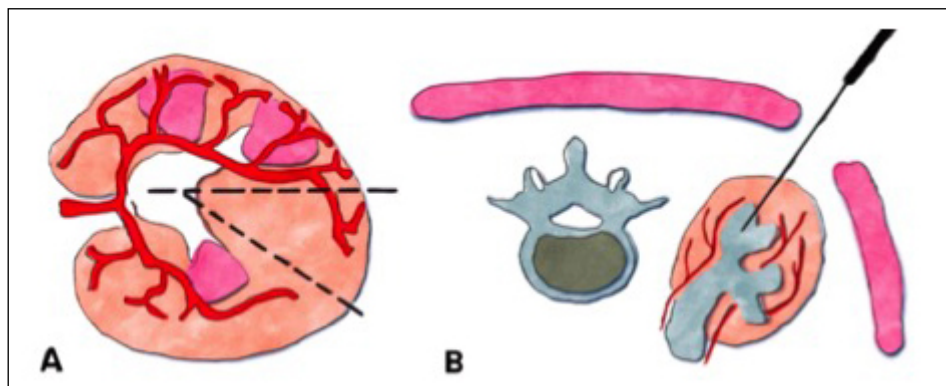
The data were obtained from electronic medical records, diagnostic imaging and laboratory examinations of patients who underwent JJ stenting due to malignant ureteral obstruction in the urology clinic of our hospital between January 1, 2018 and December 31, 2020.

Patients with ureteral obstruction who underwent retrograde JJ stenting with conventional technique were excluded from the study. Conversely, patients who could not undergo retrograde JJ stenting or who previously had percutaneous nephrostomy were included in the study. Antegrade JJ stenting procedures were performed with the guidance of a specialist interventional radiologist by a urologist with clinical experience. Absolute contraindications for antegrade JJ stenting included uncorrectable coagulopathy, severe vertebral bone and posture disorders, insufficient cardiopulmonary function, hemodynamic instability, pregnancy and severe uncontrolled hypertension.

### Antegrade JJ stenting technique

After receiving informed consent from the patient or first-degree patient relatives, the preoperative preparation process was completed. All patients were given preoperative iv (intravenous) antibiotic prophylaxis. All invasive procedures were performed under local or general anaesthesia by ultrasonography and fluoroscopy. After the patient was prepped, the procedure was usually performed in two stages. Percutaneous nephrostomy was first performed on patients who did not have previous nephrostomy. Then, in the same session, ureteral JJ stent was placed in the renal pelvis and ureter and by antegrade method. The patient was placed in the prone position and surgical area was sterilised. An 18-gauge-15 cm Chiba needle was used under the guidance of fluoroscopy and ultrasound, which ensured proper placement from the skin to the renal calyx with Seldinger technique (10).

The location of renal puncture was determined in accordance with the access indication taking into account anatomical constraints (5-10). Punctures were normally performed using the posterolateral oblique approach to the upper collecting system along Brödel's avascular plane, through the safest and easiest access to the ureteropelvic system (Figure 2).



**Figure 2.**  
Schematic drawing of the kidney avascular plane, also known as the Brödel line.

A: Magnification of the angle of entry of the needle into the right kidney, with the patient in the supine position.

B: Axial slice obtained with the patient in the prone position, demonstrating the ideal entry point for the percutaneous nephrostomy (Reference 5).

The needle was placed in the renal calyx selected by ultrasonography and a urine sample was collected and sent for urinalysis. After the needle was properly positioned, antegrade pyelography was performed with injection of non-ionic iodised contrast agent (350 mg I/mL) diluted with sterile saline in a ratio of 1/2 in order to reveal the collecting system anatomy fluoroscopically (Figure 3).

All sort of pathologies such as obstruction, stenosis or extravasation in the ureter were verified. (Figure 4).

According to the Seldinger technique, a 6 F introducer was placed towards the ureteropelvic junction. Using a hydrophilic 0.035-inch guidewire under serial scopy images, the 5 F diagnostic catheter was advanced by passing the obstruction site in the ureter and placed in the bladder. Hydrophilic guidewire was removed and a 0.035-inch J-tip teflon-coated guidewire was inserted into the bladder (Figure 5).

The 5 F catheter was then removed and replaced with a 6 Fr  $\times$  45 cm introducer sheath. The JJ catheter was advanced with the help of the teflon-coated guidewire or with the help of the sheath dilator feeding on the introducer sheath without the guidewire, until the distal end of the stent entered the bladder. The introducer sheath was then pulled back onto the dilator until the sheath

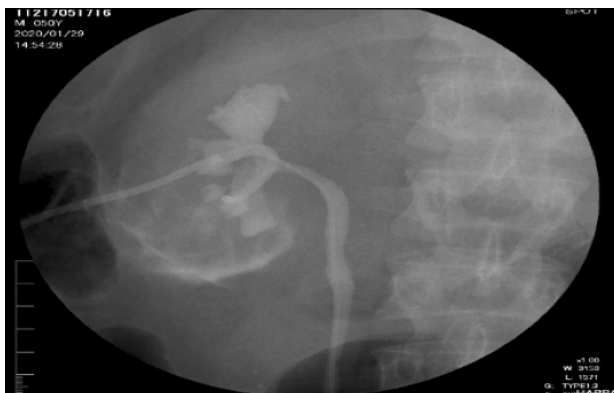
remained only in the renal pelvis. At this point, with the help of the dilator, the proximal (renal) tip of the JJ catheter was advanced to the appropriate position within the collecting system. Serial scopy images were obtained to confirm that the tip of JJ stent was curled in the bladder and renal pelvis (Figure 6).

Then, a 6 F percutaneous nephrostomy catheter was placed in the renal pelvis under the guidance of fluoroscopy and fixed to the skin.

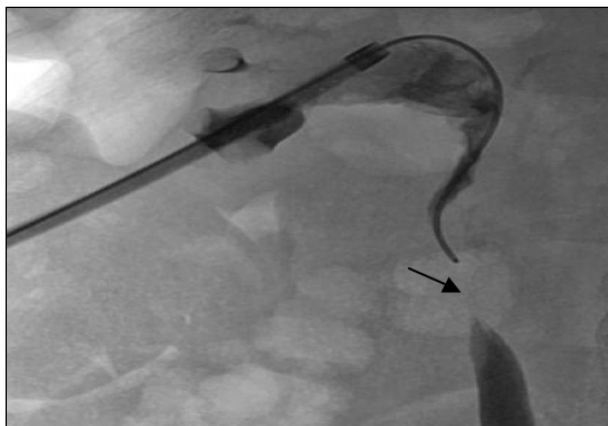
Abdominal ultrasonography was planned for all patients to exclude possible complications after antegrade JJ stenting. On postoperative day 1, DUSG (direct urinary system radiography) was done to observe the position of the JJ catheter and the excretion of the contrast agent used.

The nephrostomy catheter of the patients who did not have major complications and who did not have severe hematuria was removed in the postoperative 1-2 days under the guidance of fluoroscopy. The correct placement of the ureteral stent and the completion of the interventional procedure without major complications was considered as technical success. Clinical success was defined

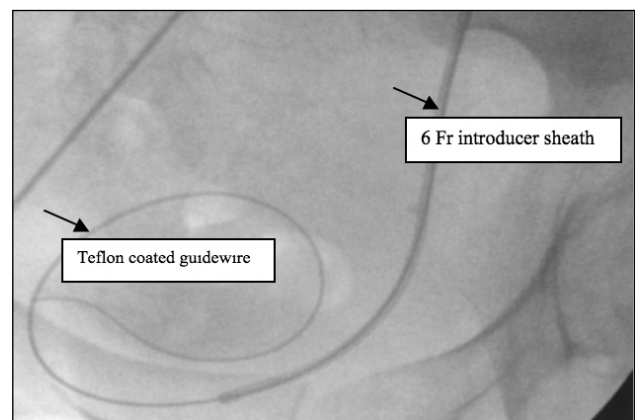
**Figure 3.**  
Right antegrade pyelography.



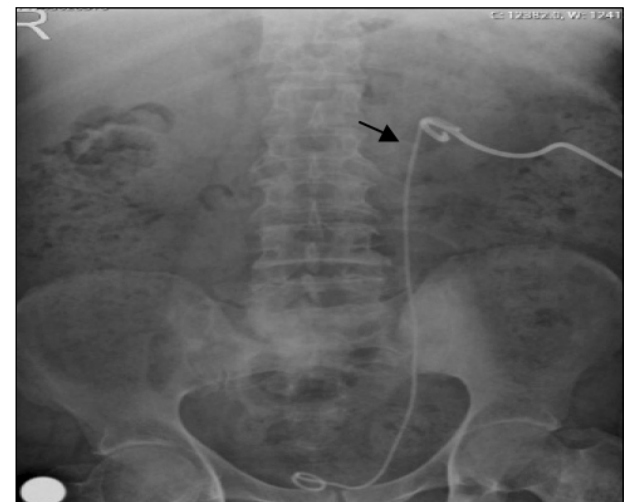
**Figure 4.**  
Right antegrade pyelography, narrow segment in proximal urethra and antegrade advancement of guide (indicated by the arrow sign).



**Figure 5.**  
Antegrade placement of the guidewire and curling in the bladder (indicated by the arrow sign).



**Figure 6.**  
JJ and nephrostomy catheter placed by left antegrade percutaneous approach.



as decreased blood creatinine levels to normal values, resolved hydronephrosis and complete recovery or decrease in symptoms in postop follow-ups.

**RESULTS**

During the study, antegrade JJ stenting procedure was performed on 40 patients (16 males, 24 females) who presented to our clinic. The mean age of the patients was 56.7 years. In all, antegrade JJ stenting was performed in 61 renal units of these patients. Of these, 21 were bilateral, 61 were in the right collecting system and 8 in the left collectinf system. Clinical and technical success was achieved in 59 of the 61 procedures (96.6%).

Severe obstruction was caused by malignant causes (bladder-prostate and colorectal cancers, among others) in 34 (85%) of the patients, whereas 6 (15%) had benign etiologies (C-section and ureteroendoscopic interventions, among others) (Table 1). The clinical and technical success rate in the patients was 96.3% and 100% for neoplastic and non-neoplastic groups, respectively.

In addition, 14 (35%) of the patients had important comorbidities such as coronary artery disease, cerebrovascular disease, diabetes and hypertension. In 33 patients that include those with high anaesthesia risk, the procedure was performed under local anaesthesia, while

**Table 1.** Patient distribution according to benign and malignant etiologies.

Malignancies	34 patients	85.0%
Endometrium carcinoma	5	12.5%
Colorectal carcinoma	8	20.0%
Bladder cancer	10	25.0%
Prostate cancer	1	2.5%
Ovarian carcinoma	1	2.5%
Cervix carcinoma	4	10.0%
Soft tissue carcinoma	5	12.5%
<b>Benign causes</b>	<b>6 patients</b>	<b>15.0%</b>
Surgical ligation (caesarean section)	3	7.5%
Ureteral stone (ureterorenoscopy)	3	7.5%
<b>Total</b>	<b>40 patients</b>	<b>100.0%</b>

**Table 2.** Aetiology of malignant urological obstructions, together with the distribution of approaches, technical success, failures and complications.

Indication	Patients	Unilateral approach	Bilateral approach	Technical success	Technical failure	Complications
Endometrium carcinoma	5 (12.5%)	2	3	5	—	—
Colorectal carcinoma	8 (20.0%)	3	5	8	—	1
Bladder cancer	10 (25.0%)	5	5	8	2	—
Prostate cancer	4 (10.0%)	2	2	4	—	—
Ovarian carcinoma	1 (2.5%)	—	1	1	—	—
Cervix carcinoma	5 (12.5%)	1	4	5	—	—
Soft tissue carcinoma	1 (2.5%)	—	1	1	—	—
Surgical ligation (caesarean section)	3 (7.5%)	3	—	3	—	—
Ureteral stone (ureterorenoscopy)	3 (7.5%)	3	—	3	—	—

**Table 3.** History of retrograde JJ and percutaneous nephrostomy according to aetiology.

	Retrograde JJ history		Percutaneous nephrostomy history	
	⇨	x	⇨	x
<b>Malignancies</b>				
Endometrium carcinoma	0	5	0	5
Colorectal carcinoma	3	5	3	5
Bladder cancer	4	6	6	4
Prostate cancer	2	2	2	2
Ovarian carcinoma	1	0	1	0
Cervix carcinoma	1	4	2	3
Soft tissue carcinoma	0	1	0	1
<b>Benign causes</b>	⇨	x	⇨	x
Surgical ligation (caesarean section)	3	0	0	3
Ureteral stone (ureterorenoscopy)	0	3	3	0

general anaesthesia was used in 7 patients. The mean blood creatinine values decreased from a preoperative value of 2.3 mg/dl to 1.1 mg/dl after the procedure.

In addition, the preoperative kidney antero-posterior (AP) diameter decreased from an average of 25.15 mm to 14.02 mm during postoperative follow-up. In two of the patients with bladder cancer aetiology, malignant ureteral obstruction could not be corrected due to lack of balloon dilatation material in our hospital and antegrade JJ stenting could not be performed. Therefore, percutaneous nephrostomy was performed (Table 2).

When the past clinical records of the patients were examined, it was determined that 14 patients had a history of retrograde JJ stenting and 17 had a history of percutaneous nephrostomy (Table 3). In the present study, antegrade JJ stenting was performed through the existing nephrostomy in only three patients.

During the follow-up, 75% of the patients developed clinically insignificant minimal haematuria, while almost all patients had pain at the wound site that resolved with simple analgesic treatment. The percutaneous nephrostomy catheter was fixed to the opening site for an average of 24-48 hours until the haematuria was completely resolved. Haematuria recovered spontaneously within a few hours, usually without the need for additional intervention. In one patient with colorectal malignancy, arte-

riovenous fistula, which can be considered a major complication, developed and the necessary treatment with angioembolisation was performed. No other patient developed serious complications such as bleeding, resistant haematuria, arteriovenous fistula or pseudoaneurysm requiring transfusion. Control DUSG taken on postoperative day 1 was checked to ensure that JJ stents were in the correct localisation. JJ stents were usually removed and new stents were placed within an average of 3 months. The procedure was performed either cystoscopically or

ureterorenoscopically using a retrograde technique with guide wire. Procedures were completed between 15-30 minutes on average.

## DISCUSSION

Ureteral obstructions may occur due to malignant or benign etiologies. In ureteral obstruction, options such as percutaneous nephrostomy or ureteral stenting are the most commonly used treatment methods (12). In the current retrospective study, we investigated the applicability of percutaneous antegrade ureteral stenting in the treatment of severe ureteral obstructions caused by both malignant and benign causes and we found that antegrade stenting is a safe and effective method in cases where the retrograde approach fails. Since both acute and chronic ureteral obstruction can cause impairment of renal function, these conditions may lead to severe morbidities. In addition, there is still no clear consensus in the literature on the treatment of malignant ureteral obstruction regarding the patient's clinical picture, emergency status, current technical equipment, or clinician's experience (6-11). The treatment method to be selected is usually determined depending on the physician's personal clinical experience, capabilities of the institution and patient preference (12).

Percutaneous nephrostomy has various risks such as wound site and urinary tract infection due to mandatory external drainage bag, and it also negatively affects the daily life and comfort of the patient (9).

Ureteral JJ stents are usually placed under cystoscopy with a retrograde approach in various obstruction cases. However, they have been successfully placed with antegrade approach by many years.

Both techniques are promising and give similar long-term results, but in recent studies, the failure rates of retrograde ureteral stenting in malignant ureteral obstruction has been reported to range between 18.5% and 42% (12-13-14). In addition, numerous studies have investigated the applicability of antegrade ureteral stenting (15-16).

In addition to similar long-term results, both techniques have their advantages and disadvantages. Using a retrograde approach, it is possible to simultaneously treat concomitant bladder and ureteral stones with endoscopic laser or pneumatic lithotripter or to take a punch biopsy sample from possible malignancies, or to expand existing strictures and relieve obstruction. Retrograde ureteral stenting is a one-step procedure but it has the disadvantage to be performed under general or spinal anaesthesia in operating room conditions (2-17). Particularly, general anaesthesia is a problem in patients with serious cardiac reserve or respiratory problems, and it is even contraindicated in some cases. In addition, in severe ureteral obstructions caused by malignant etiologies, factors such as external ureteral pressure or bladder invasion reduce the success rates of retrograde stenting method by up to 50% (7-15).

Clinical trials and observations have proven that antegrade ureteral stenting has higher success rates in severe ureteral obstructions due to both malignant and benign etiologies. Success rates reported in the literature range from 80% to 92% (17-18). In addition, balloon dilatation

can be performed during antegrade ureteral stenting, increasing technical success rates significantly. Furthermore, antegrade ureteral stenting can be performed successfully even under local anaesthesia, as opposed to retrograde method (18). In the present study, clinical and technical success with the antegrade method was 96.6% and the success rate was consistent with the literature. In only two procedures, percutaneous nephrostomy has to be performed because JJ stent could not be inserted by antegrade method.

Major complications associated with antegrade JJ stenting have been reported in the literature, but these occur in only 4-8% of cases (10). These complications include retroperitoneal bleeding, which can be treated with angiographic embolisation, perforation of the pleura or intraabdominal organs (such as intestine, liver, spleen) and urosepsis (8-19). Significant respiratory complications such as pneumothorax, hydrothorax and empyema are seen in less than 0.2% of patients (6).

Minor complications such as the extravasation of urine into the retroperitoneal area, subcapsular hematoma and macroscopic hematoma can develop in 3-15% of cases (20). Mild haematuria caused by urothelial irritation is a common finding after ureteral stenting and usually improves spontaneously during follow-up. However, in the presence of severe and resistant haematuria that develops after the placement of ureteral stent, ureteroarterial fistula between the ureter and the major or internal iliac artery should be considered first and necessary interventions should be performed quickly (6).

The clinician's mastery of urinary system anatomy and vascularisation is vital in choosing a safe pathway for percutaneous puncture and reducing the risk of complications (8-10-11). In the present study, only 3 (7.5%) of the patients developed minor complications including mild lumbar pain and minimal haematuria (Clavien Degree I), which usually recovered spontaneously within hours. Only one patient developed arteriovenous fistula, which is considered a major complication, and the necessary treatment was performed with angioembolisation.

In addition, although parenteral antibiotic prophylaxis is applied to all patients before the procedure, urinary tract infection is also a common finding. However, usually these infections can be successfully treated with basic antibiotics. However, if the current infection does not respond to medical pharmacological treatment, JJ stents may need to be removed immediately. In the present study, no symptoms of urinary tract infection that required stent removal was observed in any of the patients.

The present study has certain limitations. Firstm the study was designed and conducted retrospectively. Furthermore, the interventional radiology clinic in our hospital has just become operational, therefore the number of patients was limited. It becomes evident that the most important requirement at this stage is the clinical skill of an expert interventional radiology specialist.

## CONCLUSIONS

The results of this retrospective study show that percutaneous antegrade JJ stenting is possible in ureteral obstruction caused by both malignant and benign causes with

minimal risk of complications and high technical success rate. In addition, antegrade JJ stenting stands out as a good alternative option when conventional retrograde placement fails. To the best of our knowledge, there are no large-scale randomised controlled clinical trials in the literature comparing antegrade ureteral JJ stenting with retrograde JJ stenting. In addition, there is still no clear consensus in the literature on the treatment of malignant ureteral obstruction regarding the patient's clinical picture, emergency status, current technical equipment, or experience of the interventional radiologist. Therefore, in patients with malignant ureteral obstruction, randomised controlled trials with a larger population are needed to gain further information on the optimal approach to ureteral JJ stenting.

## REFERENCES

1. Zimskind PD, Fetter TR, Wilkerson JL. Clinical use of long-term indwelling silicone rubber ureteral splints inserted cystoscopically. *J Urol.* 1967; 97:840-4.
2. Seymour H, Patel U. Ureteric stenting: Current status. *Semin Intervent Radiol.* 2000; 17:351-65.
3. Nunes TF, Tibana TK, Santos RFT, et al. Percutaneous insertion of bilateral double J stent. *Radiol Bras.* 2019; 52:104-105.
4. Fletcher HM, Wharfe G, Williams NP, et al. Renal impairment as a complication of uterine fibroids: a retrospective hospital-based study. *J Obstet Gynaecol.* 2013; 33:394-8.
5. Meira MS, Barbosa PNV, Bitencourt AGV, et al. Análise retrospectiva das nefrostomias percutâneas guiadas por tomografia computadorizada em pacientes oncológicos. *Radiol Bras.* 2019; 52:148-54.
6. Hsu L, Li H, Pucheril D, et al. Use of percutaneous nephrostomy and ureteral stenting in management of ureteral obstruction. *World J Nephrol.* 2016; 5:172-81.
7. Chitale SV, Scott-Barrett S, Ho ET, Burgess NA. The management of ureteric obstruction secondary to malignant pelvic disease. *Clin Radiol.* 2002; 57:1118-21.
8. Venyo AKG, Hanley T, Barrett M, et al. Ante-grade ureteric stenting, retrospective experience in managing 89 patients: indications,

complications and outcome. *Journal of Biomedical Graphics and Computing.* 2014; 4:47-56.

9. Bahu R, Chaftari AM, Hachem RY, et al. Nephrostomy tube related pyelonephritis in patients with cancer: epidemiology, infection rate and risk factors. *J Urol.* 2013; 189:130-5.
10. Dyer RB, Regan JD, Kavanagh PV, et al. Percutaneous nephrostomy with extensions of the technique: step by step. *Radiographics.* 2002; 22:503-25.
11. van der Meer RW, Weltings S, van Erkel AR, et al. Antegrade ureteral stenting is a good alternative for the retrograde approach. *Curr Urol.* 2016; 10:87-91.
12. Matsuura H, Arase S, Hori Y. Ureteral stents for malignant extrinsic ureteral obstruction: outcomes and factors predicting stent failure. *Int J Clin Oncol.* 2019; 24:306-312.
13. Kamiyama Y, Matsuura S, Kato M, et al. Stent failure in the management of malignant extrinsic ureteral obstruction: risk factors. *Int J Urol.* 2011; 18:379-82.
14. Yu SH, Ryu JG, Jeong SH, et al. Predicting factors for stent failure-free survival in patients with a malignant ureteral obstruction managed with ureteral stents. *Korean J Urol.* 2013; 54:316-21.
15. Turgut B, Bayraktar AM, Bakdik S, et al. Placement of double-J stent in patients with malignant ureteral obstruction: antegrade or retrograde approach? *Clin Radiol.* 2019; 74:976.e11-976.e17.
16. Kahrman G, Özcan N, Dogan A, et al. Percutaneous antegrade ureteral stent placement: single center experience. *Diagn Interv Radiol.* 2019; 25:127-133.
17. Uthappa MC, Cowan NC. Retrograde or antegrade double-pig-tail stent placement for malignant ureteric obstruction? *Clin Radiol.* 2005; 60:608-12.
18. Adamo R, Saad WE, Brown DB. Management of nephrostomy drains and ureteral stents. *Tech Vasc Interv Radiol.* 2009; 12:193-204.
19. Pabon-Ramos WM, Dariushnia SR, Walker TG, et al. Society of Interventional Radiology Standards of Practice Committee. Quality Improvement Guidelines for Percutaneous Nephrostomy. *J Vasc Interv Radiol.* 2016; 27:410-4.
20. Ganatra AM, Loughlin KR. The management of malignant ureteral obstruction treated with ureteral stents. *J Urol.* 2005; 174:2125-8.

## Correspondence

Eser Ordek, MD (Corresponding Author)

dr\_eseser@hotmail.com

Kahta State Hospital, Urology Department 02000Adiyaman (Turkey)

Mehmet Kolu, MD

drdylg@gmail.com

Harran University, Faculty of Medicine Hospital, Radiology, 63340 Sanliurfa (Turkey)

Mehmet Demir, MD

drdemir02@gmail.com

Bulent Kati, MD

bulentkati@harran.edu.tr

Eyyup Sabri Pelit, MD

dreyyupsabri@hotmail.com

Ismail Yagmur, MD

dr\_iyagmur@hotmail.com

Harran University, Faculty of Medicine Hospital, Urology, 63340 Sanliurfa (Turkey)