

# Core urological surgical training: The pivotal role of feminizing genital reconstruction for gender dysphoria

Gianmartin Cito<sup>1\*</sup>, Elena Rovero<sup>1\*</sup>, Francesco Sessa<sup>1</sup>, Simone Sforza<sup>1</sup>, Girolamo Morelli<sup>2</sup>, Arturo Lo Giudice<sup>3</sup>, Lorenzo Masieri<sup>1</sup>, Andrea Minervini<sup>1</sup>, Riccardo Bartoletti<sup>2</sup>, Giorgio Ivan Russo<sup>3</sup>, Andrea Cocci<sup>1</sup>

<sup>1</sup> Department of Urology, Careggi Hospital, University of Florence, Florence, Italy;

<sup>2</sup> Department of Urology, Cisanello Hospital, University of Pisa, Pisa, Italy;

<sup>3</sup> Department of Urology, University of Catania, Catania, Italy.

\* These authors contributed equally to the work.

**KEY WORDS:** Sex reassignment; Male to female; Surgery; Urology; Gender.

Submitted 25 November 2021; Accepted 3 December 2021

## INTRODUCTION

In recent years, the surgical techniques for sex reassignment surgery in *male-to-female* (MtoF) transsexualism have been standardized and improved with better functional and aesthetic results, therefore increasing patients' satisfaction. Feminizing genital reconstruction is a complex surgical procedure that can be performed by using several skills such as penile skin inversion, penoscrotal flap, enterovaginoplasty. This challenging surgery is done by specific steps that could be related to other procedures in uro-andrological field, especially for benign conditions. In this context, MtoF reassignment surgery could represent a complete training model for future urologists. Here, we aim to describe all surgical steps of feminizing genital reconstruction as a core urological surgical training for young urologists.

## MTOF REASSIGNMENT SURGERY

From November 2016 to December 2019, all resident doctors in urology training were involved in MtoF reassignment surgery.

The basic steps of the feminizing genital reconstruction for gender dysphoria were described as follow:

### 1. Orchiectomy

After anesthesia is induced, the patient is placed in the lithotomic position. An inverted U-shaped incision on the posterior surface of the scrotum is performed, the incision is extended through subcutaneous tissue so that the urethral corpus spongiosum and corpora cavernosa are bilaterally exposed (Figure 1). Subsequently, bilateral orchiectomy is performed by dissecting and suturing both spermatic cords at the level of external inguinal rings (Figure 2). Once this is done, the proximal end of these structures will retract into the inguinal canal, in order to close bilaterally external inguinal ring to avoid future weakness that can lead to inguinal hernia (1).

### 2. Penile degloving

A circumferential subcoronal incision is made, allowing outwards folding of the penile skin downward to the base in order to expose the corpora. The penile skin is transected from the corpus spongiosum and the corpora cavernosa. A cylindrical penile skin flap is created and dissected from the albuginea, being careful to preserve the vitality of the skin, this flap will provide the anterior wall of the neovagina (Figure 3).

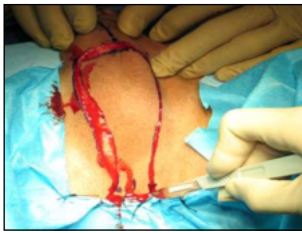### 3. Penectomy

The corpus spongiosum is isolated starting from the crura up to the penile glans. Through a bilateral incision of the Buck's fascia, a plane is created between the tunica albuginea and the dorsal neurovascular bundle, whose connection to the glans is meticulously preserved. The glans is detached from the corpora cavernosa without danger and neurovascular bundle isolation is held in a retrograde fashion (Figure 4). The corpora are then excised as proximally as possible (1).

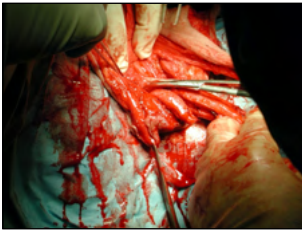### 4. Creation of a prostatic space

Fibers of bulbocavernosus muscles are divaricated on the midline and the bulbar urethra is completely freed. The central tendon of the perineum is incised, and an accurate, blunt dissection is performed in order to create a wide space between

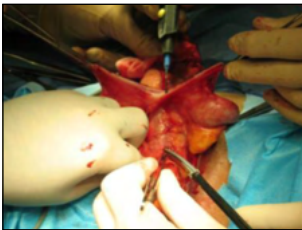No conflict of interest declared.



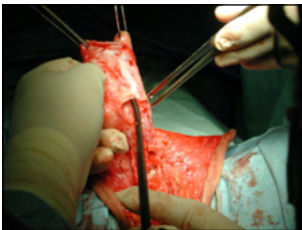**Figure 1.**  
*Inverted U-shape incision on the posterior aspect of the scrotum, centrally prolonged on the penis.*



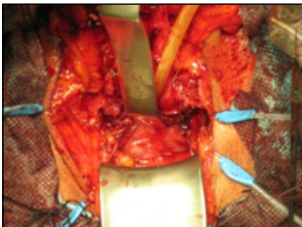
**Figure 2.**  
*Isolation of the testis and spermatic cord, before the ligature at the external inguinal ring.*



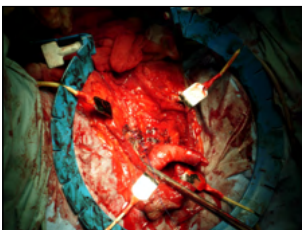
**Figure 3.**  
*Penile degloving.*



**Figure 4.**  
*Asportation of corpora cavernosa after isolation of neurovascular bundle.*



**Figure 5.**  
*Creation of a prostatesrectal space or neovaginal cavity, we can appreciate the prostate with Denonvillier's fascia.*



**Figure 6.**  
*Conservation of bulbar urethra and reduction urethral bulb.*

the rectum and the prostate, where the neovagina will be placed. The Denonvillier's fascia is identified, and the blunt dissection continues through this avascular plane, transecting the medial fibers of the elevator ani muscles (Figure 5). The penile-scrotal cylinder of skin is placed into the neo-cavity, forming the neovagina and sutured to the Denonvillier's fascia (1).

#### 5. Creation of the neourethra

After the bulb of penis is completely excised, the distal urethra is reduced at the pubic symphysis and passed through a second incision, more ventrally, so as to obtain a Y-shaped. The distal part of the urethral stump is spatulated and the urethro-cutaneous anastomosis is performed, with the apex fixed to the anterior portion of pubis. This becomes the reference point for positioning the neoclitoris, which will be framed by urethral mucosa. The urethral bulb is carefully removed in order to avoid its bulging during sexual arousal and dyspareunia (Figure 6). The creation of the urethra-clitoris complex gives to the neoclitoris a mucosal environment providing adequate lubrication; furthermore, the two layers suture permits a reciprocal vascular support, useful in case of urethral or clitoral ischemia (2).

#### MAIN FINDINGS

We analyzed how the learning curve of MtoF reassignment surgery could influence the skills of the same resident in practicing simpler andrological procedures as lead surgeon, assisted by his tutor.

After performing 10 feminizing genital reconstructions as assistant surgeon, the resident performed 64 andrological procedures as lead surgeon, at the end of his training period with the tutor in the operating room (Table 1). No postoperative complications occurred. Operating times, as well as hospitalization times were comparable to those performed by the tutor.

After the first 10 procedures, the mean operating time decreased of 20 minutes (SD  $\pm$  5;  $p < 0.05$ ) and the mean blood loss decreased of 80 ml (SD  $\pm$  15;  $p < 0.05$ ).

The perineal approach using the inverted U-shaped incision on the posterior surface of the scrotum, the dissection and suture of spermatic cords at the external inguinal rings and the bilateral orchiectomy helped the learning curve of the resident for the radical orchiectomy to treat testicular torsion ( $n = 5$ ). Likewise, it helped to practice bilateral orchiopexy for testicular retraction ( $n = 10$ ), that is generally performed with vertical perineal incision or homolateral transversal incision; by the way it was possible to facilitate to learn the inguinal approach, the exteriorization and asportation of the spermatic cord and testicle, that must be preferred in case of testicular cancer.

The acquired expertise in gonadic surgery helped also to learn the procedure of hydrocelectomy in case of tense and large hydrocele ( $n = 5$ ). Once a scrotal median incision is performed, the fluid is aspirated, the testicle exposed, and the sac everted to avoid a recurrence.

The process of penile degloving in MtoF reassignment surgery facilitated the performance for the treatment of congenital or acquired penile curvature (Nesbit's corporoplasty,  $n = 2$ ). In this

Procedure	Total
Circumcision	25
Orchiopexy	10
Varicocelectomy	10
Radical orchifuniclectomy	5
Hydrocelectomy	5
Corporoplasty	2
Penile prosthesis implantation	3
Meatoplasty	2
Radical or partial penectomy	2

**Table 1.**

*Andrological procedures performed by resident, as lead surgeon, at the end of his training period with the tutor in the operating room.*

case, the best approach for penile skin degloving is a circumcisional incision 0,5-1 cm below the coronal sulcus deepened until the whitish Buck's fascia, continued by blunt and sharp dissection (3).

Circumcision and dissection with Dartos fascia preservation, to obtain a complete penile degloving, is normally performed during feminizing genital reconstruction for gender dysphoria. This training simplifies the learning ability of other surgical steps such as circumcision (n = 25), in case of severe phimosis or the preservation of the dorsal neurovascular bundle, required during corporoplasty.

Moreover, the penoscrotal approach is widely used to implant penile prosthesis for the treatment of erectile dysfunction (n = 3) (4). The feminizing genital reconstruction helped also to get skills concerning functional anatomy of the penis, that allowed the resident to practice in radical penectomy for penile cancer (n = 2) (5).

The preparation of the urethral stump before the urethrocutaneous anastomosis for the creation of the neourethra in feminizing genital reconstruction was useful to learn procedures of meatoplasty, performed in case of urethral strictures (n = 2) (6).

Lastly, sex reassignment surgery requires expertise of the inguinal canal anatomy, that is conductive in varicocele treatment (n = 10). The inguinal approach involves a 3-5 cm incision over the inguinal canal, the opening of the external oblique aponeurosis and the delivery of the spermatic cord. All internal spermatic veins are identified and dissected under microscopy and then ligated with sutures or surgical clips. The vas deferens, vasal vessels, testicular artery and as many lymphatic channels as possible are preserved.

In conclusion, assisting to complex andrological procedures, as MtoF reassignment surgery, seems to have a positive influence in facilitating the learning curve of other simpler procedures in young urologists. Thus, the challenging steps of feminizing genital reconstruction could be a core urological training in performing surgery for andrology conditions.

## REFERENCES

1. Mirone V, Imbimbo C, Verze P, Arcaniolo D. Transgender reconstructive surgery. In: Austoni E (ed). *Atlas of reconstructive penile surgery*. 1<sup>st</sup> edn. (Pacini Editore Medicina, 2010) pp.419-432.
2. Trombetta C, Liguori G, Bertolotto M (eds). *Management of Gender Dysphoria: A Multidisciplinary Approach*. (Springer, Milan, Heidelberg, New York, Dordrecht London, 2015).
3. Fabiani A, Fioretti F, Pavia MP, et al. Buccal mucosa graft in surgical management of Peyronie's disease: Ultrasound features and clinical outcomes. *Arch Ital Urol Androl*. 2021;93:107-110.
4. Bayrak O, Erturhan S, Seckiner I, et al. Comparison of the patient's satisfaction underwent penile prosthesis; Malleable versus Ambicor: Single center experience. *Arch Ital Urol Androl*. 2020; 92:25-29.
5. Moulavasilis N, Yiannopoulou K, Frangoulis M, et al. A surgical approach to squamous cell carcinoma of penis that also resolved the psychological dysfunction of the patient. *Arch Ital Urol Androl*. 2020; 92:58-60.
6. Gentile G, Martino A, Nadalin D, et al. Penile-scrotal flap vaginoplasty versus inverted penile skin flap expanded with spatulated urethra: A multidisciplinary single-centre analysis. *Arch Ital Urol Androl*. 2020; 92:186-191.

## Correspondence

Gianmartin Cito, MD  
gianmartin.cito@gmail.com

Elena Rovero, MD  
elena.rovero@stud.unifi.it

Francesco Sessa, MD  
francesco\_sessa@hotmail.it

Simone Sforza, MD  
simone.sforza1988@gmail.com

Lorenzo Masieri, MD  
lorenzo.masieri@meyer.it

Andrea Minervini, MD  
andreamine@libero.it  
Andrea Cocci, MD, PhD (Corresponding Author)  
cocci.andrea@gmail.com

Department of Urology, Careggi Hospital, University of Florence, Largo Brambilla 3, 50134, Florence (Italy)

Girolamo Morelli, MD  
girolamomorelli@gmail.com

Riccardo Bartoletti, MD  
riccardo.bartoletti@hotmail.com  
Department of Urology, Cisanello Hospital, University of Pisa, Via Piero Trivella, 56124, Pisa (Italy)

Arturo Lo Giudice, MD  
arturologiudice@gmail.com

Giorgio Ivan Russo, MD  
giorgioivan1987@gmail.com  
Department of Urology, University of Catania, Via Plebiscito, 628, 95124, Catania (Italy)