

# Penile prosthesis and complications: Results from 577 implants

Diego Pozza<sup>1</sup>, Andrea Marcantonio<sup>1</sup>, Augusto Mosca<sup>2</sup>, Carlotta Pozza<sup>3</sup>

<sup>1</sup> Studio di Andrologia e di Chirurgia Andrologica, Roma, Italy;

<sup>2</sup> Urology and Andrology Unit, S. Sebastiano Hospital, Frascati, Italy;

<sup>3</sup> Department of Experimental Medicine, Sapienza University, Roma, Italy.

**Summary** Objective: Penile Prosthetic Surgery is already well characterized but the problems connected with possible complications still need to be evaluated and discussed.

**Material and Methods:** The Authors reevaluated their experience in Penile Prosthetic Surgery involving 577 patients (18 - 86 years, mean age 51.3 years) operated by the same surgeon since 1984. We implanted 199 silicone-semi-rigid (Small Carrion, Implantal, Eurogest, Subrini, SSDA GS), 200 malleable (Jonas, Omniphase, Duraphase, AMS600, MentorColoplast Genesis, Vedise) and 178 inflatable (Mentor: Mark II, Alpha I, Titan OTR; AMS: mono-component Hydroflex, Dynaflex; bi-component Ambicor; multi-component: 700 Ultrex, 700 CX, 700 LGX) prostheses. Operative, postoperative, infectious and malfunctioning complications have been recorded. A total of 156 patients drop out at follow-up and we may not exclude possible late complications treated at different hospitals.

**Results:** The recorded complications and the therapeutic modalities utilized to treat them are examined. Operative complications were recorded in 2 malleable prostheses (MPP) and in one inflatable prosthesis (IPP).

Postoperative complications have been recorded in three cases of MPP (1.5%) and in 9 IPP (5.0%) and were strictly connected to general medical co-morbidities as diabetes mellitus (DM), coronary artery dysfunction (CAD), and Peyronie's disease (PD). In three cases of IPP implantation, hematomas were related to the blunt surgical maneuvers utilized to insert the reservoir or the scrotal pumps.

Infectious complications were mostly observed in patients with DM: 4 patients with MPP (1.0%) and 15 patients with IPP (8.4%). Malfunction rate of the prostheses in our series was really disappointing considering that 13/17 cases (77%) of mono-component IPP broke while in patients with multicomponent IPP the percentage of malfunction has been of 13/161 (8%) and malfunction was observed in only one case of MPP. We were forced to explant the prostheses in 2 patients with MPP (0.5%) and 40 with IPP (22%).

However, after excluding 17 mono-component IPPs, the percentage of explants of multicomponent IPP (23 patients, 4.2%) is in line with other significative experiences.

**Conclusion:** The number of complications of PPS are similar to those reported by well qualified urological institutions. In our experience a scrupulous antibiotic therapeutic schedule, avoiding direct contact between the prostheses and the patient's skin, reduced time of surgery with surgeon's experience positively influenced the results.

*In a limited number of patients medical treatment or minimal surgical acts allowed to solve the complications preserving the prostheses and avoiding the prosthetic explant.*

**KEY WORDS:** Penile prosthesis surgery; Complications; Infections.

Submitted 14 June 2020; Accepted 26 August 2020

## INTRODUCTION

Since the first penile prosthetic implants, in 1972 (1-3), the relevant problems related to surgical technique, durability of materials and prosthetic mechanisms (4-7), the high risk of infections (8-11) and the possible traumas related to an incorrect use of the prostheses continue to be object of medical consideration (12).

With the increase of operated cases (13, 14), the surgical ability has significantly improved; in parallel medical companies have introduced new materials that last longer over time and are less subject to wear and tear. Despite these improvements, the possibility that the insertion of a prosthesis could lead to dangerous and harmful maneuvers still exists. We have to consider that the particular weakness of the cavernous and perineal tissues such as may occur after pelvic surgery or radiation therapy, the structural alterations in Peyronie's Disease (PD) and the presence of comorbidity such as Diabetes Mellitus (DM) or Coronary Artery Disease (CAD) continue to make Penile Prosthetic Surgery (PPS) a risky surgery (15-17).

## MATERIALS AND METHODS

From 1984 to 2020 over 39,000 patients (pts) (age 6-90 years) with urological and/or andrological problems presented to our outpatient clinic for consultation. Out of them, 9540 patients (25.1%) complained of Erectile Dysfunction (ED). After an accurate taking of medical history and clinical evaluation we requested appropriate diagnostic tests (routine blood tests, hormonal evaluation, ColorDuplexSonography, sometimes Magnetic Resonance imaging, cavernometry and neurologic tests). We then prescribed currently available therapies (psychotherapy, hormones, venous surgery, vasoactive intracavernous injections, oral phosphodiesterase type 5

No conflict of interest declared.

inhibitors, *Medical Urethral System for Erection* (MUSE) or alprostadil urethral creams, vacuum).

To 952 patients who had no satisfactory results with the first line therapies used, we suggested a Penile Prosthesis (PP). The *Italian National Health System* did not refund the costs of such surgery and therefore, until a few years ago, patients had to cover the not-negligible expenses for the cost of prostheses, clinics, and surgeons. For these reasons, the type of prosthesis to implant was selected also considering their economic cost. Of 952 patients, 577 (age 18-86 years) accepted the prosthetic solution of their ED. We began to implant PP in 1984 performing the surgical procedures in different private clinics in Rome.

We implanted 199 silicone semi-rigid (*Small Carrion, Implantal, Eurogest, Subrini, SSDA GS*), 200 malleable (*Jonas, Omniphase, Duraphase, AMS600, Mentor/ Coloplast Genesis, Vedise*) and 178 inflatable (*Mentor: Mark II, Alpha I, Titan OTR; AMS: Hydroflex, Dynaflex, Ambicor, 700 Ultrex, 700 CX, 700 LGX*) prostheses.

We systematically used an antibiotic therapy (AbThe) with Ciprofloxacin 1 g/day since 3- 4 days before surgery until 7-10 days after; Gentamicin Sulfate 150 mg/bid starting from the day of surgery until the day after, Ceftriaxone 2gr/iv just before surgery and 1gr/day until 7 days after (16).

Patients were hospitalized the night before or the morning of surgery. Genital skin was shaved 1-2 hours before surgery. Spinal anesthesia was mostly used; local anesthesia with sedation, for semi-rigid or malleable prostheses, was performed in 40 patients. The time of the surgery varied between 35 to 120 minutes. In cases of PD with significant curvature Wilson's maneuver (14), plaque's incision or excision with heterologous grafting were performed. Patients were discharged the day after surgery; patients implanted with inflatable prosthesis (IPP) or living outside Rome 2-3 days later. Follow-up visits were performed, generally, after 7 days, 4 weeks and 1 year. A total of 156 patients dropped out at follow-up and we cannot exclude possible late complications.

## RESULTS

We recorded a series of operative, late postoperative, mechanical, infectious and removal complications that we report below.

## OPERATIVE COMPLICATIONS

### *Perforation of the cavernosal septum*

In 2 patients, during cavernosal dilation we perforated the septum inserting the two cylinders in the same cavernous space. In one case we were immediately aware of the incorrect location of the cylinders. In the second case, we discovered the incorrect insertion during the final suture steps. We managed to correct the defect by placing the cylinder in the correct cavernous space. In both cases, no significant immediate or postoperative complications were recorded.

In 1 case of AMS 700CX IPP implantation, the rear part of the right cylinder was improperly positioned in the left cavernous root. The IPP functioned regularly and the

patient was discharged after 2 days. After 3 months, the scrotal pump malfunctioned and the IPP had to be removed. At that time, during surgery, we discovered the erroneous placement of the right cylinder. The new IPP was correctly replaced and the postoperative course had no problems. After 8 years the patient is still fine and satisfied with the IPP.

### *Crural Perforation*

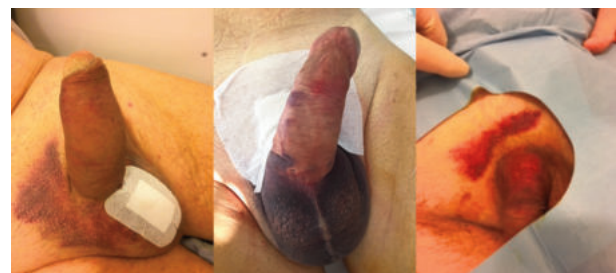During the cavernous dilation in a young patient suffering from Corporal Venous Occlusive Dysfunction (CVOD), we caused the perforation of the right crus with pathological progression of scissors and Hegar's dilators beyond the crus. No evident perineal hematoma happened. We decided to conclude the procedure inserting a Rear Tip Extender (RTE) into the cavernous crus and, through a small perineal incision, we affixed it with stitches to the albuginea tunica. We inserted the Eurogest cylinders, 21 cm into the left and 19 cm into the right space. We did not record significant postoperative complications. The patient after 6 years continues to be satisfied.

## POSTOPERATIVE COMPLICATIONS

### *Superficial Ecchymosis – Hematomas*

Postoperative formation of blood effusions or hematomas is a common surgical complication. For this reason, the patient is always advised to suspend anticoagulants and/or aspirin 7-10 days before surgery. Cutaneous bruising and superficial hematomas tend to disappear in a few weeks (Figure 1). We recorded scrotal hematomas in 6 patients: 3 patients after peno-scrotal access and 3 patients after blunt dilation performed to place the scrotal pump after infra-pubic incision. Until 1992, we did not use any suction drainage, but after the first episode of voluminous hematoma we began to place a suction drainage (12) that we generally remove 16-24 hours after surgery in all cases of IPP. We do not use drainage in cases of malleable prostheses (MPP) (13).

**Figure 1.** Postoperative local and diffuse ecchymosis. Simple medical treatment.



### **Case 1**

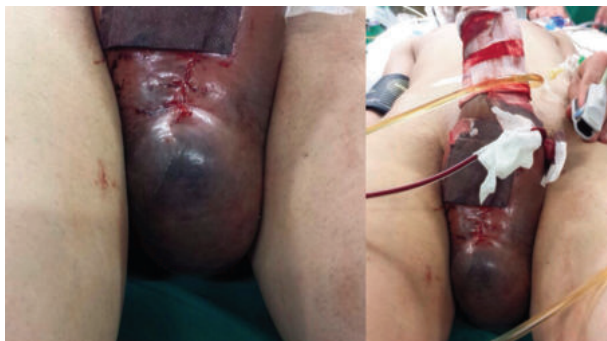A 52 year-old patient had to remove an IPP for malfunction after 8 years. The removal and repositioning of a new AMS700CX prosthesis did not present any problem. After 16 hours, next morning, the drainage had aspirated 15-20 cc of blood. We deflated the cylinders that had been left swollen since operation. The patient had to be dismissed

in the late afternoon so we maintained the drainage. In the hours after we noticed an abundant blood collection in the vacuum cleaner and hematic suffusion at the base of the penis. We brought the patient back to the Operating Room (OR) but we did not find any bleeding vessel. Blood was seeping out of an incomplete suture of the cavernous body. We applied a stitch, inflated the prosthetic cylinders and the bleeding completely stopped. The drainage was removed after 24 hours and the patient was discharged maintaining fully inflated cylinders for 15 days. After 5 years the patient is satisfied.

### Case 2

A 31 years-old patient, developed a voluminous hematoma of the penis and scrotum after IPP with drainage in suction. After 10 hours, at night, the volume of the scrotum and the base of the penis began to increase for a voluminous hematoma (Figure 2). We immediately checked him in the OR but we failed to identify obvious sources of bleeding. Multiple local and scrotal washes were performed. We kept fully inflated the cylinders and maintained the drainage for 3 days until the patient was discharged. The cylinders were kept inflated for 10 days. After surgery, the patient was diagnosed with an unknown coagulative disease.

**Figure 2.** Relevant hematoma after Coloplast inflatable penile prosthesis with drainage due to unrecognized coagulation's problem. An immediate surgical revision was performed. No damages to the patient and the inflatable penile prosthesis.



### Case 3 & 4

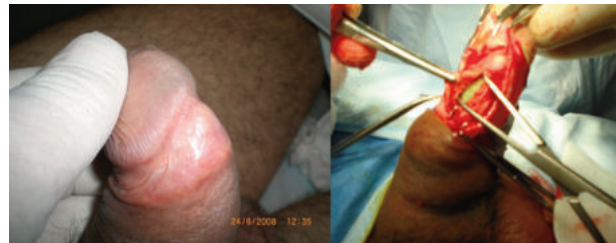Two patients (72 and 74 years old) with DM and CAD, after Radical Prostatectomy (RP), received an IPP. In the 2 cases the drainage was negative at discharge but after 7-10 days, with the resumption of aspirin and anticoagulant treatment (Coumadin), they complained of scrotum bulge with pain and difficulty in finding the scrotal pump. In one case we preferred to operate on to drain a scrotal hematoma with rapid healing. In the second, less evident, case, we solved the problem after a month with medical therapy.

### Apical Extrusion

After 4 years from implantation of an AMS700Cx IPP for PD with mild dorsal curvature, a 56 years old patient complained of persistent pain in the glans. The glans appeared deformed. Suspecting an apex extrusion, it was decided to operate on. After sub-coronal incision, we

detected the extrusion of the right prosthetic cylinder, however, not in contact with the outside (Figure 3A). A small medium-penile incision was performed and the right prosthetic cylinder was fully removed (Figure 3B). We changed the 2 cm RTE with a 1 cm RTE. The apex of the right cavernous body was closed by applying a patch of Marlex tissue like a hood. After reinserting the cylinder the corporotomy was sutured and the glans fixed to the albuginea. The cylinders were maintained inflated for 10 days. In 2020, the patient continues to be satisfied.

**Figure 3.** A: Extrusion of the right cylinder of inflatable penile prosthesis under the glans; B: Removal and shortening of right cylinder's rear tip extender. Repairing of the cavernous tip with Marlex hood.



### Apical Extrusion with removal

#### Case 1

In a 56 years old patient with DM, an Hydroflex cylinder perforated the apex of the right cavernous body after 8 months from implantation (Figure 4A). The IPP did not work so we removed the 2 cylinders. After dismissal, the patient was lost at follow-up.

#### Case 2

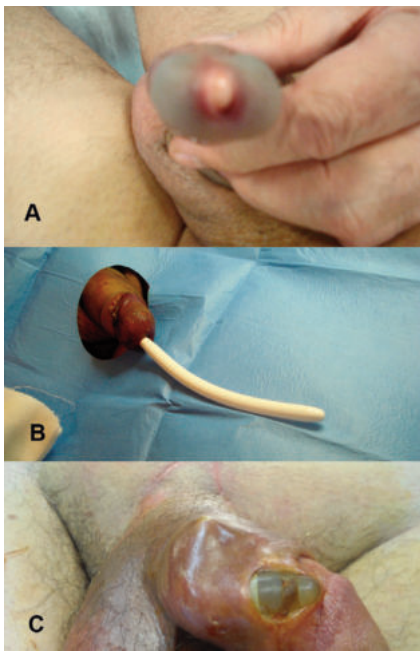
In a 36 years old patient, with DM and CAD and CVOD, we implanted a couple of Implantal 120 MPP in 2003. The patient got married, he fathered a son and after 6 years he began to feel a constant pain in the glans. In a few days the cylinder came out. We extracted the prosthetic cylinder, washed with antibiotic solution and did not insert a new cylinder for the risk of infection. After 3 months the patient reported that he had no more pain being able to have penetrative intercourses with his wife. He refused a possible re-intervention to reposition the missing prosthetic cylinder mainly for economical reasons (Figure 4B).

#### Case 3

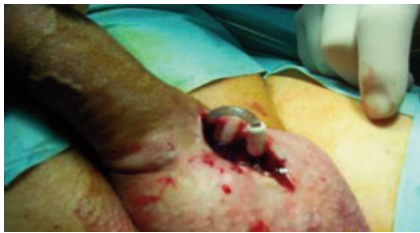In a 65 years old patient with DM, an infection of the IPP begun to develop after 35 days. The evolution of the infection was aggressive, not modified by complex antibiotic treatment, till the extrusion of the right cylinder due to necrosis of cavernous body. It was immediately explanted (Figure 4C).

### Skin erosion due to connection tubes

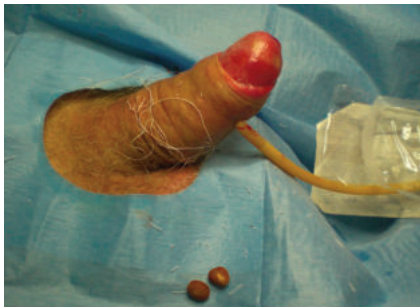A 66 years old patient with DM received in 1999 an IPP with penoscrotal incision. After 7 years he begun to feel pain near the peno-scrotal scar where the presence of the connecting tubes was always felt. After the pain, local bulging appeared with leakage of serous not infected



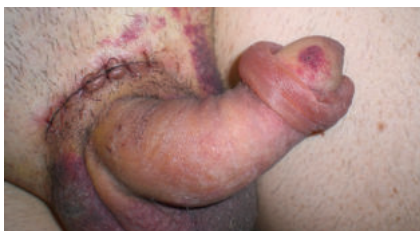**Figure 4.**  
**A:** Apical extrusion of Hydroflex penile prosthesis covered by the glans, probably without infection.  
**B:** Complete extrusion of implantal cylinder.  
**C:** Complete extrusion of inflatable penile prosthesis after severe cavernosal infection in a patient with diabetes mellitus.



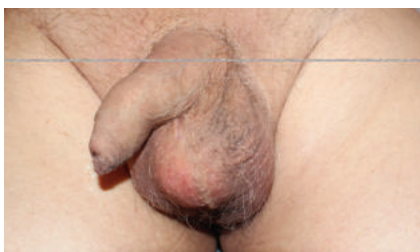
**Figure 5.**  
 Scrotal superficial extrusion of inflatable penile prosthesis tubing without infection. Simple surgical repair of the scrotal tissues.



**Figure 6.** Two urethral stones extracted in a patient with inflatable penile prosthesis after renal colic.



**Figure 7.**  
 Preputial edema in IPP due to infra-pubic incision.



**Figure 8.**  
 Scrotal pump surrounded by clear fluid under the neo-capsule.

material (Figure 5). A lozenge incision was made, under local anesthesia and sedation; the tube, after antibiotic washes, was sunk into the dartos tissue of the scrotum. The skin was closed. Antibiotic therapy was started. After discharge, the patient did not complain any local and general symptoms.

#### Urinary urethral stones

A 76 years old patient with CAD and hyperuricemia, had an IPP in 2004. He had a frequent sexual activity being very satisfied. In 2017 he had an episode of renal colic with hematuria. The medical practitioner (MP) who visited him during the first episode, unaware of the hydraulic prosthesis, at sonography excluded kidney stones but diagnosed a “paravesical liquid cyst”.

The patient the next day continued to suffer pain and hematuria and presented to our clinic. The IPP worked properly. The “paravesical liquid cyst” at sonography revealed to be the prosthetic reservoir that emptied and filled normally. Through palpation and sonography we found 2 round stones obstructing the urethra. Local anesthesia with lidocaine was performed, followed by a small meatal incision that made possible the extraction of the urinary stones (Figure 6). A Foley catheter was inserted till the bladder without any obstacle. After 2 days a flexible cystoscopy excluded other bladder stones. In 2020 the patient continues to utilize the prosthesis.

#### Preputial edema

In the last 3 years we begun again to utilize the infrapubic incision to implant IPP. In 7/ 12 patients we observed, in the first post-op week a significant edema of the foreskin with patient’s discomfort and difficulties in discovering the glans. General and local steroid therapy determined a normalization of the edema in a few weeks. In one patient (Coloplast IPP), the difficulty in discovering the glans persisted after one month and the patient preferred to be submitted to circumcision. We observed this problem also in several patients operated in the past for different indications utilizing the infrapubic incision. We cannot exclude an interruption of lymphatic vessels draining of the penile foreskin due to the “pubic” incision (Figure 7).

#### Altered position of the scrotal pump

In 3 patients we observed, during the first visit after surgery, an irregular positioning of the scrotal pump with difficulty to find and activate it.

##### Case 1

A 54 years-old patient, after IPP, wasn’t able to perceive the pump, to activate and to deflate the cylinders. After several controls without obtaining a correct position of the pump we decided to re-operate on the patient; after antibiotic therapy, re-incision of the scrotum and freeing of the pump from adhesions we positioned it in the correct way. We did not observe any postoperative complication, neither infections.

##### Case 2

A 72 years-old patient, after IPP, wasn’t able to activate the prosthesis because one tube was fixed to the pump and was not possible to detach it even with physical maneuvers performed after local anesthesia. We per-

formed a surgical revision after usual antibiotic therapy. The pump was repositioned in the right way. The patient had no complications. After 4 years the IPP is functioning (Figure 8).

**Case 3**

A 66 years-old patient after radical prostatectomy had in 2012 an IPP with infrapubic access. He observed that the pump was positioned transversally, at the base of the scrotum, but normally functioning. In front of the proposal to re-operate on to position the pump in the correct way, the patient refused due to the risks of infection. After 3 years the patient was however satisfied.

**Case 4**

A 60 years-old hypertensive patient, after IPP observed a progressive formation of a painful liquid swelling of the scrotum. The ultrasound was not conclusive so we performed surgery, after antibiotic therapy, and we found a very large amount of clear fluid collected into the pseudo capsule covering the pump (Figure 9). We removed the capsule and repositioned the pump between the testicles. No complication was registered.

**Pump malfunction and substitution**

Two patients (56 and 60 years old) after IPP complained of malfunction of the pump that doesn't inflate the cylinders. In OR, after incision of the scrotum, we observed that the tubes were broken at their base, near the pump, with leaking of the fluid. In both patients we disconnected the pumps, checked the correct function of cylinders and reservoir and we substitute only the pump making three new tube connections. No infection occurred; the IPPs worked perfectly and the patients were both satisfied after 2 and 4 years (Figure 9).

**INFECTIONS**

The risk of infection continues to be the main problem for PPS. Surgeons and medical companies tried to find the better strategy, the medical behavior, the drugs, the instruments to reduce the incidence of infective compli-

cations (14-16). In our series we recorded 22 cases of severe infections in 6/399 MPP (1.5%) and in 16/177 IPP (8.9%) that were not managed with complex antibiotic treatment.

We reported most of our complications in patients with DM (16/22, 73%) even if we tried to perform Penile Implant after regularization of glyceemic values with insulin or oral antidiabetics.

**Scrotal pump abscess**

**Case 1**

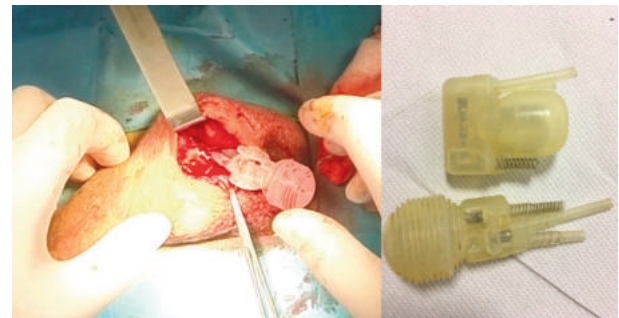A 72 years-old patient with DM, 2 years after an IPP implantation, begun to report scrotal pain, fever, and leakage of purulent material from the peno-scrotal scar. We informed the patient of the possible removal of the prosthesis but we started the treatment by cleaning the scrotal wound with gentamicin 80 mg and iodopovidone solution twice a day for 7 days and by starting systemic antibiotic treatment.

After 7 days the leakage of purulent secretion stopped and the wound closed. The patient begun to utilize the pump after 15 days. Since then he has no further complaints (Figures 10A, B).

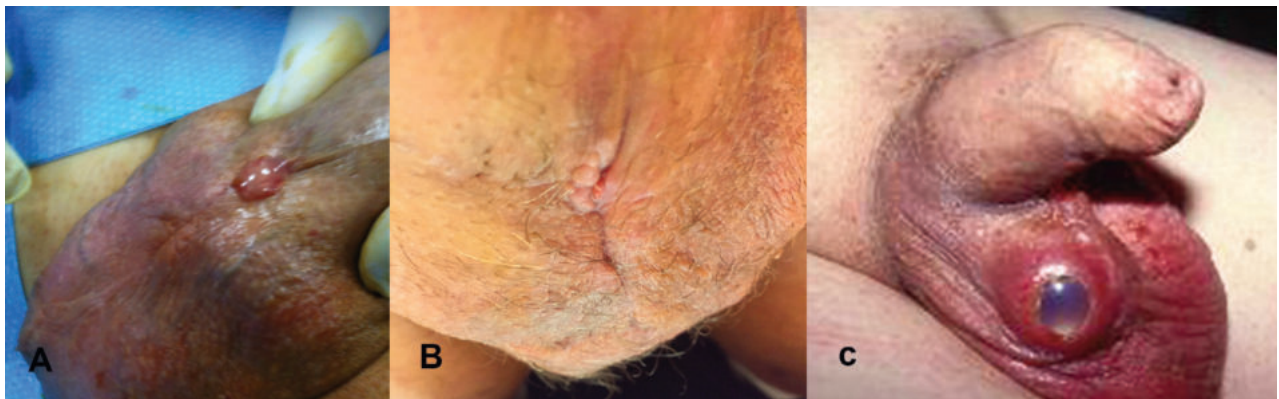**Case 2**

A 58 years-old patient with DM and CAD, after an IPP for PD and ED, begun to experience pain in the scrotum

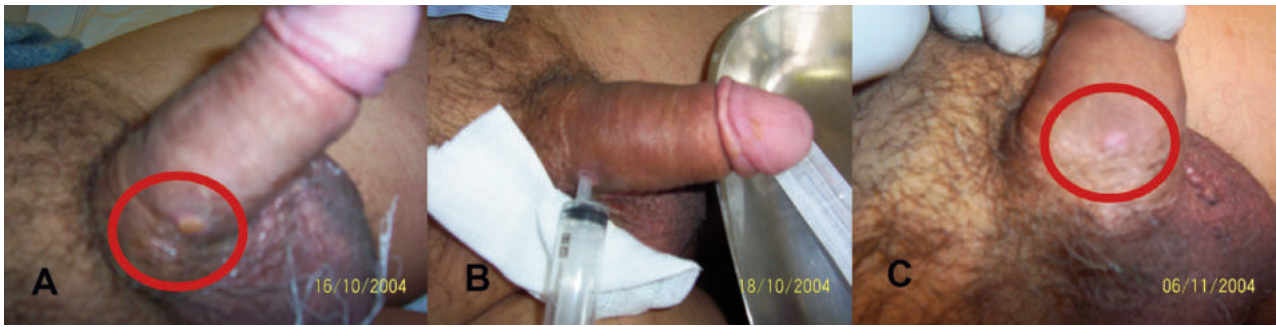**Figure 9.** Removal of the pumps of inflatable penile prosthesis and their substitution after 3 years.



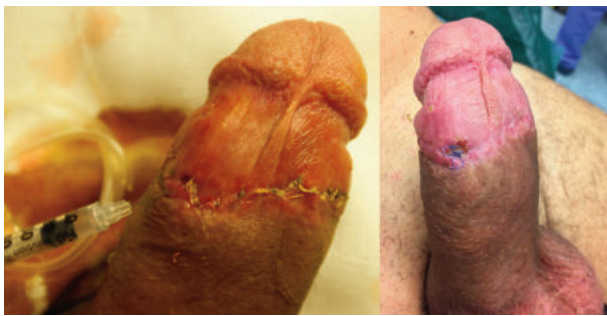**Figure 10.** A: Painful scrotum and purulent secretion from the pump; B: After local infusion of gentamicin for 7 days closure of the skin with complete recovery; C: Purulent abscess of the scrotal pump in a patient with diabetes mellitus after 36 days from implantation of inflatable penile prosthesis. Removal of the inflatable penile prosthesis.



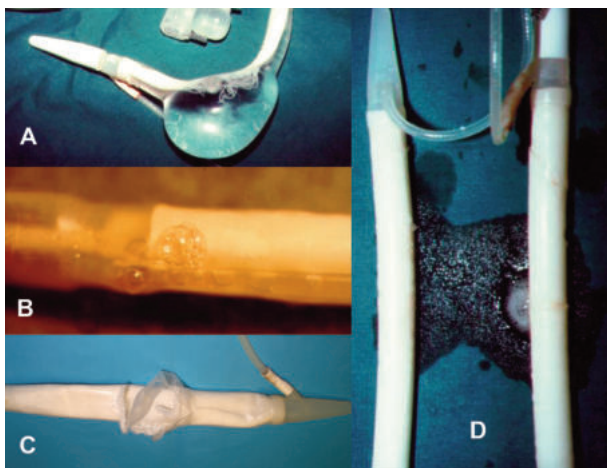
**Figure 11.** A: Purulent secretion at the basis of the penis 15 days after implantation of inflatable penile prosthesis; B: Repeated local instillations of antibiotic; C: Complete resolution after 20 days.



**Figure 12.** Malleable penile prosthesis implantation and plaque grafting in a 42 years old patient with Peyronie's disease. Initial leakage of serous-coprusculated secretion. Repeated instillations of antibiotic with complete resolution.



**Figure 13.** Malfunction of inflatable penile prosthesis. A: Aneurism of inflatable penile prosthesis AMS700Ultrax cylinder; B: Leakage of fluid from one cylinder of AMSHydroflex; C: Rupture of the outer layer of AMS700Ultrax; D: Leakage of fluid from one cylinder of AMS700.



and septic fever after 30 days. In few days, scrotal pump appeared outside with purulent secretion. We decided to remove the entire IPP on suspicion of contamination of the whole system. The patient for economical reasons refused a new IPP (Figure 10C).

### Case 3

A 62 years-old patient with DM and CAD, in 2004 was submitted to AMS700 implant. Usual antibiotic treatment was administered. After 15 days the patient begun to complain pain at the basis of the penis, septic fever, and a yellowish lesion at the basis of the penis.

A yellowish creamy purulent secretion began to drain. When we inflated the cylinders the volume of purulent fluid drain increased.

Suspecting an infection of the IPP we suggested to the patient the possibility to explant the IPP. The patient, mainly for economical reasons, refused such an immediate hypothesis. We started with a local injection of iodopovidone and gentamicin 150 mg. After injecting fluid we inflated the cylinders forcing the fluid to exit. We repeated this maneuver several times, every 8 hours. The quantity of drain was reduced and we injected only gentamicin. After 12-15 days the skin opening closed and we maintained the cylinders fully inflated for 10 days without secretion, fever and pain. We had the possibility of checking the patient regularly till 2012 (Figures 11A, B, C).

### Case 4

A 45 years-old patient presented with PD, curvature and ED. He was submitted to subcoronal incision, excision of the plaque, heterologous grafting and MPP. After 2 weeks he developed fever, pain at the glans and pouring of purulent fluid. We organized an explant and in meanwhile, we decided to inject a solution of gentamicin and iodopovidone every 8 hours into the hole of the suture. After one week, pain and fever were decreased and the fluid drainage stopped. After 2-3 days without secretion we closed the hole. (Figures 12A, B). After 2 years the patient is fully satisfied.

### MALFUNCTION

We recorded malfunctions in 13/17 mono-component IPP (2 leakings of fluid from the cylinders, 3 ruptures of the outer layer and 8 ineffective pumps). In multi-component IPP we recorded aneurysmatic dilation (Figure 13A) of the cylinders in 2 AMS700Ultrax, 3 leakage of fluid at the cylinder level (Figure 13B, D), 3 ruptures of the connecting tubes and 4 ruptures on the outer layer (Figure 13C).

## REMOVAL

We had to remove most (13/17; 76.4%) of single component IPP (AMS Hydroflex and Dynaflex), for malfunction. For the high percentage of malfunctions these prostheses have been retired from the market (19).

We explanted in only 2 patients the broken pump of IPP reconnecting the tubes and refilling the reservoir. In 23/160 (14.3%) IPP the whole system was removed for malfunction or infections. In 15/168 (8.9%) cases we observed infections non treatable with medical therapy. In 6/144 (4.1%) MPP and in 23/177 (12.9%) IPP we registered infections with subsequent removal of all parts of the IPP. In 2 pts we re-implanted the IPP after 3 months and MPP in 2 pts. In the last 3 years, probably due to the selection of the patients, the skill of the surgical team, the shortening of operating procedures and the improved prosthetic materials the number of complications has greatly reduced.

## CONCLUSIONS

The event of complications related to PPS is still present. Our clinical and surgical experience confirms that with experience some complications tend to decrease as is the case of all surgical practices. Particularly, we never observed major complications reported in other series as perforations of adjacent organs (20). The problem of infections and malfunctions of IPP persists and could always lead to the removal of prostheses which for the patient and surgeon always represents a bad and sad defeat. We were able to verify that some technical or infectious complications could be resolved with a limited surgery without necessarily having to perform an explant. We also believe that a close relationship between patient and surgeon is extremely important both to manage the course of the patient with penile prosthesis and to face and resolve possible complications.

## REFERENCES

1. Pearman RO. Insertion of a silastic penile prosthesis for the treatment of organic sexual impotence. *J Urol.* 1972; 107:802-6.
2. Scott FB, Bradley WE, Timm GW. Management of impotence erectile. Use of inflatable prostheses. *Urology.* 1973; 2:80-82.
3. Small MP, Carrion HM, Gordon JA. Small Carrion penile prosthesis. New implant for management of impotence. *Urology.* 1975; 5:479-86.
4. Pozza D, Rossello Barbara M, Carrion H. L'utilizzazione del Cavernotomo di Carrion-Rossello per l'impianto di protesi intracavernose. *Acta Urol Ital.* 1993; 2:87-8.
5. Ehlers M, McCormick B, Coward RM, Figler BD. Innovating incrementally: development of the Modern Inflatable Penile Prosthesis. *Curr Urol Rep.* 2019; 20:4.
6. Scherzer ND, Dick B, Gabrielson AT, Alzweri LM, Hallstrom WJG. Penile prosthesis complications: planning, prevention, and decision making. *Sex Med Rev.* 2019; 7:349-59.
7. Bayrak O, Erturhan S, Seckiner I, et al. Comparison of the patient's satisfaction underwent penile prosthesis; Malleable versus Ambicor: single center experience. *Arch Ital Uro Androl.* 2020; 92:25-9.
8. Mulcahy JJ, Kramer A, Brant WO, et al. Current management of

penile implant infections, device reliability, and optimizing cosmetic outcome. *Curr Urol Rep.* 2014; 15:413-6.

9. Dhabuvala C. In vitro assessment of antimicrobial properties of rifampicin-coated Titan Coloplast penile implants and comparison with inhibizone. *J Sex Med.* 2010; 7:3516-9.

10. Lokeshwar SD, Madhusoodanan V, Kava B, Ramasamy R. A surgeon guide to various antibiotic dips available during penile prosthesis implantation. *Curr Urol Rep.* 2019; 20:11.

11. Christodoulidou M, Pearce I. Infection of penile prostheses in patients with diabetes mellitus. *Surg Infect.* 2016; 17:2-8.

12. Jani K, Smith C, Delk JR 2<sup>nd</sup>, et al. Infection retardant coating impact on bacterial presence in penile prosthesis surgery: a multicenter study. *Urology.* 2018; 119:104-8.

13. Madiraju SK, Wallen JJ, Rydelek SP, et al. Biomechanical studies of the inflatable penile prosthesis: a review. *Sex Med Rev.* 2019; 7:369-75.

14. Wilson SK, Delk JR. Historical advances in penile prostheses. *Int J Imp Res.* 2000; 12:101-7.

15. Whelan P, Levine LA. Additional procedures performed at time of penile prosthesis implantation: a review of current literature. *Int J Imp Res* 2020; 32:89-98.

16. Pozza D, Pozza M, Musy M, Pozza C. 500 penile prostheses implanted by a surgeon in Italy in the last 30 years. *Arch Ital Urol Androl.* 2015; 87:216-21.

17. Hebert KJ, Kohler TS. Penile prosthesis infection: myths and realities. *World J Mens Health.* 2019; 37:276-87.

18. Kramer A, Goldmark E, Greenfield J. Is a closed-suction drain advantageous for penile implant surgery? The debate continues. *J Sex Med.* 2011; 8:601-12.

19. Anafarta K, Yaman O, Aydos K. Clinical experience with Dynaflex penile prostheses. *Urology.* 1998; 52:1098-100.

20. Deger M, Kizilgok B, Aridogan IA, Tansug MZ. Management of erosion of inflatable penile prosthesis reservoir into bladder. A different approach. *Arch Ital Urol Androl.* 2019; 91:43-45.

## Correspondence

Diego Pozza, MD (Corresponding Author)  
Studio di Andrologia e di Chirurgia Andrologica  
Via B. Gozzoli, 82C, 00142 Roma (Italy)  
diegpo@tin.it

Andrea Marcantonio, MD  
Via B. Gozzoli, 82, 00142 Roma (Italy)  
md.andreamarcantonio@gmail.com

Augusto Mosca, MD  
Via Tuscolana 2, 00040 Frascati (Italy)  
moscaugusto@gmail.com

Carlotta Pozza, MD  
Via B. Gozzoli, 82, 00142 Roma (Italy)  
carlotta.pozza@gmail.com