

A giant adrenal hemorrhagic pseudocyst mimicking a parapelvic renal cyst: A case report and review of the literature

Erhan Ates¹, Arif Kol¹, Gokce Su Gokce², Ahmet Emre Yildiz¹, Haluk Erol¹

¹ Department of Urology, Aydin Adnan Menderes University School of Medicine, Aydin, Turkey;

² Department of Pathology, Aydin Adnan Menderes University School of Medicine, Aydin, Turkey.

Summary Adrenal pseudocysts are rare, nonfunctional, asymptomatic cystic masses that originate from the adrenal gland and are usually located in the suprarenal area. They are usually incidentally discovered during imaging, but diagnosis can be challenging because they are similar to benign and malignant cystic lesions of the adrenal gland and adjacent organs. We describe a giant, adrenal hemorrhagic pseudocyst that was atypically located, extending from the middle to the lower poles of the kidney, admixed with a renal cortical cyst.

KEY WORDS: Adrenal gland; Adrenal hemorrhagic pseudocyst; Mimicking; Renal cyst.

Submitted 2 March 2020; Accepted 15 March 2020

INTRODUCTION

Adrenal gland cysts are rare lesions that are frequently noted today because of the widespread use of imaging modalities. The incidence rate is 0.06-0.18% (1). The cysts are divided into four types: parasitic (7%), epithelial (9%), pseudocystic (39%), and endothelial (45%). Adrenal pseudocysts are benign nonfunctional masses originating from the cortex or medulla of the adrenal gland. The luminal face is not paved with epithelium, and the walls contain dense fibrous connective tissue and (often) calcified and (sometimes) hyalinized areas (2). The cysts are mostly asymptomatic (being nonfunctional) and thus incidentally recognized (3). The masses are mostly small and located in the suprarenal region, but they may be confused with benign and malignant lesions of the adrenal gland and adjacent organs (4, 5). We describe a huge (19 cm diameter) adrenal hemorrhagic pseudocyst that was atypically located, extending from the middle to the lower poles of the kidney, admixed with a renal cortical cyst.

CASE PRESENTATION

A 21-year-old female with left flank pain 3 weeks in duration was referred to our clinic with a diagnosis of a giant parapelvic renal cyst. Her medical history revealed no additional disease, no anticoagulant medication, and no trauma. On physical examination, a palpable mass was detected on the left side. Routine laboratory tests including a complete blood count, biochemistry, and liver function tests were normal; the urine was sterile.

Ultrasonographic imaging revealed a septate cystic mass in the left kidney. Contrast-enhanced abdominal *computed tomography* (CT) revealed a septate hypodense cystic lesion with a somewhat thickened, well-circumscribed, non-solid component 14×9×19 cm in dimension extending from the middle-lower pole of the left kidney to the pelvic region (Figure 1). The attenuation was 16 Hounsfield units (HU) without and 17 HU with contrast. The lesion was considered a Bosniak type II renal cyst. Decortication was planned and a lumbar incision was created. The Gerota fascia was opened and a giant cystic mass was observed in the medial, left inferior region of the renal hilum. When the thick fibrous cyst wall was resected from the anterior wall of the hilum, a thick viscous brown liquid with hemorrhagic characteristics was released. We biopsied a frozen section of the cyst wall. The result was benign; we proceeded with decortication. Pathological examination revealed a cystic structure featuring intense bleeding and histiocytes that were richly granulated. Cells/cell groups with clear cytoplasm were linearly arranged along the cyst wall (Figure 2A). Multiple blocks containing cells with clear cytoplasm were negative for cytokeratin, cytokeratin 7, CD68, EMA, vimentin, and CD10 (Figure 2B). However, melan-A staining was strong to diffuse, and inhibin and calretinin stained positively (Figure 3). No sample contained epithelium. The findings were compatible with an adrenal hemorrhagic pseudocyst.

DISCUSSION

The classification of adrenal cysts was modified by Foster in 1966; four types were recognized: parasitic (7%), epithelial (9%), pseudocystic (39%), and endothelial (45%) (2). Pseudocysts are fibrous walled cysts lacking an epithelium and may develop because of vascular malformation, bleeding of the adrenal gland, or cystic degeneration of a primary adrenal or vascular neoplasm (6). Although pseudocysts are the second most common type of adrenal cysts encountered in the clinic, they constitute the largest group (60%) of cysts encountered intraoperatively (7). They are usually asymptomatic and thus incidentally diagnosed (3). Pseudocysts are more likely to be symptomatic than other adrenal cysts (8). Although the cysts are usually small, large cysts can cause infection, rupture, hemorrhage, and compression

No conflict of interest declared.

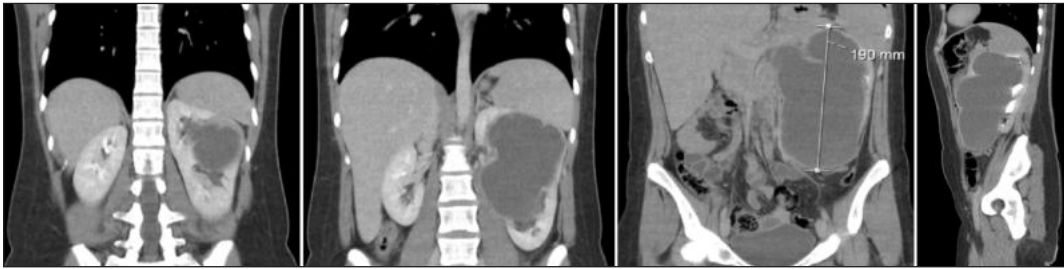

Figure 1. Cystic mass on the left side in the computed tomography sections.

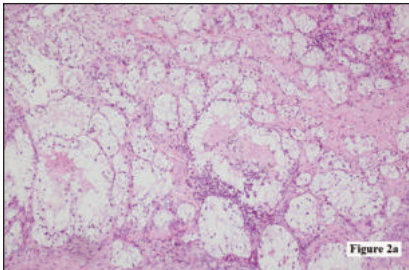
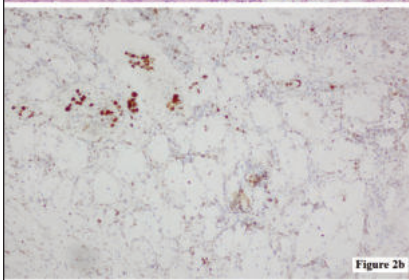


Figure 2. 2A. Large cells with different sizes of vacuolar cytoplasm and some hyperchromatic cells are observed together;



2B. Cells with vacuolar clear cytoplasm were not stained with CD68.

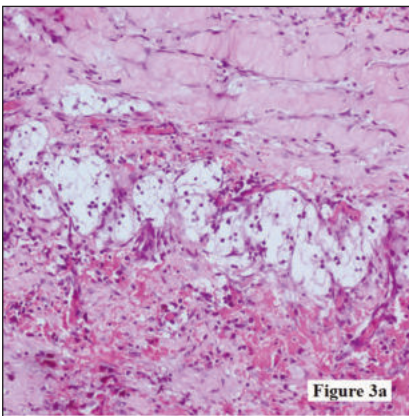


Figure 3. Histiocyte-like cells with vacuolar cytoplasm and melanin A positive in these cells.

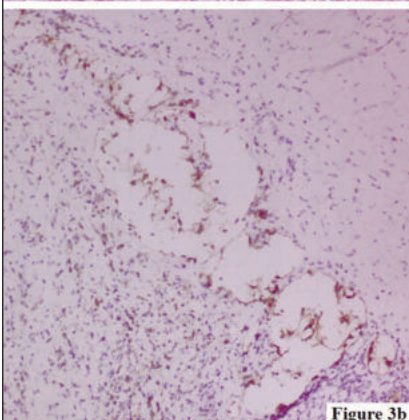


Figure 3b

cystic lesions (1). Computed tomography, which is 100% sensitive in terms of identifying small tumors, is the gold standard diagnostic method for adrenal masses (9).

The radiological characteristics of adrenal pseudocysts are typical. In CT, most present as uni- or multi-locular cystic lesions with a thin but well-confined wall filled with a liquid similar to water. However, unlike simple cysts, they may exhibit intracavitary blood and septa extending into the cystic cavity, and a solid component that may be focally calcified, inviting confusion with adrenal tumors. In most cases, the lower wall of the cyst is concave or straight, following the contour of the top kidney pole. The renal parenchyma is separated from the cyst wall by anywhere from a few centimeters to 20-30 mm. Thus, adrenal lesions can be differentiated from renal cysts (which are more common) and cystic tumors of the kidney (10). However, it is not always possible to definitively diagnose adrenal pseudocysts, particularly large lesions, via imaging. The differential diagnosis includes malignant adrenal tumors; cystic pathologies of the spleen, liver, and kidney; cystic neoplasms of the pancreatic tail; retroperitoneal mucinous cystic neoplasms; and mesenteric and urachal cysts (5, 11)

There are several reasons why an adrenal pseudocyst may be radiologically diagnosed as a renal cyst. An adrenal cyst may develop from an adrenal tumor. In addition, a cyst developing in an adrenal gland that is heterotopically located in the kidney may be wrongly radiologically diagnosed (5). In addition, an adrenal cyst may originate from congenital, adrenal residual tissue or intrarenal, accessory adrenal tissue (12).

Surgical excision is recommended for all adrenal lesions larger than 5 cm in diameter and functional adrenal pseudocysts that may be malignant (13). Some studies have found that adrenal cysts < 4 cm in diameter may also be malignant (9). CT follow-up of lesion size is recommended after a few months (14). Open surgery is preferred because masses larger than 6 cm in diameter may be malignant and open surgery facilitates mass control (15). However, some authors report that a laparoscopic approach is safe in any benign and malignant adrenal mass (16, 17).

There are even studies reporting that the transumbilical approach for laparoendoscopic single-site adrenalectomy for adrenal tumors is a viable and safe alternative to standard laparoscopic adrenalectomy (18). Upon macroscopic examination of surgically resected cysts, endothelial cysts are thin-walled, multiloculated, and contain yellow serous fluid; as in our case, pseudocysts are usually thick-walled, unilocular, and filled with blood or a yellow-brown amorphous liquid (19).

of surrounding organs (3). The increased use of imaging modalities has increased the detection rate of adrenal

CONCLUSIONS

Adrenal pseudocysts, which are usually asymptomatic and incidentally diagnosed, may become symptomatic because of infection, rupture, haemorrhage, or (when large) compression of surrounding organs. Imaging may be misleading in terms of diagnosis. Benign and malignant masses of adjacent organs, particularly the adrenal gland and kidney, should be kept in mind during differential diagnosis. A definitive diagnosis requires pathological examination after surgical excision.

REFERENCES

1. Sebastino S, Zhao X, Deng F, et al. Cystic lesions of the adrenal gland: our experience over the last 20 years. *Hum Pathol.* 2013; 44:1797-1803.
2. Foster DG. Adrenal cysts: review of the literature and report of a case. *Arch Surg.* 1966; 92:131-143.
3. Papaziogas B, Katsikas B, Psaralexis K, et al. Adrenal pseudocyst presenting as acute abdomen during pregnancy. *Acta Chir Belg.* 2006; 106:722-725.
4. Yue CT, Liao A, Huang P, et al. A large adrenal pseudocyst mimicking malignant intraabdominal tumor: a case report. *Zhonghua Yi Xue Za Zhi (Taipei).* 1997; 60:321-325.
5. Fan F, Pietrow P, Wilson LA, et al. Adrenal pseudocyst: a unique case with adrenal renal fusion, mimicking a cystic renal mass. *Ann Diagn Pathol.* 2004; 8:87-90.
6. Mohan H, Aggarwal R, Tahlan A, et al. Giant adrenal pseudocyst mimicking a malignant lesion. *Can J Surg.* 2003; 46:474.
7. Groben PA, Roberson IB. Immunohistochemical evidence for the vascular origin of primary adrenal pseudocysts. *Arch Pathol Lab Med.* 1986; 110:121.
8. Erickson LA, Lloyd RV, Hartman R, et al. Cystic adrenal neoplasms. *Cancer.* 2004; 101:1537-1544.
9. Yip L, Tublin ME, Falcone JA, et al. The adrenal mass: correlation of histopathology with imaging. *Ann Surg Oncol.* 2010; 17:846-852.
10. Lockhart ME, Smith JK, Kenney PJ. Imaging of adrenal masses. *Eur J Radiol.* 2002; 41:95-112.
11. Marwah S, Marwah N, Garg S, et al. Adrenal pseudocyst mimicking cystic neoplasm of pancreatic tail. *Clin J Gastroenterol.* 2011; 4:262-265.
12. Mitchell N, Angrist A. Adrenal rests in the kidney. *Arch Pathol.* 1943; 35:46-52.
13. Wedmid A, Palese M. Diagnosis and treatment of adrenal cyst. *Curr Urol Rep.* 2010; 11:44-50.
14. Passoni S, Regusci L, Peloni G, et al. A giant adrenal pseudocyst mimicking an adrenal cancer: Case report and review of the literature. *Urol Int.* 2013; 91:245-258.
15. Stimac G, Katusic J, Sucic M, et al. A giant hemorrhagic adrenal pseudocyst: case report. *Med Princ Pract.* 2008; 17:419-421.
16. Ramacciato G, Mercantini P, La Torre M, et al. Is laparoscopic adrenalectomy safe and effective for adrenal masses larger than 7 cm? *Surg Endosc.* 2008; 22:516-521.
17. Abate D, Giusti G, Caria N, et al. Surgical approach to adrenal ganglioneuroma: Case report and literature review. *Arch Ital Urol Androl.* 2018; 90:145-146.
18. Carvalho JA, Nunes PT, Antunes H, et al. Transumbilical laparoendoscopic single-site adrenalectomy: A feasible and safe alternative to standard laparoscopy. *Arch Ital Urol Androl.* 2019; 91:1-4.
19. Carvounis E, Marinis A, Arkadopoulos N, et al. Vascular adrenal cysts: a brief review of the literature. *Arch Pathol Lab Med.* 2006; 130:1722-1724.

Correspondence

Erhan Ates, MD, Assistant Professor of Urology (Corresponding Author)
drerhanates@yahoo.com

Arif Kol, MD, Assistant Professor of Urology
drarifkol@gmail.com

Ahmet Emre Yildiz, MD, Urology
aemreyildiz@gmail.com

Haluk Erol, MD, Professor of Urology
halukerol@yahoo.com

Department of Urology, Aydin Adnan Menderes University
School of Medicine, 09010, Aydin (Turkey)

Gokce Su Gokce, MD
gkc.gkc@windowslive.com
Department of Pathology, Aydin Adnan Menderes University School
of Medicine, Aydin (Turkey)