

# Late urinary bladder metastasis from breast cancer

Aldo Franco De Rose<sup>1</sup>, Federica Balzarini<sup>1</sup>, Guglielmo Mantica<sup>2</sup>, Carlo Toncini<sup>3</sup>, Carlo Terrone<sup>1</sup>

<sup>1</sup> Department of Urology, Policlinico San Martino Hospital, University of Genoa, Italy;

<sup>2</sup> Department of Urology, San Raffaele Turro Hospital, San Raffaele University, Milan, Italy;

<sup>3</sup> Department of Pathology, Policlinico San Martino Hospital, University of Genoa, Italy.

**Summary** Introduction: Breast cancer (BrC) is the most common non-dermatologic cancer in women.

It frequently metastasizes to lung, liver and bone, while the urinary bladder is considered as an unusual site for BrC metastases.

Materials and methods: Four years after her first oncologic surgical approach, a known BrC patient complained of a left flank pain, dysuria and urgency. Computed tomography (CT scan) imaging showed an irregular thickening of the left bladder wall and bilateral hydronephrosis.

Results: A bladder metastases from BrC was diagnosed based on a histological examination of a transurethral resection of the bladder (TURB-T) specimen.

Conclusions: In patients with a history of BrC, urinary bladder screening is not needful. However, if low urinary symptoms persist, an evaluation of the bladder should be considered to rule out metastatic involvement.

**KEY WORDS:** Bladder cancer, Breast cancer; Bladder metastasis; Breast cancer metastasis.

Submitted 5 January 2019; Accepted 25 January 2019

## INTRODUCTION

Breast adenocarcinoma is the most frequently diagnosed malignancy in women, with more than 1.6 million new cancer cases diagnosed worldwide (25% of all cancers). BrC remains the leading cause of death for cancer in women, despite increased screening programs and advanced therapies, and its mortality is mainly due to metastatic disease. Common sites of BrC metastasis are lung, liver, bone, lymph nodes and skin while other organs are less frequently involved. Bladder metastasis from solid tumours are rare, accounting for up 4.5% of all bladder neoplasms (1). Most bladder metastasis are due to direct infiltration from peripheral organs, such as colon and rectum, prostate and cervix. Metastasis from distant organs are extremely rare and reported sporadically. The most common are related to stomach and lung tumours as well as melanomas. BrC accounts for about 2.4% cases of all bladder metastasis (1). In most instances, bladder metastases from BrC are associated with other metastatic involvement of pelvic organ with a very poor survival (2, 3).

## CASE REPORT

We present the clinical case of a 57 years-old woman with a negative family history regarding BrC. At the end

of 2013 she presented with painless right breast mass. A mammogram demonstrated a large high dense soft mass lesion in the upper outer quadrant of the right breast (maximum diameter 16 cm). A Tru-cut needle biopsy showed 2 foci of invasive ductal carcinoma of 10 and 6 mm (immunohistochemistry was estrogen receptor (ER) 95% - progesterone receptor (PgR) 40% - Ki67 40% - human epidermal growth factor receptor 2 (HER2) negative and ER 95% - PgR 10% - Ki67 15% - HER2 negative, respectively). Tumour clinical stage was T1cN1M0. Neoadjuvant chemotherapy was started (FEC-75 q21 x4 + Paclitaxel 80 mg q7x12) and a right mastectomy with ipsilateral axillary lymph node dissection was done in August 2014. Pathology revealed invasive ductal carcinoma (IDC) with some elements of atypical ductal hyperplasia (ADH-DIN1b) and negative margins. All six removed lymph nodes were involved, one of which presented perineural invasion. Tumour pathological stage was pT1c(m)/G2/N2a(6+/6)/M0 - luminal B (stage IIIA). ER and PgR were positive (ER 95%, PgR 50%), Ki67 1% and HER2 were negative.

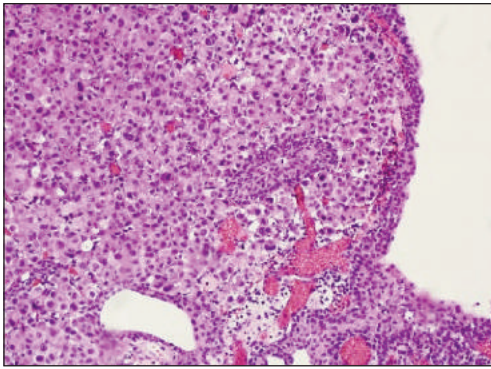
The patient underwent adjuvant radiotherapy from November to December 2014 and hormonal adjuvant treatment with Letrozole was administered from September 2014 to August 2016. She had been on regular follow-up every 6 months until November 2016, when the patient suffered from left subcutaneous inguinal mass. Excisional biopsy showed a metastasis from the primary BrC with negative margins. Immunohistochemistry showed ER positive (100%), PgR negative, Ki67 40% and HER2 negative.

In January 2017, a follow-up total-body CT scan displayed left enlarged inguinal lymph nodes. Bone scintigraphy was negative. From February 2017, Letrozole was substituted with Fulvestrant, which was continued until April 2018. At the end of April 2018 a new CT scan showed increasing of lymph node disease (left common iliac lymph nodes, internal obturator lymph nodes and left inguinal lymph nodes).

The patient took part in the phase II trial of the CDK4/6 inhibitor Palbociclib as single agent or in combination with the same endocrine therapy (ET) received prior to disease progression, in patients with hormone receptor positive (HR+) HER2 negative metastatic breast cancer (mBrC) (TREnd trial).

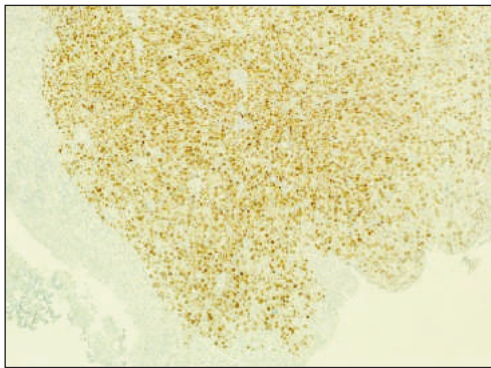
At the end of the first cycle she presented to our attention with left flank pain, dysuria, urge incontinence and

No conflict of interest declared.



**Figure 1.**

The submucosal layer of the urinary bladder is expanded by medium and large size atypical cells, poorly differentiated, that diffusely infiltrate the muscularis propria. The transitional epithelium is intact, without any dysplastic and neoplastic changes or relation/connection to the neoplastic elements. Hematoxylin-eosin stain (20x).



**Figure 2.**

Immunohistochemistry staining is diffusely positive for estrogen receptor in neoplastic cells, otherwise the transitional epithelium of urinary bladder is completely negative (20x).

increasing creatinine. Abdominal CT scan displayed thickening of the posterior-left bladder wall with bilateral grade I-II hydronephrosis. Cystoscopy showed inflammatory changes and suspicious bladder wall thickening. *Transurethral resection of bladder tumour* (TURB-T) was performed. Pathology revealed muscular invasive anaplastic cells consistent with the known primary breast adenocarcinoma. Microscopically, the bladder layers showed a diffuse infiltration by large size carcinomatous cells displaying round nuclei, distinct nucleoli with a diffuse pattern, without obvious ductal or glandular structure. The urinary transitional epithelium was intact and ulcerated, without dysplastic or neoplastic changes. (Figures 1, 2) The muscular layer was deeply involved. Neoplastic cells were ER and PgR positive, Cytokeratin 7 positive, GCDPF 15 positive and Mammoglobin positive. Ki67 immunostaining was markedly increased. Nowadays, the patient is continuing the therapy with Palbociclib and Fulvestrant. A 3-months follow-up cystoscopy and urine cytology didn't show any bladder recurrence.

## CONCLUSIONS

Bladder metastases from BrC are uncommon. However, literature reveals an increase of such occurrence over the

last few years, probably due to better imaging techniques. Most cases are diagnosed after the diagnosis of primary BrC and are usually associated with other metastatic sites. Although routine screening of the lower urinary tract is not mandatory for all patients, women presenting with urinary symptoms should be evaluated in order to exclude a bladder metastasis. The imaging should include ultrasound, CT and/or MRI scan. Once imaging and/or cystoscopy show a bladder neoplasm in a patient with a BrC history, a TURB-T is mandatory. Chemotherapy and/or hormonal therapy, if not already ongoing, should be started as soon as a diagnosis is confirmed. Generally, the prognosis is poor unless bladder metastases represents the only metastatic site (3).

Our reported case confirms that bladder metastases may occur late after the diagnosis of the primary tumours. Such data support the need for accurate urological follow-up and early intervention if such clinical state is suspected.

## DISCUSSION

Secondary tumours of the urinary bladder are rare and the majority of them are due to the direct extension of another pelvic neoplasm (4). The minority are metastases originating from lymphoma or from solid tumour such as lung, breast cancers and melanoma.

Possible mechanisms are through vascular and lymphatic dissemination or direct retroperitoneal invasion (5).

To date, approximately 55 cases of urinary bladder metastasis from BrC have been reported in literature (3). In the majority of reported cases, the urinary bladder lesions from BrC were part of a systemic dissemination and multiple organ involvement. This indicates that bladder metastases are usually late complications of primary disease (6). However, a solitary metastasis to the urinary bladder had also been reported (7, 8). Metastases start from the outer layer of bladder wall and advance towards the bladder lumen (9). Urinary symptoms correlate with the advancement of this growth. Early stages of BrC bladder metastases might be asymptomatic, while the most common presenting symptoms are *low urinary tract symptoms* (LUTS), flank or abdominal pain, hydronephrosis, and haematuria (9).

Our patient did not present with macroscopic haematuria. Instead, she complained from recurrent dysuria, urge incontinence and progressive renal failure. Flank pain was later the major weakening symptom that allowed the investigation through CT scan imaging.

Diagnostic workshop needs imaging (ultrasound and CT scan), direct visualisation of the bladder mucosa by cystoscopy, and histological confirmation of a specimen obtained by biopsy or TURB-T. Cystoscopy findings vary and comprehend solid tumour, inflammatory patches, and thickened bladder wall with intact overlying mucosa. In our patient cystoscopy revealed suspicious bladder wall thickening and non-specific inflammatory areas. *Feldman et al.* affirm that assessment should also include further imaging evaluation, citing a case with negative cystoscopy despite strong evidence of bladder wall involvement from the patient's symptoms, ultrasound and CT scan (10). *Magnetic resonance imaging*

(MRI) scan would help in definitive confirmation of neoplastic bladder infiltration and it would help in precise local cancer staging. PET-CT scan may reveal other metastases. Patient assessment should incorporate check of blood serum CA 15-3 level which remains the most sensitive tumour marker in BrC follow-up (11).

The metastatic pattern of BrC may be related to the histologic type of cancer (10). It has been suggested that *infiltrating lobular carcinoma* (ILC) has a higher bladder metastatic rate in comparison with *infiltrating ductal carcinoma* (IDC) representing approximately 90% of BrC (3). Some reports have related the likelihood of developing bladder metastases with the presence of positive lymph nodes at first diagnosis of BrC or with steroid treatment (11). Patients who have been administered prolonged steroid therapy may develop unusual metastases due to the possible influence of immune-suppressive effects on carcinoma spreading routes.

Immunohistochemistry is an indispensable adjunct in the correct diagnosis of metastatic tumours in all sites. Common markers for suspected breast tumours include the expression of cytokeratin, CK-7, CK-18, CK-19, CK-20, GCDFP-15 and ER/PgR (8). In the present case, positive CK-7 and CD-138, and negative CD-20 helped the pathologist in confirming the diagnosis of metastatic BrC. Some authors reported differences in hormonal (ER and PgR) and HER2 expression between primary and metastatic tissue, with discordance rates ranging from 24 to 39% (6, 12).

Bladder metastases from BrC usually occurs a few months after the initial diagnosis of the primary tumour, but they might also occur years later (3, 10). However, it is possible of bladder metastases being present at the time of first diagnosis of BrC, like in the case reported by *Shah et al.* (8), whereby acute renal failure due to the ureteral obstruction was the presenting sign. In our patient the bladder metastasis was identified 4 years after the initial diagnosis of BrC.

The standard treatment of urinary bladder metastases from BrC involves chemotherapy and hormonal therapy. Radiotherapy might be used only to control bladder

bleeding. In case of obstructive uropathy, percutaneous drainage or ureteric catheterization should be performed to optimise renal function before starting chemotherapy.

## REFERENCES

1. Bates AW, Baithun SI. The significance of secondary neoplasms of the urinary and male genital tract. *Virchows Arch.* 2002; 440:640-647.
2. Velcheti V, Govindan R. Metastatic cancer involving bladder: a review. *Can J Urol.* 2007; 14:3443-3448.
3. Sanguedolce F, Landriscina M, Ambrosi A, et al. Bladder metastases from breast cancer: managing the unexpected. A systematic review. *Urol Int.* 2018; 101:125-131.
4. Cormio L, Sanguedolce F, Di Fino G, et al. Asymptomatic bladder metastasis from breast cancer. *Case Rep Urol.* 2014; 2014:672591.
5. Pontes JE, Oldford JR. Metastatic breast carcinoma to the bladder. *J Urol.* 1970; 104:839-42.
6. Zagha RM, Hamawy KJ. Solitary breast cancer metastasis to the bladder: an unusual occurrence. *Urol Oncol.* 2007; 25:236-239.
7. Ghaida RA, Ayoub H, Nasr R, et al. Bladder metastasis from primary breast cancer: a case report and literature review. *Cent European J Urol.* 2013; 66:177-84.
8. Shah KG, Modi PR, Rizvi J. Breast carcinoma metastasizing to the urinary bladder and retroperitoneum presenting as acute renal failure. *J Urol.* 2011; 27:135-136.
9. Ramsey J, Beckman EN, Winters JC. Breast cancer metastatic to the urinary bladder. *Ochsner Journal Information.* 2008; 8:208-212.
10. Feldman PA, Madeb R, Naroditsky I, et al. Metastatic breast cancer to the bladder: a diagnostic challenge and review of the literature. *Urology.* 2002; 59:138.
11. Luczyńska E, Pawlik T, Chwalibóg A, et al. Metastatic breast cancer to the bladder case report and review of literature. *J Radiol Case Rep.* 2010; 4:19-26.
12. Lin WC, Chen JH. Urinary bladder metastasis from breast cancer with heterogeneous expression of estrogen and progesterone receptors. *J Clin Oncol.* 2007; 25:4308-4310.

## Correspondence

Aldo Franco De Rose, MD

Federica Balzarini, MD

Carlo Terrone, MD

Department of Urology, Policlinico San Martino Hospital, University of Genoa, Genoa, Italy

Guglielmo Mantica, MD (Corresponding Author)

guglielmo.mantica@gmail.com

Department of Urology, San Raffaele Turro Hospital, San Raffaele University Via Stamira d'Ancona 20, 20127 Milano (Italy)

Carlo Toncini, MD

Department of Pathology, Policlinico San Martino Hospital, University of Genoa, Genoa, Italy