

# Distant subcutaneous spreading of Fournier's gangrene: An unusual clinical identification by preoperative ultrasound study

Lucio Dell'Atti, Daniele Cantoro, Guevar Maselli, Andrea Benedetto Galosi

Department of Urology, University Hospital "Ospedali Riuniti", Ancona, Italy.

**Summary** We present here the first case of successful management via preoperative ultrasonographic (US) study to detect a distant spreading of Fournier's gangrene (FG), which was happened in a 75-year-old man. US study showed the necrotizing infection in the periumbilical region distant 22 cm from the genital tract. A target incision of this periumbilical area and debridement of necrotic tissues was made. Computed tomography (CT) is superior to ultrasonography to confirm the diagnosis of FG and support in surgical management, but a CT evaluation in patients with FG may be limited by the frequent presence of concurrent acute renal failure or patient hemodynamic instability. Ultrasonography is an ideal technique for evaluating patients in bedside settings and can be routinely used in an emergency.

**KEY WORDS:** Fournier's gangrene; Ultrasonography; Computed tomography.

Submitted 6 March 2017; Accepted 27 March 2017

## INTRODUCTION

Fournier's gangrene (FG) is an acute, rapidly progressive necrotizing soft-tissue infection of the external genitalia and perineum (1). If not recognized and treated early, it is associated with high morbidity and mortality (2). In addition to the physical exam, there are several diagnostic procedures that can be used to evaluate this necrotizing infection. Ultrasonographic (US) study allows to evaluate a scrotal pathology or soft tissue collection, and has been shown to identify subcutaneous gas, even prior to the overt development of crepitus on physical exam (3). We here report the first case of successful management via preoperative US study to detect a distant spreading of FG and allow proper surgical debridement.

## CASE REPORT

A 75-years-old male patient presented to our Emergency Department for generalized malaise, fever, appearance of edema, scrotal erythema, and pain symptoms in the perianal region not responsive to the most common anti-inflammatory drugs. The patient's medical history was remarkable for a history of hypertension and diabetes mellitus, diagnosed twenty years ago. On admission, his vital signs were as follows: blood pressure 135/80 mmHg; heart rate 98 bpm and

body temperature 38°C. His blood count showed: haemoglobin level, 11.3 g/dL, white blood cell count, 17.000/mm<sup>3</sup>, and platelet count, 185.000/mm<sup>3</sup>.

C-reactive protein level was 13 mg/dL, glucose 280 mg/dL and creatinine level was 1.4 mg/dL. Physical examination showed genital and perineal swelling, with erythema, edema and necrotic tissue over his scrotum with extension to the perineum (Figure 1A); subcutaneous crepitation was also present. As part of the initial assessment, the patient received an US study that demonstrated marked thickening of the scrotal fascia with edema and high-amplitude echoes, as well as an area of subcutaneous gas in the periumbilical region was discovered distant 22 cm from the genital tract (Figure 1B). However, a contrast-enhanced computed tomography (CT) was performed to differentiate areas of subcutaneous gas in the periumbilical and genital regions (Figure 2). These findings were compatible with Fournier gangrene. Immediate broad spectrum antibiotic administration were initiated. Although the initial vital signs were normal, he rapidly developed septic shock and was emergently taken to the operating room for aggressive surgical therapy including target incision and debridement of necrotic tissues until to be able to contain the progression of the gangrene. The patient was discharged after a flap reconstruction over the scrotum and 28 days of hospitalization. The clinical follow-up was 6 months and showed no signs of infectious or ischaemic complications.

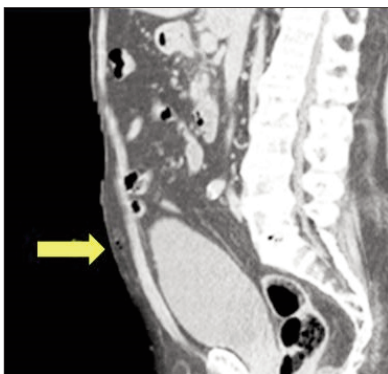
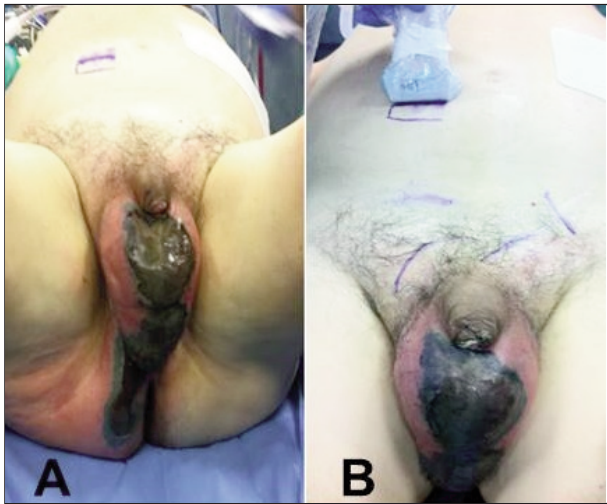
## DISCUSSION

FG was first described by Jean Alfred Fournier, a French venereologist, in 1883. At that time, it was described as abrupt in onset with rapid progression to gangrene, but without a clear aetiology. The disease was noted to occur most commonly in young males (4). Today, FG is most commonly found in middle-aged men (50-60 years) and, to a much lesser extent, in women (2). FG shows vast heterogeneity in clinical presentation, from insidious onset and slow progression to rapid onset and fulminant course. The characteristic of this necrotizing infection is gas production by the bacterial organisms, which can sometimes (but not always) be assessed on physical exam. However,

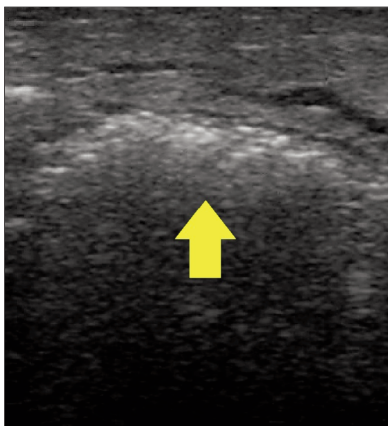
No conflict of interest declared.

**Figure 1.**

Genital and perineal swelling, with edema and necrotic tissue over the scrotum and perineum secondary to Fournier's gangrene (A). Ultrasonographic probe reported an area of subcutaneous gas in the periumbilical region (distant 22 cm from the genital tract, B).



**Figure 2.** Longitudinal scan of contrast-enhanced computed tomography shows a distant subcutaneous spreading of Fournier's gangrene (yellow arrow).



**Figure 3.** The characteristic ultrasonographic features of necrotizing infection comprise subcutaneous multiple echoic spots that show reverberation artefacts, causing "dirty" shadowing that represents gas (yellow arrow).

an early diagnosis is important because immediate surgical debridement and aggressive antibiotic treatment are indicated (1, 3). Thorough physical examination and clinical assessment are favourable for a correct diagnosis of FG, but laboratory studies and imaging can be useful for risk stratification and to identify a potential source, respectively. Radiological exams, including radiography, ultrasonography, and CT, can be of value to assess the extent of disease. Radiography is the least costly option and can, in

some cases, show hyperlucency representing soft-tissue gas before the accompanying clinical crepitations (3). Traditionally, owing to its low cost, ready availability, US study has been the primary modality for imaging of the scrotum and can be utilized to examine the scrotal contents, and determine testicular involvement. Overall, CT is superior to both ultrasonography and radiography to confirm the diagnosis of FG and support in surgical management. *McGillicuddy et al.* in a review of CT findings on adult patients undergoing imaging for the evaluation of a soft-tissue infection reported a sensitivity of 86.3% and a specificity of 91.5%, with a negative predictive value of 85.5% (5). However, imaging evaluation in patients with FG may be limited by the frequent presence of concurrent acute renal failure (thus precluding the use of intravenous contrast material) or patient hemodynamic instability making transport to the *Radiology Department* unsafe. US study can be readily performed in bedside settings, which is of particular benefit to patients who are hemodynamically unstable but whose physical examination findings are equivocal (6). The characteristic US features of necrotizing infections comprise subcutaneous multiple hyperechoic foci that show reverberation artefacts, causing "dirty" shadowing that represents gas (Figure 3) (1, 6).

In conclusion we believe that US study constitutes an excellent minimally invasive alternative in such situations, reduces the extension of surgical field allowing a quick recovery and the risk of under treatment, can value alternate pathologies, such as epididymitis and torsion, does not expose patients to radiation, and does not require contrast-enhanced. Based on our experience, a preoperative US study may identify easy and precisely distant foci of infection spreading avoiding wide surgical field and provide earlier control of disease.

## REFERENCES

1. Di Serafino M, Gullotto C, Gregorini C, et al. A clinical case of Fournier's gangrene: imaging ultrasound. *J Ultrasound*. 2014; 17:303-6.
2. Luján Marco S, Budía A, Di Capua C, et al. Evaluation of a severity score to predict the prognosis of Fournier's gangrene. *BJU Int*. 2010; 106:373-6.
3. Levenson RB, Singh AK, Novelline RA. Fournier gangrene: role of imaging. *Radiographics*. 2008; 28:519-28.
4. Fournier AJ. Gangrene foudroyante de la verge. *Semaine Med*. 1883; 3:344-46.
5. McGillicuddy EA, Lischuk AW, Schuster KM, et al. Development of a computed tomography-based scoring system for necrotizing soft-tissue infections. *J Trauma*, 2011; 70:894-9.
6. Rajan DK, Scharer KA. Radiology of Fournier's gangrene. *AJR*. 1998; 170:163-8.

## Correspondence

Lucio Dell'Atti, MD, PhD (Corresponding Author)  
dellatti@hotmail.com

Daniele Cantoro, MD - Daniele.Cantoro@ospedaliriuniti.marche.it

Guevar Maselli, MD - guevarmaselli@katamail.com

Andrea Benedetto Galosi, MD - galosiab@yahoo.it

Department of Urology - Marche Polytechnic University

University Hospital "Ospedali Riuniti"

71 Conca Street - 60126 Torrette, Ancona, Italy