

Ultrasonographic study of subcutaneous penile granuloma secondary to silicone injection

Lucio Dell'Atti

Department of Urology, University Hospital "St. Anna", Ferrara, Italy.

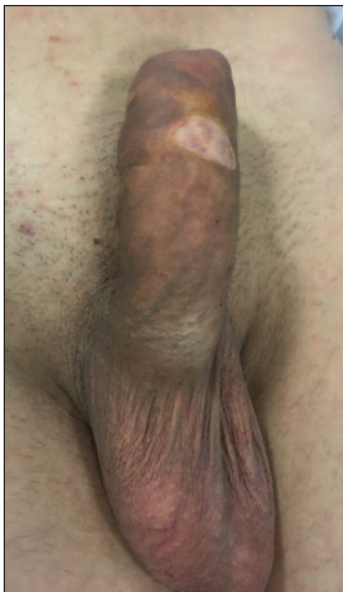

Figure 2.
A tender and highly swollen penis with ulcerated tissue, especially on the ventral surface, and a considerable phimosis was developed 2 months following penile augmentation by silicone injection.

Figure 3.
The surgical access was through a circumferential sub-coronal dorsal incision and penile skin was dissected with the silicon mass.

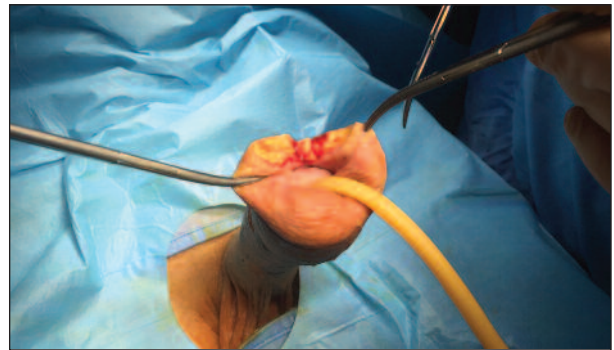


Figure 5.
Penile skin was re-draped over the shaft and the incision was closed in one layer.

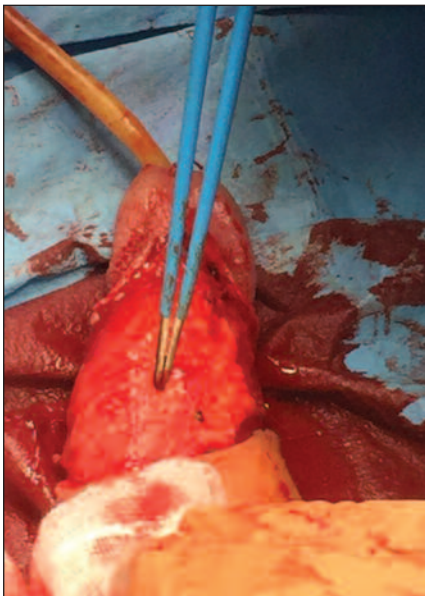


Figure 4.
Following excision of the mass, the corpora cavernosa were inspected for integrity.

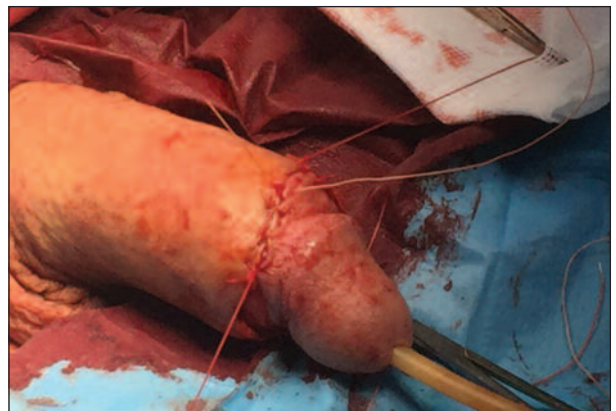


Figure 6.
Cut section of the excised mass

