

Renal cell carcinoma in patient with crossed fused renal ectopia

Ozgur Cakmak, Cemal Selcuk Isoglu, Ercument Aziz Peker, Huseyin Tarhan, Ulku Kucuk, Orcun Celik, Ferruh Zorlu, Yusuf Ozlem Ilbey

Clinic of Urology, Tepecik Research and Education Hospital, Izmir, Turkey.

Summary Primary renal cell carcinomas have rarely been reported in patients with crossed fused renal ectopia. We presented a patient with right to left crossed fused kidney harbouring renal tumor. The most frequent tumor encountered in crossed fused renal ectopia is renal cell carcinoma. In this case, partial nephrectomy was performed which pave way to preservation of the uninvolved both renal units. Due to unpredictable anatomy, careful preoperative planning and meticulous delineation of renal vasculature is essential for preservation of the uninvolved renal units.

KEY WORDS: Crossed fused renal ectopia; Renal cell carcinoma.

Submitted 23 May; Accepted 30 September

INTRODUCTION

Congenital anomalies of upper urinary tract include anomalies in number, location, collecting system and renal vasculature. Crossed fused renal ectopia (CRE) is an uncommon congenital anomaly in which both the kidneys lie on one side and are fused. This is the second most common congenital anomaly following horseshoe kidney (1). Primary renal cell carcinomas have rarely been reported in patients with crossed fused renal ectopia (2-4). Due to atypical arterial supply and venous drainage, surgery in these patients may become challenging. In this report we presented a patient with right to left crossed fused kidney harbouring renal tumor.

CASE REPORT

A 42-year-old female patient presented complaints with left flank pain and dysuria. No family history of congenital anomalies and no systemic disease was present. Laboratory tests were in normal ranges. Right kidney was not visualized by ultrasonography and a 7 x 6 cm isoechoic mass was detected in the conjunction of both kidneys in left quadrant. Contrast enhanced computerized tomography (CT) revealed right to left cross fused renal ectopia with 70 x 65 mm of solid mass arising from orthotopic left renal moiety (Figure 1). No evidence of distant metastases was observed. Magnetic resonance angiography was performed to delineate the renal vasculature of the kid-

Figure 1.

CT scan demonstrating tumor arising from orthotopic left renal moiety and relation to crossed fused ectopic 'right' kidney.

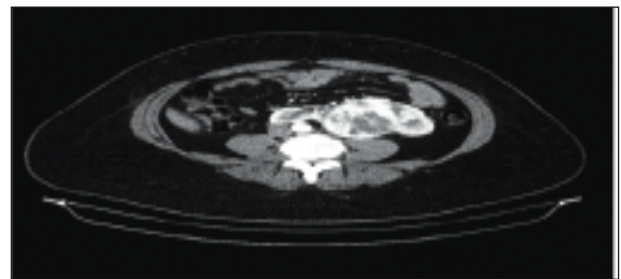
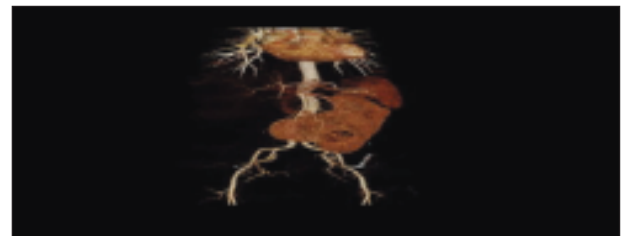


Figure 2.

CT angiography image delineating renal arteries of both renal moieties.



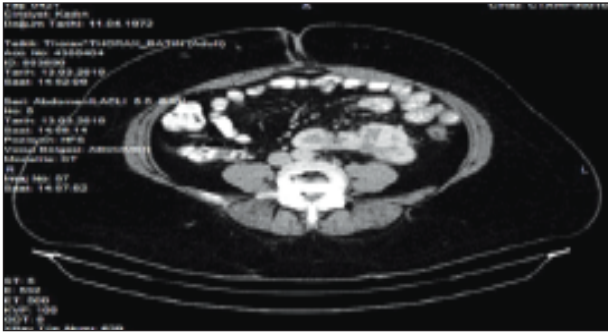
neys and tumor (Figure 2). After catheterization of both ureters, partial nephrectomy was performed without any perioperative complication. Pathologic examination revealed clear cell renal cell carcinoma, Fuhrman grade 1 with negative surgical margins. Patient was discharged at postoperative fifth day after uneventful postoperative period. No pathologic finding was observed during 7 months follow-up and her renal function has remained stable on routine surveillance.

DISCUSSION

Crossed renal ectopia is an uncommon congenital anomaly and in most cases usually presents with fusion of both kidneys. The autopsy incidence has been reported as 1 in 2000 (1). There is a slight male predominance (3:2), and left-to-right crossover occurs more frequently (1). The

No conflict of interest declared.

Figure 3.
Sample CT axial slice of patient depicting both kidneys in postoperative period.



most common anomaly involves fusion between the lower pole of the orthotopic kidney and the upper pole of the ectopic kidney with the lower ureter crossing the midline to insert into a normal location within the bladder trigone. In our case it was right to left crossover with two ureters ending in their normal positions.

The association of malignant tumors with such anomalies is an extremely rare event.

Primary renal cell carcinomas have rarely been reported in patients with crossed fused renal ectopia (2-5). Management typically involves complete nephrectomy of both renal moieties or excision of the tumor (4-6). Due to the unpredictable anatomy and vascular anomalies which are observed in 70% of cases, careful preoperative planning using CT, magnetic resonance imaging (MRI) or CT/MRI angiography is advised (5).

Preoperative ureteral stenting may be helpful to avoid inadvertent ureteral injury during surgery. There are several surgical approaches which were described for renal fusion abnormalities. Among these techniques anteriorly-based approaches such as subcostal or thoracoabdominal incisions provides the optimal exposure of the anomalous anatomy which enables nephron sparing surgery possible (5).

In our case, left subcostal approach was performed to

excise the tumor which paved way to preservation of the uninvolved both renal units. Postoperative CT imaging of both kidneys was shown in Figure 3.

In the reviewed literature, RCC is the type of tumor most frequently associated with fusion anomalies.

Its incidence among fusion anomalies is similar to the general population and the prognosis of the disease depends on the same prognostic factors as in case of normal kidneys (6). Compatibly the literature, pathologic examination of our case revealed RCC.

CONCLUSIONS

Primary malignancy in kidneys with fusion anomalies are very rare entity.

The most frequent tumor encountered in crossed fused renal ectopia is renal cell carcinoma. Due to unpredictable anatomy, careful preoperative planning and meticulous delineation of renal vasculature is essential for preservation of the uninvolved renal units.

REFERENCES

1. Bauer SB. Anomalies of the upper urinary tract. In: Wein AJ, Kavoussi LR, Novick AC, Partin AW, Peterseds CA, eds. *Campbell's urology*, 9th ed. Philadelphia: Saunders-Elsevier; 2007; p. 3269-304.
2. Bolton DM, Bowsher WG, Costello AJ. Renal cell carcinoma in both moieties of crossed fused ectopia. *Aust N Z J Surg*. 1993; 63: 662-3.
3. Sugita S, Kawashima H, Nakatani T, et al. Renal cell carcinoma in an L-shaped kidney. *Int J Urol*. 2000; 7: 236-8.
4. Tsunoe H, Yasumasu T, Tanaka M, et al. Resection of an L-shaped kidney with renal cell carcinoma using a microwave tissue coagulator. *Int J Urol*. 2001; 8:459-62.
5. Carley M, Davis Manoj V, Rao Robert C, et al. Renal cell carcinoma in two patients with crossed fused ectopic kidneys. *Urol Int*. 2008; 81:370-2.
6. Stimac G, Dimanovski J, Ruzic B, et al. Tumors in kidney fusion anomalies – report of five cases and review of literature. *Scand J Urol Nephrol*. 2004; 38:485-9.

Correspondence

Ozgur Cakmak, MD

Cemal Selcuk Isoglu, MD

Ercument Aziz Peker, MD

Huseyin Tarhan, MD

Ulku Kucuk, MD

Orcun Celik, MD

orcuncelik82@hotmail.com

Ferruh Zorlu, MD

fyzorlu@yahoo.com

Yusuf Ozlem Ilbey, MD

Tepecik Research and Education Hospital, Clinic of Urology,
Izmir, Turkey