

## CASE REPORT

# An unusual “linitis plastica” like breast cancer bladder metastasis

Riccardo Farci<sup>1</sup>, Simona Tolu<sup>1</sup>, Matilde Trombetta<sup>2</sup>, Alessandro Murgia<sup>1</sup>, Andrea Solinas<sup>1</sup>

<sup>1</sup> Department of Surgery, Unit of Urology, ARES Sardegna, ASL Sulcis, Sirai Hospital, Carbonia, Italy;

<sup>2</sup> Pathology Department, ARES Sardegna - ASL Cagliari, SS. Trinità Hospital, Cagliari, Italy.

## Summary

*Breast cancer (BrC) is the most frequently diagnosed malignancy in woman and most*

*BrC related deaths are due to metastasis. BrC frequently metastasizes to the lymph nodes, liver, lung, bone and brain while the urinary bladder is considered as an unusual site for breast metastasis. We report a case of bladder metastasis identified in a patient with past BrC history, presenting with hematuria, low urinary tract symptoms, and hydronephrosis.*

**KEY WORDS:** Bladder metastasis; Breast cancer; Breast cancer metastasis.

Submitted 16 March 2024; Accepted 28 March 2024

## INTRODUCTION

BrC is the most frequently diagnosed malignancy in women with an estimated 1.6 million new cancer cases diagnosed worldwide (1). Incidence of BrC show variability across different countries. It is highest in Australia, Europe and North America, reflecting discrepancies in early diagnosis and in the entity of risk factors. Although we actually have effective screening programs and therapies, it remains the leading cause of death because of metastatic disease. BrC in fact usually metastasizes to lymph nodes, bone, lung and liver, while bladder metastasis is very uncommon, accounting for about 2.4% of all bladder metastasis (2). We present the case of 75-year-old woman with severe hematuria and a history of breast cancer.

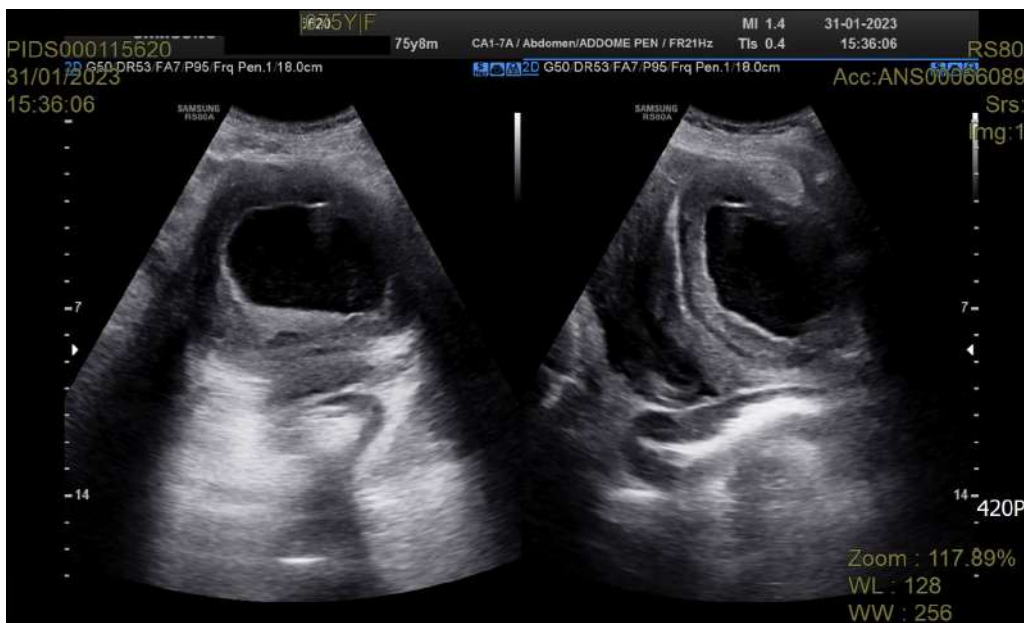
## CASE REPORT

In January 2023 we hospitalized a 75-year-old woman suffering from dementia from the Emergency Department due to the appearance of severe hematuria and dysuria. Her past medical history showed hypothyroidism, hypercholesterolemia, bilateral hearing loss. In 2018 she underwent a left nipple sparing mastectomy and contextual axillary lymphadenectomy. Histopathological examination showed an infiltrating lobular carcinoma pT2G2N2 (6/15 positive lymph nodes, RE=90% RPg=34% Ki67=18% Her2: +-). The patient at the time was not eligible for adjuvant chemotherapy due to the time since diagnosis, so she received letrozole and locoregional radiotherapy from 03/27/2019 to 05/03/2019. The patient then adequately adhered to the follow-up protocol. At the emergency-

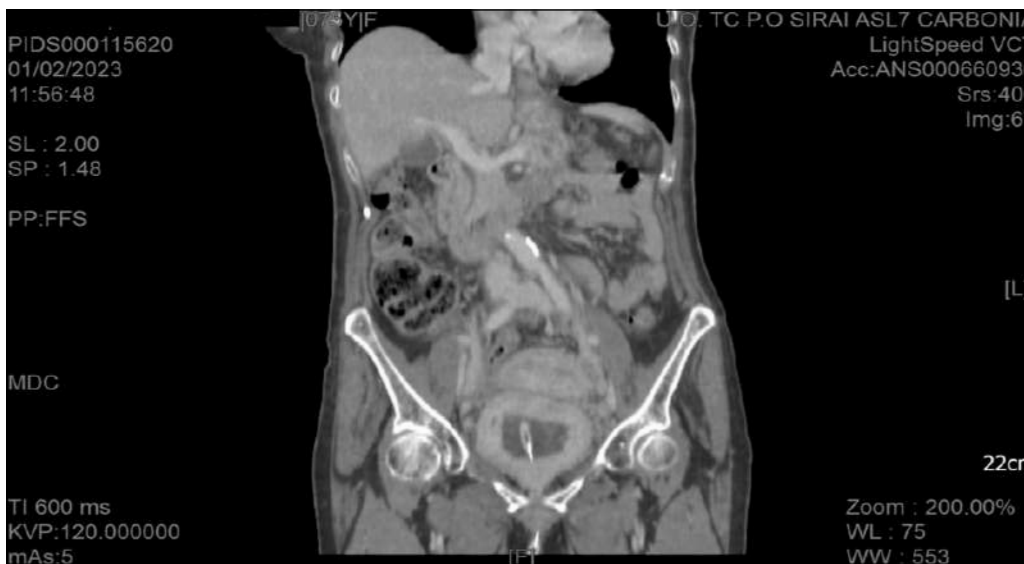urgency department she underwent an abdominal ultrasound which showed a markedly thickened urinary bladder (max 10.4 mm), with finely corpuscular contents as of blood nature and bilateral hydronephrosis (Figure 1). Blood tests demonstrated a slight increase in serum creatinine (1.42 mg/dL) and mild anemia (HBG 11.3 g/dL). Contrast-enhanced CT scan showed diffuse and marked thickening of the entire urinary bladder (10.4 mm max) with contextual inhomogeneity of the perivesical fat, particularly affecting the Retzius space, bilateral hydronephrosis and numerous osteolytic skeletal lesions affecting the vertebral metameres from D10 to L2, proximal diaphysis of the left femur and left iliac wing (Figure 2). We decided to proceed with a transurethral resection of the bladder. Cystoscopy showed a bladder with little distensibility and erythematous mucosa, in the absence of clear vegetating neoplasms. The ureteral meatuses could not be recognized. We then proceeded to perform a TURB for hemostatic and biopsy purposes. TURB specimen showed proliferation of cells CK19+, CK34BE12+, PgR+, ER- (Figure 3) compatible with poorly differentiated epithelial neoplasia and suspected of breast cancer primitiveness. The poor performance status made the patient ineligible for any oncological therapy.

## DISCUSSION

BrC is the most frequent cancer in women worldwide. The most common sites of metastasis are bone, lung, liver and brain. The urinary bladder is rarely involved, being only about 4.5% of all bladder metastases derived from solid tumors (2) and typically the majority of cases are secondary to direct invasion by pelvic neoplasms (3). Bladder metastases deriving from BrC accounts for about 2.4% of all bladder metastases (2), they usually are expression of systemic disease (9) and rarely occur as solitary metastases (4). A review of the literature showed about 65 cases of BrC bladder cancer metastases published (5). The majority of BrC bladder metastases derives from an *invasive lobular carcinoma* (ILC) rather than an *invasive ductal carcinoma* (IDC): ILC has in fact a particular tropism for serosal surfaces such as gastrointestinal and gynecological tracts, and from these two last sites metastases can then spread to the bladder (6). They can present as exophytic mass, thickening of the bladder wall or nonspecific mucosal phlogistic areas.

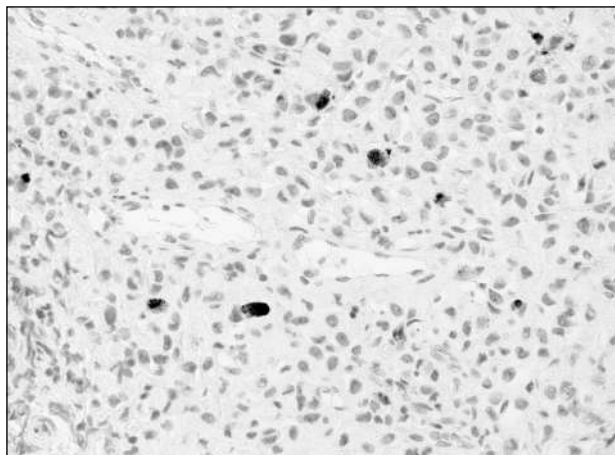


**Figure 1.** Ultrasound of the bladder showing diffuse bladder wall thickening.



**Figure 2.** CT scan demonstrating thickening of urinary wall.

**Figure 3.** Histopathology image of specimen: demonstration of PR positive BrC cells.



The most common clinical presentation is characterized by asymptomatic gross hematuria, lower urinary tract symptoms in case of detrusor involvement, flank pain because of hydronephrosis with renal failure and sepsis, but early stages can be asymptomatic (7).

The diagnostic workshop of the patient must include ultrasounds, CT scans and cystoscopy. Endoscopy can be used to stop hematuria by *transurethral resection of bladder* (TURB) (7), possibly to visualize ureteral meatus in case of need for ureteral stent placement, but most of all to obtain biopsy samples. Despite of all, the past clinical history of the patient remains fundamental in formulating the suspicion of bladder metastases.

Prognosis is similar to that of any metastatic BrC, with an average survival of 18-30 months (8), while the gold standard treatment is a combination of endocrine therapy and chemotherapy. Radiotherapy also can have a role in controlling hematuria.

## CONCLUSIONS

BrC urinary bladder metastases are a rare disease and the differential diagnosis compared to other pathologies with similar symptoms can be complex, and the Physician need to take into consideration this possibility in all women with past history of BrC presenting with urinary symptoms (9).

## REFERENCES

1. Torre LA, Bray F, Siegel RL, et al. *Global Cancer Statistics, 2012*. *CCA Cancer J Clin* 2015; 65:87-108.
2. Bates AW, Baithun SL. *The significance of secondary neoplasms of the urinary and male genital tract*. *Virchows Arch*. 2002; 440:640-647.
3. Cormio L, Sanguedolce F, Di Fino G, et al. *Asymptomatic bladder metastasis from breast cancer*. *Case Rep Urol*. 2014; 2014:672591.
4. Zagha RM, Hamawy KJ. *Solitary breast cancer metastasis to the bladder: an unusual occurrence*. *Urol Oncol*. 2007; 25:236-239.
5. Karjol U, Jonnada P, Cherukuru S, et al. *Bladder metastasis from breast cancer: a systematic review*. *Cureus* 2020; 12:e7408.
6. Ferlicot S, Vincent-Salomon A, Médioni J, et al. *Wide metastatic spreading in infiltrating lobular carcinoma of the breast*. *Eur J Cancer*. 2004; 40:336-341.
7. Ramsey J, Beckman EN, Winters JC. *Breast cancer metastatic to the urinary bladder*. *Ochsner Journal information*. 2008; 8:208-212.
8. Gennari A, Conte P, Rosso R, et al. *Survival of metastatic breast carcinoma patients over a 20-year period: a retrospective analysis based on individual patient data from six consecutive studies*. *Cancer*. 2005; 104:1742-1750.
9. De Rose AF, Balzarini F, Mantica G, et al. *Late urinary bladder metastasis from breast cancer*. *Arch Ital Urol Androl*. 2019; 91:60-62.

## Correspondence

Riccardo Farci, MD (Corresponding Author)  
riccardo.farci@aslsulcis.it - Urology Department

Andrea Solinas, MD - Urology Department  
andreasolinas@aslsulcis.it

Simona Tolu, MD  
simona.tolu@aslsulcis.it - Oncology Department

Alessandro Murgia, MD  
alessandro.murgia@aslsulcis.it - Radiology Department

ARES Sardegna - ASL Sulcis, Sirai Hospital  
Via Ospedale, 09013 Carbonia, Italy

Matilde Trombetta, MD  
matilde.trombetta@aslcagliari.it

Pathology Department, ARES Sardegna - ASL Cagliari, SS. Trinità Hospital  
Via Is Mirrionis 92, 09121 Cagliari, Italy

**Conflict of interest:** The authors declare no potential conflict of interest.