

# New concept in urologic surgery: The total extended genital sparing radical cystectomy in women

Antonio Cisternino, Lorenzo Capone, Antonio Rosati, Costanzo Latiano, Nicola Sebastio, Antonio Colella, Giuseppe Creti

Department of Urology, Fondazione IRCCS Casa Sollievo della Sofferenza, San Giovanni Rotondo, Italy.

## Summary

**Introduction and objectives:** The aim of the study was to evaluate genital sparing radical cystectomy surgery in female patients from the point of view of both oncologic and functional outcomes (with emphasis on urinary and sexual outcomes) in a single high-volume center for the treatment of muscular invasive bladder cancer.

**Materials and methods:** Between January 2014 and January 2018, 14 female patients underwent radical cystectomy with preservation of genital organs (the entire vagina, uterus, fallopian tubes, ovaries) and orthotopic urinary neobladder (Padua neobladder). Inclusion criteria were recurrent T1G3 tumors; refractory tumors after BCG therapy without associated carcinoma in situ (CIS); T2 or T3a tumors entirely resected at endoscopic transurethral resection of the bladder and not involving urethra/bladder trigone. Exclusion criteria were: T3b or higher bladder cancer, associated CIS and involvement of urethra or bladder trigone. Oncological and histopathological outcomes (Overall Survival - OS, Recurrence Free Survival - RFS), urinary outcomes (day and night incontinence, intermittent catheterization use, Sandvik Score) and sexual outcomes (Female Sexual Function Index 19 FSFI-19) were considered. The average follow-up time was 56 months.

**Results:** Considering oncological outcomes, histologic examination reported urothelial carcinoma in 13/14 patients; 8/13 patients (61.5%) had high grade T1 stage, 3/13 patients (23%) had high grade T2 stage and finally 2/13 patients (15.5%) had high-grade T3 stage. One patient presented with embryonal rhabdomyosarcoma completely excised after surgery (PT2aN0M0). No patient developed local or metastatic recurrence (RFS 100%); OS was 100%. Considering urinary continence outcomes, 12/14 patients retained daytime and nighttime continence (85.5%); 2/14 (14.5%) complained of low stress urinary incontinence daily and nighttime urinary leakage.

The Sandvik Score showed complete continence in 7/14 patients (50%); mild degree incontinence in 6/14 patients without use of incontinence devices (43%); moderate degree of incontinence in one patient (7%). The FSFI administered at 1 year from the surgery showed sexual desire in all patients (100%); subjective arousal, achievement of orgasm and sexual satisfaction in 12/14 patients (85.5%); sufficient lubrication in 11/14 patients (78.5%). Only one patient (7%) complained about dyspareunia during sexual intercourse.

**Conclusions:** Our study aims to demonstrate that genital-sparing radical cystectomy is a safe surgery in terms of oncologic outcomes and, most importantly, that it is beneficial in terms of urinary and sexual function. Indeed, patients' quality of life together with their psychological and emotional health should be put on the same level as oncological safety. However, it is a

treatment reserved for selected patients who are strongly motivated to preserve fertility and sexual function and thoroughly informed about the benefits and complications of such a procedure.

**KEY WORDS:** Muscle-invasive bladder cancer; High risk non-muscle invasive bladder cancer; Total extended genital sparing; Oncologic outcomes; Sexual life; Post-operative continence; Quality of life.

Submitted 4 December 2022; Accepted 20 December 2022

## INTRODUCTION

Bladder cancer is the 13<sup>th</sup> most common cancer worldwide when both sexes are considered. If only the male population is taken into account, the incidence rises to sixth place with a mortality rate of 3.3 per 100.000 population (1). However, cancer incidence is about four times lower in women than in men (2). Nevertheless, female gender is an independent risk factor for the disease, which is associated with a higher stage at diagnosis (3). Radical cystectomy with urinary diversion and possibly neoadjuvant chemotherapy is the treatment of choice for patients with muscle-invasive bladder cancer or high-risk non-muscle-invasive bladder cancer. In men, this involves removal of the bladder, prostate, seminal vesicles and loco-regional lymph nodes. In women, it is a true anterior pelvic exenteration with removal of the bladder, urethra, uterus, ovaries, adnexa, anterior wall of the vagina and loco-regional lymph nodes (4). This surgery has a detrimental effect on both the quality of life and the psychology of the patient, and many high-volume centers have considered it being less disruptive for female patients, especially in the pre-menopausal phase (5). Initially, cystectomy with urethral sparing and urinary diversion was performed, but nowadays selected patients undergo cystectomy with genital sparing, which can preserve fertility and a sexually active life (6). In this article we describe our genital organ preservation technique and examine the oncological and functional results at 56 months of follow-up.

## MATERIALS AND METHODS

Between January 2014 and January 2018, 14 female patients were admitted to the Urology Department of the IRCCS Casa Sollievo della Sofferenza Foundation in San Giovanni Rotondo. All patients underwent radical cystecto-

my and bilateral pelvic lymphadenectomy with preservation of genitalia (vagina, uterus, fallopian tubes and ovaries) and orthotopic urinary diversion. Prior to surgery, they were carefully counseled about the procedure, possible long-term and short-term complications, and finally signed an informed consent.

In accordance with the most recent guidelines, we placed as inclusion criteria for surgery: recurrent high-grade T1 tumors, tumors relapsed after BCG therapy without the presence of concomitant *Carcinoma in situ* (CIS), T2 and T3a tumors completely excised at endoscopic *transurethral resection of the bladder* (TURB) and not involving the urethra or bladder trigone. All patients were sexually active and were younger than 65 years of age. Before surgery, each patient was evaluated by accurate clinical history (with special attention to urinary and sexual function), physical examination, complete abdominal ultrasound, cystoscopy, and bladder biopsy in order to exclude CIS or concomitant dysplasia; they also had gynecological examination to exclude tumors or papilloma of the cervix, uterus, or ovaries. Finally, all patients were staged by abdominal and pelvic CT with contrast and sequential bone scintigraphy to exclude extension to the peri-vesical fat (T3b), lymph nodes, and/or adjacent organs (T4). Exclusion criteria were bladder cancer T3b or higher, concomitant CIS, and urethral and/or trigone involvement. All patients had bowel preparation and antibiotic prophylaxis the day before surgery.

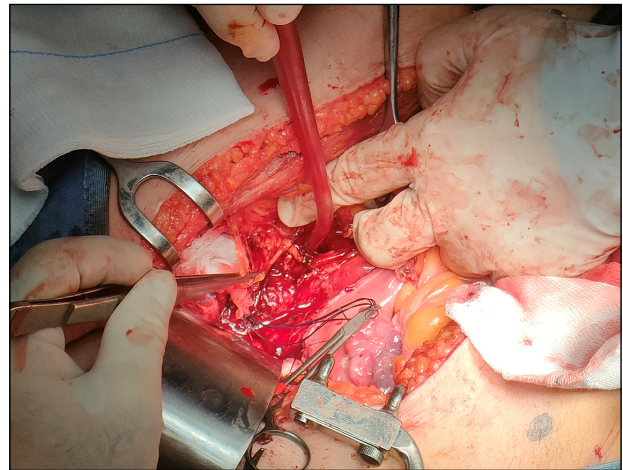
### **Surgical open technique**

Patients were placed in the Trendelenburg supine position with pelvic hyperextension. An incision was made on the midline from the pubis to the umbilicus, after dividing the muscular-aponeurotic planes, the peritoneal sac was opened. Lysis of any bowel-omental adhesions was performed, and the bowel was cranially dislocated to expose the pelvis. The bladder was then mobilized to the lateral walls of the pelvis. The residual urachus was circumscribed – paying attention not to injure the lower epigastric vessels –, to be removed with the entire bladder. A careful and systematic examination was carried out to determine the extent of the disease and the possible presence of metastases or massive retroperitoneal lymphadenopathy. At this point the bowel was mobilized from the ascending colon, which was moved medially to gain access to the right ureter. The mesentery was reversed until the retroperitoneal part of the duodenum was exposed. The left colon and sigmoid were then mobilized to the inferior pole of the left kidney to give access to the left ureter. The ureters were then isolated at their entrance to the bladder, were they were ligated and dissected. To exclude neoplastic involvement, the distal margin was sent for extemporaneous histopathology. The umbilical, uterine, superior, and inferior bladder arteries were carefully dissected bilaterally. The bladder was mobilized and the junction between the cervix and the anterior wall of the vagina was identified along the anterior wall of the uterus. The vaginal wall was then dissected at the level of the anteroventral plane of the vagina, at 2 o'clock and 10 o'clock, as close as possible to the bladder wall, in order to preserve the paravaginal tissues con-

taining the autonomic nerves that reach the proximal sphincter. The superior and inferior bladder arteries were dissected at their origin, at the level of the hypogastric arteries, while the uterine arteries and vaginal branches of the paravaginal tissues were spared. Once the retroperitoneal space was created and opened, the endopelvic fascia was incised very close to the bladder neck to reduce the risk of inadvertent injury to the paraurethral neurovascular structures, which are crucial for sexual function and continence (Figures 1, 2). The urethra was carefully prepared, exposed and divided, and a specimen was sent for extemporaneous histopathological examination (Figure 3). At this time, careful dissection of the retroperitoneal lymph nodes was performed. The margins of the resection were cranially defined by the common iliac artery,

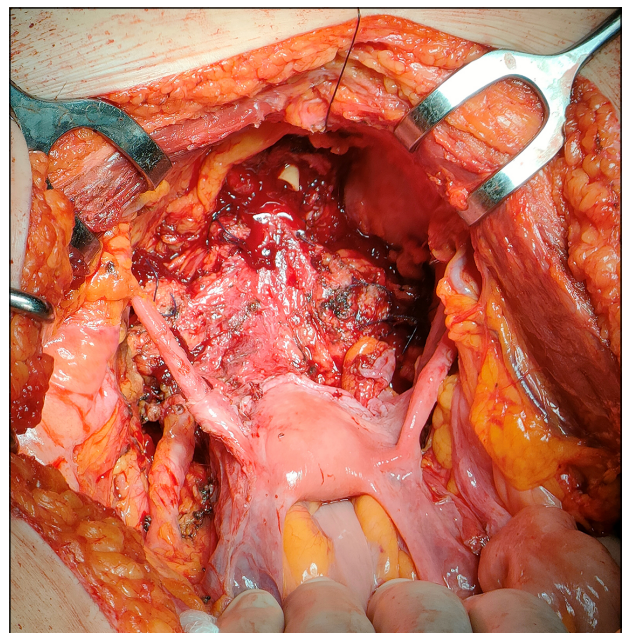
**Figure 1.**

*Development of the plane between uterus and bladder.*

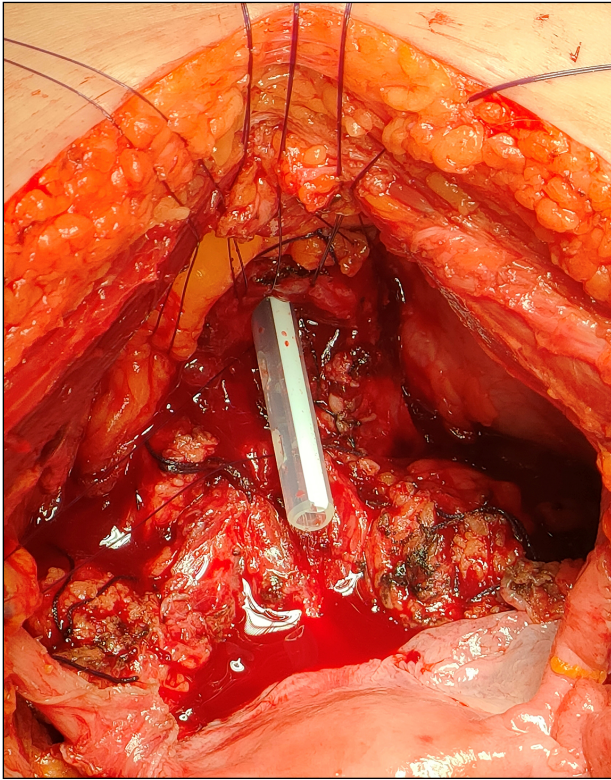


**Figure 2.**

*Genital sparing cystectomy with sparing of the uterus, ovaries, tubes and vagina.*



**Figure 3.**  
Preparation of the urethra.



laterally by the genito-femoral nerves, inferiorly by the Cooper's ligament, caudally by the obturator canal, medially and laterally by the hypogastric vessels.

#### Mini-invasive technique

Out of the 14 patients who underwent radical cystectomy with genital sparing, 3 underwent removal of the bladder using the robot-assisted laparoscopic technique with the *Da Vinci robot* (Ab Medica). During the procedure, patients were placed in the supine position with abducted lower limbs. A catheter was placed. This was followed by a supraumbilical skin incision to access to the abdomen using the Hasson open technique, opening of the peritoneum under direct vision, positioning of the first optical trocar and induction of pneumoperitoneum at 12 mmHg. Patients were placed in Trendelenburg position ( $> 25^\circ$ ), and the peritoneal cavity and viscera were inspected to exclude adhesions or metastatic pathology. Two additional 8 mm robotic surgical ports were placed approximately 8 cm from the optical trocar, 2 cm lateral to the rectus abdominis muscle, at the level of the inferior border of the umbilicus. Two further laparoscopic ports were introduced, one 12 mm, 5 cm above the anterior superior iliac spine, on the right mid-axillary line for the surgical tractions; another 5 mm, approximately 2.5 cm above the right robotic ports for the surgical aspirator. Finally, the robot was docked with monopolar curved scissors on the right and bipolar ProGrasp forceps on the left. The steps for radical cystectomy were the same as for open surgery. At the end of the robotic procedure, a suprapubic Pfannenstiel incision was made, the surgical

piece previously placed in the endobag was removed and finally the orthotopic urinary diversion was packed.

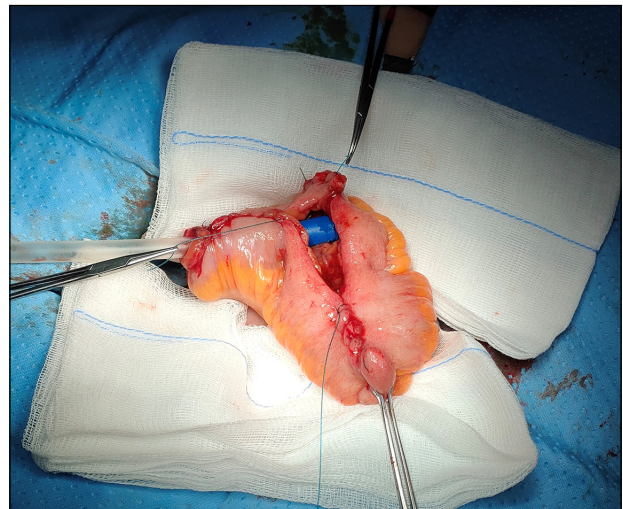
#### Orthotopic neobladder

At a distance of 15-20 cm from the ileocecal valve, a 40 cm ileal segment is isolated. Intestinal continuity is restored with a latero-lateral anastomosis. Mechanical sutures are used. The distal loop (approximately 20 cm in length) is lowered to form a 'U' to reach the membranous urethra. The ileal segment is then opened along the antimesenteric border. A 3/0 V-Loc suture is used to tunnel the lower part of the ileal loop posteriorly and anteriorly. The proximal loop is folded medially into an inverted U-shape and the opposite inner edges are then sutured from side to side to form an upper ileal cup. This is then inverted at the edges of the lower ileal pouch to create an oval reservoir. The urethro-intestinal anastomosis is packed with 6 detached stitches of resorbable 3/0 glyconate monofilament suture on a 20-ch 3-way neobladder catheter. The uretero-neovesical anastomosis is then exteriorized at the level of the left iliac fossa using Bracci ureteral catheters as a guide. A hydraulic leak test of the neobladder is performed and a 24 c tube drain is placed in the Retzius excavation at the level of the right iliac fossa. Finally, the abdominal wall is closed in layers (Figure 4).

#### Post-operative assessment

Patients were evaluated according to age, *Body Mass Index* (BMI), *American Society of Anesthesiology* (ASA) score, pre-operatively measured hemoglobin and creatinine. Surgical outcomes were operative time, discharge hemoglobin and creatinine, days in hospital and perioperative complications in accordance with the Clavien-Dindo classification system (7). Patients were functionally and oncologically followed by outpatient visits quarterly in the first year and biannually thereafter with a program including blood tests, abdominal ultrasound, urine cytology, abdominal and pelvic CT, urethrocytostomy and chest X-ray. The study evaluated the following oncological outcomes: *Recurrence Free Survival* (RFS local or metastatic)

**Figure 4.**  
Final configuration of the neobladder.



and *Overall Survival* (OS) both measured at more than 56 months of follow-up and finally anatomopathological outcomes. In terms of functional outcomes, sexual function was measured using a standardized questionnaire: The *Female Sexual Function Index* (FSFI-19) (8). This is a quick and effective questionnaire that structures female sexual function into 6 different aspects: desire, subjective arousal, lubrication, orgasm, satisfaction, and pain, with a score ranging from a minimum of 2 to a maximum of 36. We administered it both 3 and 12 months after surgery. Urinary function was evaluated by the patient's level of continence (day and night) and the use of urinary incontinence devices; the severity of urinary leakage was calculated using the Sandvik score (9).

Finally, urinary retention requiring intermittent urethral catheterization was assessed.

## RESULTS

The mean age of the 14 patients who underwent genital sparing radical cystectomy was 57.6 years (range 30-65). The preoperative clinicopathological characteristics of the patients are shown in Table 1. Regarding surgical outcomes (Table 2), the mean operative time for the entire procedure, including cystectomy, bilateral pelvic lymphadenectomy and neobladder reconstruction, was 260 minutes (range 220-396 minutes) for the open procedure

**Table 1.**  
*Patient characteristics.*

Patient characteristics	Mean (range)
Age (years)	57.6 (30-65)
Body Mass Index	26.1 (20-30.5)
Preoperative Creatinine (mg/dL)	0.86 (0.72-1.1)
Preoperative Hemoglobine (g/dL)	12.7 (11.2-14.3)
	<b>No. of patients (%)</b>
Status	
Married	13 (93)
Unmarried	1 (7)
Menopause	
Premenopausal	6 (43)
Postmenopausal	8 (57)
ASA Score	
I	8 (57)
II	6 (43)
Previous abdominal surgery	
Cesarean section	1 (7)
Appendectomy open	1 (7)
Location of the tumor	
Posterior wall	6 (43)
Anterior wall	1 (7)
Lateral wall	6 (43)
Dome of the bladder	1 (7)
Pathological type	
Urothelial carcinoma	13 (93)
Other (Embryonal rhabdomyosarcoma)	1 (7)
Grading of the tumor	
Low grade	0 (0)
High grade	14 (100)
Staging TNM	
T1 NO MO	8 (57)
T2 NO MO	4 (29)
T3 NO MO	2 (14)

and 318 minutes (range 258-432 minutes) for the robotic one. The mean blood loss during surgery was 400 ml (230-710 ml). Patients' mean hospital stay was 18 days (15-24 days), and discharge hemoglobin and serum creatinine were 9.3 g/dL (8.9-14.8 g/dL) and 1.2 mg/dL (0.8-1.6 mg/dL), respectively. Perioperative complications such as loss of ileo-ileal anastomotic seal, bleeding, or loss of neobladder seal were not observed in any of the patients.

None of the patients had complications requiring surgery (grade  $\geq 3$  according to the Clavien-Dindo classification of postoperative complications); only one patient had postoperative acute pancreatitis, which was successfully treated with medical therapy.

Final histopathological examination revealed urothelial carcinoma in 13 patients, of which 8/13 (61.5%) had low grade T1 stage, 3/13 (23%) had high grade T2 stage and, finally, 2 (15.5%) had high grade T3 stage. Botryoid variant embryonal rhabdomyosarcoma localized to the bladder and completely excised after surgery (PT2aN0M0) was found in one patient at final histopathological exam-

**Table 2.**  
*Surgical and oncologic outcomes.*

Surgical and oncologic outcomes	Mean (range)
Operative time (min)	
Open	260 (220-396)
Robot-assisted	318 (258-432)
Mean Blood Loss (ml)	400 (230-710)
Hospital stay (days)	18 (15-24)
Postoperative creatinine (mg/dL)	1.2 (0.8-1.6)
Postoperative hemoglobine (g/dL)	9.3 (8.9-14.8)
	<b>No. of patients (%)</b>
Complications	
Clavien low grade (0-2)	14 (100)
Clavien high grade (3-5)	0 (0)
Cystectomy	
Robotic-assisted cystectomy	3 (21)
Open cystectomy	11 (79)
Postoperative pathologic stage	
Ta, Tis, T1	8 (57.5)
T2aN0M0	1 (7)
T2bN0M0	3 (21.5)
T3aN0M0	1 (7)
T3bN0M0	1 (7)
T4	0 (0)
Pathologic nodal stage	
NO	14 (100)
N+	0 (0)
Tumor grading	
Low grade	0 (0)
High grade	14 (100)
Positive surgical margins	0 (0)
Follow-up 12 months	
Recurrence-free survival	14 (100)
Overall survival	14 (100)
Follow-up 24 months	
Recurrence-free survival	14 (100)
Overall survival	14 (100)
Follow-up 36 months	
Recurrence-free survival	14 (100)
Overall survival	14 (100)

**Table 3.**  
Functional outcomes.

Functional outcomes	No of Patients (%)
Continence	
Day-time	14 (100)
Night-time	12 (85.5)
Sandvik score	
0 (continent)	7 (50)
1-2 (mild incontinence)	6 (43)
3-6 (moderate incontinence)	1 (7)
8-9 (severe incontinence)	0 (0)
12 (very severe incontinence)	0 (0)
Neobladder complications	
Urethral stricture	1 (7)
Female Sexual Function Index (FSFI) at 12 months	
Sexual desire	14 (100)
Sexual arousal	12 (85.5)
Lubrication	11 (78.5)
Orgasm	12 (85.5)
Satisfaction	12 (85.5)
Pain	1 (7)

ination. Resection margins were free of neoplastic pathology in all patients, and all resected lymph nodes were free of tumor pathology. All patients were followed for at least 56 months. During this period, no patient developed local recurrence (urethral and/or neovesical) or metastatic recurrence (RFS 100%) with a 100 % OS. The oncological findings are presented in Table 2.

Out of the 14 patients, 12 (85.5%) maintained complete continence both during the day and at night, 2 (15.5%) complained about urine leakage at night, and only 1 required the use of 1-2 pads. The Sandvik Score showed a state of complete continence in 7 patients (50%), mild incontinence in 6 patients (43%) without the use of urinary incontinence devices, moderate incontinence in 1 patient (7%) with the use of 1-2 pads during the night. Only one patient developed urethral-neovesical stenosis after 6 months, which was treated by endoscopic surgery. During the follow-up period, no patient developed hydronephrosis, urethro-neovesical reflux or deterioration of renal function. Of the 14 patients who underwent surgery, 13 (93%) were married, 1 was single (7%) but had a stable partner; 6 women (43%) were fertile at the time of surgery, while the other 8 (57%) were already menopausal; all patients were sexually active. As mentioned above, sexual function was assessed using the FSFI-19. This was administered 3 months and 1 year after surgery. One year postoperatively, FSFI showed sexual desire in all patients (100%); subjective arousal, orgasmic attainment and sexual satisfaction in 12/14 patients (85.5%); sufficient lubrication in 11/14 patients (78.5%). Dyspareunia during intercourse was reported by only one patient (7%). One year after surgery, all patients were sexually active. Finally, when we compared patients' test scores at 3 months and 12 months postoperatively, we found that all patients had higher final test scores after one year, due to improved sexual comfort. These data were also in line with the findings of the outpatient survey (total FSFI 3 months 18.3, range 15-21; total FSFI 12 months: 29.1, range 25-33). Functional outcomes are shown in Table 3.

## DISCUSSION

For more than half a century, radical cystectomy has globally been the procedure of choice for all male and female patients with muscle-invasive bladder cancer or high-risk non-invasive bladder cancer. However, it is an invasive procedure whose main target was, and still is, oncological radicality, aimed to improve the prognosis of patients, which is already poor (5-year survival rate of 63% in stage II patients and 48% in stage III patients) (10). At the same time, an attempt was made to mitigate the clinical and psychological consequences to which a patient undergoing radical cystectomy was subjected by reconstructing the lower urinary tract and in particular by orthotopic urinary diversions. Nowadays, there is also an increasing focus on the patient's quality of life, and minimally invasive surgical techniques or the search for organ-sparing techniques are a direct consequence of this (11, 12). Female gender is considered a protective factor in the epidemiology of many oncological diseases, but this is not the case for bladder cancer where being female means not only having a higher risk of cancer-specific mortality than men, but it is also considered an independent risk factor for bladder cancer-specific death (13, 14). The causes of this universally accepted statistic have been investigated in the underestimation of hematuria due to a false diagnosis of cystitis rather than bladder cancer, resulting in the absence of more accurate examinations (15). Another cause is to be identified in anatomy: in women there is no natural anatomical barrier between the bladder and the uterus capable of preventing extra-organ invasion of the bladder tumor, thus leading to a higher rate of diagnosis of advanced-stage tumors (16). For these reasons, radical cystectomy in women with orthotopic urinary diversion developed later than in men (it was only in the early 2000s that the genital organ-sparing cystectomies were performed in women). Numerous studies have been conducted to assess the oncological feasibility of sparing first the urethra, then the vagina and finally the genital organs in toto. *Ali-El-Dein et al.* in a 1999 study were among the first to show that sparing the urethra and making a neobladder was oncologically safe (17). He again reviewed 609 cystectomy patients for bladder cancer in 2004 and reported a 2.6% incidence of secondary genital co-invasion and a 0% incidence of primary genital cancer (18). *Groutz et al.* in a 1999 study performed 37 radical cystectomies and found genital organ involvement in only one patient (19). In a more recent study in 2019 *Huang and colleagues* showed out of 112 radical cystectomies the presence of uterine invasion in only 5 patients (4.5%) (20).

In our institution, we developed a technique with the aim of respecting oncological radicality and totally sparing the genital organs. The diversion used was the Padua neobladder because of its favorable urodynamic characteristics (adequate compliance and low pressures) and the use of a relatively short ileum segment. During genital organ sparing, we took special attention to sparing the neurovascular bundles along the lateral wall of the vagina with the aim of preserving not only the patients' fertility but also their sexual function. On the oncological side, none of our patients had genital organ recurrence or lymph node and/or extra lymph node metastases. In

terms of continence and sexuality, we have had satisfactory results about daytime and nocturnal continence as well as the fertility and sexuality of the patients. As far as complications, except for a single episode of urethral stenosis resolved by surgery, no patient developed prolapse, fistulas between the neobladder and vagina, or alteration of the upper urinary tract. The results of our study, in line with the literature, show that a total extended genital sparing radical cystectomy with sparing of the neurovascular bundle and the pubo-urethral ligaments strongly reduces the risk of vaginal fistulas, pelvic prolapse, neobladder prolapse secondary to an angulation of the uretero-intestinal anastomosis through the anterior wall of the vagina, and chronic urinary retention (21-23). Above all, it allows maintenance of good continence, satisfactory sexual function and not least the maintenance of fertility. In fact, in their papers, both *Ali-El-Dein et al.* and *Niver et al.* described a patient who became pregnant after the surgery, one of whom was also able to have a child (24, 25). Finally, an interesting 2005 case report by *Puppo et al.* presented a patient with cystocele and stress incontinence secondary to subtotal hysterectomy. The patient underwent radical cystectomy with ileal reservoir followed by reconstruction of pelvic floor integrity by colposacropxy using mesh. The hysterectomy with vaginal sparing and fixation of vaginal wall to adjacent structures or sacropexy may be a valid solution both oncologically and functionally. Nevertheless, from our point of view, anatomical support to the neobladder secondary to genital sparing, preservation of the neurovascular bundle, and maintenance of fertility are to be pursued in highly motivated and selected patients (26).

## CONCLUSIONS

Total extended genital sparing cystectomy appears to be a safe treatment for high-risk non-muscle invasive or muscle invasive bladder cancer in terms of oncological radicality and it is also beneficial in terms of urinary continence, fertility and sexual function, quality of life and psychological and emotional health. However, it is a treatment that should be reserved for carefully selected patients who are highly motivated by the preservation of fertility and sexual function and who are fully informed about the advantages and disadvantages of this procedure.

## REFERENCES

1. Sung H, Ferlay J, Siegel RL, et al. *Global cancer statistics 2020: GLOBOCAN estimates of incidence and mortality worldwide for 36 cancers in 185 countries.* *CA Cancer J Clin.* 2021; 71:209-249.
2. Ferlay J, Colombet M, Soerjomataram I, et al. *Cancer statistics for the year 2020: An overview.* *Int J Cancer.* 2021.
3. Scosyrev E, Noyes K, Feng C, Messing E. *Sex and racial differences in bladder cancer presentation and mortality in the US.* *Cancer.* 2009; 115:68-74.
4. Babjuk M, Burger M, Compérat E, et al. *Guidelines on Non-muscle-invasive Bladder Cancer (Ta, T1 and CIS).* EAU Guidelines Office, 2022. European Association of Urology Guidelines Office Arnhem, The Netherlands.

5. Varkarakis IM, Pinggera G, Antoniou N, et al. *Pathological review of internal genitalia after anterior exenteration for bladder cancer in women. Evaluating risk factors for female organ involvement.* *Int Urol Nephrol.* 2007; 39:1015-1021.
6. Kulkarni JN, Rizvi SJ, Acharya UP, et al. *Gynecologic-tract sparing extra peritoneal retrograde radical cystectomy with neobladder.* *Int Braz J Uro.* 2008; 34:180-7.
7. Dindo D, Demartines N, Clavien PA. *Classification of surgical complications: a new proposal with evaluation in a cohort of 6336 patients and results of a survey.* *Ann Surg.* 2004; 240:205-213.
8. Rosen R, Brown C, Heiman J, et al. *The Female Sexual Function Index (FSFI): A multidimensional self-report instrument for the assessment of female sexual function.* *J Sex Marital Ther.* 2000; 26:191-208.
9. Sandvik H, Seim A, Vanvik A, Hunskaar S. *A severity index for epidemiological surveys of female urinary incontinence: comparison with 48-hour pad-weighting tests.* *Neurourol Urodyn.* 2000; 19:137-45.
10. Witjes JA, Bruins HM, Carrion A, et al. *EAU Guidelines on Muscle-invasive and Metastatic Bladder Cancer 2022.* Edn. presented at the 37th EAU Annual Congress Amsterdam. European Association of Urology Guidelines Office Arnhem, The Netherlands.
11. Tang K, Li H, Xia D, et al. *Laparoscopic versus open radical cystectomy in bladder cancer: a systematic review and meta-analysis of comparative studies.* *PLoS One.* 2014; 9:e95667.
12. Kalampokis N, Grivas N, Ölschläger M, et al. *Radical Cystectomy in Female Patients - Improving Outcomes.* *Curr Urol Rep.* 2019; 20:83.
13. Kluth LA, Rieken M, Xylinas E, et al. *Gender-specific differences in clinicopathologic outcomes following radical cystectomy: an international multi-institutional study of more than 8000 patients.* *Eur Urol.* 2014; 66:913-9.
14. Messer JC, Shariat SF, Dinney CP, et al. *Female gender is associated with a worse survival after radical cystectomy for urothelial carcinoma of the bladder: a competing risk analysis.* *Urology.* 2014; 83:863-7.
15. Cohn JA, Vekhter B, Lyttle C, et al. *Sex disparities in diagnosis of bladder cancer after initial presentation with hematuria: a nationwide claims-based investigation.* *Cancer.* 2014; 120:555-61.
16. Weissbart SJ, Smith AL. *Hysterectomy in the Urologist's Practice.* *Curr Urol Rep.* 2017; 18:4.
17. Ali-el-Dein B, el-Sobky E, Hohenfellner M, Ghoneim MA. *Orthotopic bladder substitution in women: functional evaluation.* *J Urol.* 1999; 161:1875-80.
18. Ali-El-Dein B, Abdel-Latif M, Mosbah A, et al. *Secondary malignant involvement of gynecological organs at radical cystectomy specimens in women: is it mandatory to remove these organs routinely?* *J Urol.* 2004; 172:885-7.
19. Groutz A, Gillon G, Konichezky M, et al. *Involvement of internal genitalia in female patients undergoing radical cystectomy for bladder cancer: a clinicopathologic study of 37 cases.* *Int J Gynecol Cancer.* 1999; 9:302-306.
20. Huang H, Yan B, Shang M, et al. *Is hysterectomy beneficial in radical cystectomy for female patient with urothelial carcinoma of bladder? A retrospective analysis of consecutive 112 cases from a single institution.* *BMC Urol.* 2019; 19:28.
21. Moursy EE, Eldahshoursy MZ, Gamal WM, Badawy AA. *Orthotopic genital sparing radical cystectomy in pre-menopausal women with muscle-invasive bladder carcinoma: A prospective study.* *Indian J Urol.* 2016; 32:65-70.

22. Roshdy S, Senbel A, Khater A, et al. Genital Sparing Cystectomy for Female Bladder Cancer and its Functional Outcome; a Seven Years' Experience with 24 Cases. *Indian J Surg Oncol.* 2016; 7:307-11.
23. Borghi C, Manservigi M, Milandri ES, et al. The impact of orthotopic reconstruction on female sexuality and quality of life after radical cystectomy for non-malignant bladder conditions. *Arch Ital Urol Androl.* 2021; 93:255-261.
24. Ali-El-Dein B, Mosbah A, Osman Y, et al. Preservation of the internal genital organs during radical cystectomy in selected women with bladder cancer: a report on 15 cases with long term follow-up. *Eur J Surg Oncol.* 2013; 39:358-64.
25. Niver BE, Daneshmand S, Satkunasivam R. Female reproductive organ-sparing radical cystectomy: contemporary indications, techniques and outcomes. *Curr Opin Urol.* 2015; 25:105-10.
26. Puppo P, Introini C, Calvi P, Naselli A. Pelvic floor reconstruction before orthotopic bladder replacement after radical cystectomy for bladder cancer. *Urology.* 2005; 65:174.

---

#### Correspondence

Antonio Cisternino, MD (Corresponding Author)  
antonio.cisternino@libero.it

Lorenzo Capone, MD (Corresponding Author)  
lorenzocapone@msn.com

Antonio Rosati, MD

Costanzo Latiano, MD

Nicola Sebastio, MD

Antonio Colella, MD

Giuseppe Crefi, MD

Department of Urology, Fondazione IRCCS Casa Sollievo della Sofferenza, via dei Cappuccini, 71013, San Giovanni Rotondo (Italy)

---

**Conflict of interest:** The authors declare no potential conflict of interest.